

American Board of Family Medicine



IN-TRAINING EXAMINATION

1. A 68-year-old male presents to your office with a 2-day history of headache, muscle aches, and chills. His wife adds that his temperature has been up to 104.1 °F and he seems confused sometimes. His symptoms have not improved with usual care, including ibuprofen and increased fluid intake. He and his wife returned from a cruise 10 days ago but don't recall anyone having a similar illness on the ship. This morning he started to cough and his wife was concerned because she saw some blood in his sputum. He also states that he experiences intermittent shortness of breath and feels nauseated. His blood pressure is 100/70 mm Hg, heart rate 98/min, temperature 39.4°C (102.9°F), and oxygen saturation 95% on room air.

Which one of the following would be the preferred method to confirm your suspected diagnosis of Legionnaires' disease?

- A) Initiating azithromycin (Zithromax) to see if symptoms improve
 - B) A chest radiograph
 - C) *Legionella* polymerase chain reaction (PCR) testing
 - D) A sputum culture for *Legionella*
 - E) Urine testing for *Legionella pneumophila* antigen
2. Which one of the following factors related to pregnancy and delivery increases the risk of developmental dysplasia of the hip in infants?
 - A) A large-for-gestational age infant
 - B) Twin birth
 - C) Breech presentation
 - D) Cesarean delivery
 - E) Premature birth
 3. A healthy 2-month-old female is brought to your office for a routine well baby examination by both of her parents, who have no concerns. The parents refuse routine recommended vaccines for their daughter because of their personal beliefs.

You want to incorporate patient-centeredness and are also concerned about improving the health of the population. You decide to follow the CDC recommendations by

- A) accepting their decision without further action
- B) not offering vaccines at future visits to preserve a positive doctor-patient relationship
- C) having the parents sign a refusal to vaccinate form
- D) dismissing the family from the practice
- E) pursuing a court order for vaccine administration since the child has no medical exemptions

4. A 50-year-old male carpet layer presents with swelling of his right knee proximal to the patella. He does not have any history of direct trauma, fever, chills, or changes in the overlying skin. On examination the site is swollen but minimally tender, with no warmth or erythema.

Which one of the following would be most appropriate at this point?

- A) Rest, ice, and compression
 - B) Aspiration of fluid for analysis
 - C) Injection of a corticosteroid
 - D) An oral corticosteroid taper
 - E) Referral to an orthopedic surgeon for resection
5. An 85-year-old female with a previous history of diabetes mellitus, hypertension, dementia, and peptic ulcer disease has been in a skilled nursing facility for 4 weeks for rehabilitation after a hip fracture repair secondary to a fall during an ischemic stroke. She is transported to the emergency department today when she develops confusion, shortness of breath, and diaphoresis. Her blood pressure is 172/98 mm Hg, her heart rate is 122 beats/min with an irregular rhythm, and her respiratory rate is 22/min. An EKG demonstrates atrial fibrillation and 0.2 mV ST-segment elevation compared to previous EKGs. Her first troponin level is elevated.

Which one of the following conditions in this patient is considered an ABSOLUTE contraindication to fibrinolytic therapy?

- A) Poorly controlled hypertension
 - B) Peptic ulcer disease
 - C) Alzheimer's dementia
 - D) Hip fracture repair
 - E) Ischemic stroke
6. An otherwise healthy 57-year-old female presents with a sudden onset of hearing loss. She awoke this morning unable to hear out of her left ear. There was no preceding illness and she currently feels well otherwise. She does not have ear pain, headache, runny nose, congestion, or fever, and she does not take any daily medications.

On examination you note normal vital signs and find a normal ear, with no obstructing cerumen and with normal tympanic membrane motion on pneumatic otoscopy. You perform a Weber test by placing a tuning fork over her central forehead. She finds that the sound lateralizes to her right ear. The Rinne test shows sounds are heard better with bone conduction on the left and with air conduction on the right.

You refer her to an otolaryngologist for further evaluation including audiometry. You should also consider initiating which one of the following medications at this visit in order to optimize the likelihood of recovery?

- A) Acyclovir (Zovirax)
- B) Amoxicillin/clavulanate (Augmentin)
- C) Aspirin
- D) Nifedipine (Procardia)
- E) Prednisone

7. You are the team physician for the local high school track team. During a meet one of the athletes inadvertently steps off the edge of the track and inverts her right foot forcefully. She is able to bear weight but with significant pain. She reports pain across her right midfoot. An examination reveals edema over the lateral malleolus and diffuse tenderness, but she does not have any pain with palpation of the navicular, the base of the fifth metatarsal, or the posterior distal lateral and medial malleoli.

Which one of the following would be most appropriate at this time?

- A) Radiographs of the right ankle only
 - B) Radiographs of the right foot only
 - C) Radiographs of the right foot and ankle
 - D) Lace-up ankle support, ice, compression, and clinical follow-up
 - E) Crutches and no weight bearing for 2 weeks, followed by a slow return to weight bearing
8. A 65-year-old male with type 2 diabetes mellitus, hypertension, and obstructive sleep apnea sees you for follow-up. He does not use tobacco or other drugs, and his alcohol consumption consists of two drinks per day. His BMI is 31.0 kg/m², and he just started a fitness program. The patient tells you that his brother was recently diagnosed with atrial fibrillation and he asks you if this increases his own risk.

Which one of the following factors would increase the risk of atrial fibrillation in this patient?

- A) Alcohol use
 - B) Treatment with lisinopril (Prinivil, Zestril)
 - C) Treatment with pioglitazone (Actos)
 - D) Use of a continuous positive airway pressure (CPAP) device
 - E) Physical stress
9. You have diagnosed a 32-year-old female with moderate iron deficiency anemia, presumed to be due to chronic menstrual blood loss. She has no gastrointestinal or genitourinary symptoms, and no bruising or bleeding other than menstrual bleeding. Her vital signs are normal and a physical examination is unremarkable. You initiate a trial of oral iron therapy.

Which one of the following would be the best way to assess the patient's response to oral iron?

- A) A reticulocyte count in 1–2 weeks
- B) A repeat hematocrit in 2 weeks
- C) A peripheral smear to look for new RBCs in 4 weeks
- D) A serum total iron binding capacity and ferritin level in 6 weeks

10. You see an adult patient who has chronic urticaria and no other known chronic conditions. He continues to experience hives after a 3-month course of daily loratadine (Claritin).

Which one of the following would be the most appropriate addition to his treatment regimen at this time?

- A) A short course of oral corticosteroids
- B) Cyclosporine
- C) Ranitidine (Zantac)
- D) Narrow-band UV light treatment

11. A 10-year-old male has an 8-mm induration 2 days after a tuberculin skin test. He shares a bedroom with his 18-year-old brother who was recently diagnosed with tuberculosis. There are no other historical or physical examination findings to suggest active tuberculosis infection and a chest radiograph is normal.

Which one of the following would be most appropriate at this point?

- A) Monitoring with annual tuberculin skin testing
- B) Observation and repeat tuberculin skin testing in 3 weeks
- C) Rifampin (Rifadin) daily for 4 months
- D) Isoniazid daily for 9 months
- E) Once-weekly isoniazid and rifampin for 3 months

12. A 62-year-old female with diabetes mellitus presents to your office with left lower quadrant pain and guarding. She has a previous history of a shellfish allergy that caused hives and swelling.

Further evaluation of this patient should include which one of the following?

- A) Ultrasonography of the abdomen
- B) CT of the abdomen and pelvis with oral and intravenous (IV) contrast
- C) Oral corticosteroids and antihistamines, then CT of the abdomen and pelvis with oral and IV contrast
- D) Intravenous corticosteroids and antihistamines, then CT of the abdomen and pelvis with oral and IV contrast
- E) Laparotomy

13. A 45-year-old female who works as a house cleaner presents with left shoulder pain. On examination she has pain and relative weakness when pushing toward the midline against resistance while the shoulder is adducted and the elbow is bent to 90°. With the elbow still at 90° she is unable to keep her left hand away from her body when you position her hand behind her back.

This presentation is most consistent with an injury of which one of the following tendons?

- A) Deltoid
- B) Infraspinatus
- C) Subscapularis
- D) Supraspinatus
- E) Teres minor

14. An 8-year-old male is brought to your office because of acute lower abdominal pain. He is not constipated and has never had abdominal surgery. You suspect acute appendicitis.

Which one of the following would be most appropriate at this point?

- A) Plain radiography
- B) Ultrasonography
- C) CT without contrast
- D) CT with contrast
- E) MRI

15. You see a patient with a serum sodium level of 122 mEq/L (N 135–145) and a serum osmolality of 255 mOsm/kg H₂O (N 280–295). Which one of the following would best correlate with a diagnosis of syndrome of inappropriate antidiuresis?

- A) A fractional excretion of sodium below 1%
- B) Elevated urine osmolality
- C) Elevated serum glucose
- D) Elevated BUN
- E) Low plasma arginine vasopressin

16. A 45-year-old African-American male returns to your clinic to evaluate his progress after 6 months of dedicated adherence to a diet and exercise plan you prescribed to manage his blood pressure. His blood pressure today is 148/96 mm Hg. He is not overweight and he does not have other known medical conditions or drug allergies.

Which one of the following would be the most appropriate initial antihypertensive treatment option for this patient?

- A) Chlorthalidone
- B) Hydralazine
- C) Lisinopril (Prinivil, Zestril)
- D) Losartan (Cozaar)
- E) Metoprolol

17. An 85-year-old female with metastatic breast cancer requests hospice care. She has type 2 diabetes mellitus, stage 3 renal failure, and heart disease.

The patient's eligibility for hospice care will be based on her

- A) age
 - B) cancer diagnosis
 - C) comorbid conditions
 - D) life expectancy
 - E) Medicare Part B plan
18. A 15-year-old female presents with a 3-month history of intermittent abdominal pain and headaches. She does not have any associated weight loss, fever, nausea, change in bowel habits, or other worrisome features. An examination is unremarkable. She does report being stressed at school and has a PHQ-2 score of 4.

Which one of the following would be most appropriate at this point?

- A) Further evaluation for depression
 - B) Laboratory studies
 - C) Abdominal imaging
 - D) Citalopram (Celexa)
 - E) Fluoxetine (Prozac)
19. A 69-year-old male with type 2 diabetes mellitus, obesity, and a history of coronary artery disease sees you for follow-up of his diabetes. His hemoglobin A_{1c} has increased to 8.7% despite therapy with metformin (Glucophage), 1000 mg twice daily, and insulin glargine (Lantus).

Which one of the following additional medications would be most effective for reducing his blood glucose level and lowering his risk of cardiovascular events?

- A) Exenatide (Byetta)
 - B) Glipizide (Glucotrol)
 - C) Liraglutide (Victoza)
 - D) Rosiglitazone (Avandia)
 - E) Sitagliptin (Januvia)
20. A 2-year-old African-American male with a history of sickle cell disease is brought to your office for a well child check. Which one of the following would be most appropriate for screening at this time?
- A) A chest radiograph
 - B) A DXA scan
 - C) Abdominal ultrasonography
 - D) Renal Doppler ultrasonography
 - E) Transcranial Doppler ultrasonography

21. You perform the initial newborn examination on a male on his first day of life, following an uncomplicated vaginal delivery at an estimated gestational age of 37 weeks and 6 days. The prenatal course was significant for the initial presentation for prenatal care at 22 weeks gestation. You note that the infant's upper lip is thin and the philtrum is somewhat flat.

Which additional finding would increase your concern for fetal alcohol syndrome?

- A) Curvature of the fifth digit of the hand (clinodactyly)
 - B) A supernumerary digit of the hand
 - C) Flattening of the head (plagiocephaly)
 - D) Metatarsus adductus in one foot
 - E) Syndactyly of the toes (webbed feet)
22. An otherwise healthy 3-year-old child with no allergies is found to have otitis media with effusion in the right ear. Which one of the following would you recommend?
- A) No treatment, and follow-up in 3 months
 - B) Amoxicillin
 - C) Oral antihistamines
 - D) Nasal corticosteroids
 - E) Tympanostomy tube placement
23. A 32-year-old male presents with a 4-week history of persistent low back pain. He started feeling tightness in his low back after helping a friend move into a new apartment. The pain does not radiate, there is no associated paresthesia or numbness, and he has not had any bowel or bladder incontinence. The pain is constant and worsens with prolonged sitting. He rates the pain as 6 on a scale of 10. Ibuprofen has provided minimal relief.

Examination of the lumbar area over the paraspinal muscles reveals minimal tenderness. A neurovascular examination and a straight leg raise are normal in both lower extremities.

Which one of the following would be most appropriate at this point?

- A) Imaging studies of the lumbar spine
- B) A short course of an oral corticosteroid
- C) Gabapentin (Neurontin) started at a low dose and titrated to effect
- D) A skeletal muscle relaxant and an NSAID
- E) A short-acting opioid and an NSAID

24. A 48-year-old female with GERD treated with a proton pump inhibitor for the past 2 years sees you for a routine visit. She reports that she has paresthesia and numbness in both feet. Her hemoglobin A_{1c} is 5.8%, her hemoglobin level is 10.4 g/dL (N 12.0–16.0), and her mean corpuscular volume is 102 μm^3 (N 81–99). Microfilament testing shows decreased sensation in both feet.

Which one of the following is the most likely cause of her peripheral neuropathy?

- A) Charcot-Marie-Tooth disease
 - B) Diabetic peripheral neuropathy
 - C) Hyperthyroidism
 - D) Tarsal tunnel syndrome
 - E) Vitamin B₁₂ deficiency
25. A 60-year-old male presents with a several-month history of a dry cough and progressive shortness of breath with exertion. On examination he has tachypnea and bibasilar end-inspiratory dry crackles, and a chest radiograph reveals interstitial opacities.

Which one of the following patient occupations would most likely support a diagnosis of silicosis?

- A) Baker
 - B) Firefighter
 - C) Stone cutter
 - D) Goat dairy farmer
 - E) High-tech electronics fabricator
26. A 28-year-old female presents with a 3-month history of fatigue and postural lightheadedness. On examination she is diffusely hyperpigmented, especially her skin creases and areolae. A CBC and basic metabolic panel are normal except for an elevated potassium level. You order a corticotropin stimulation test.

Prior to the corticotropin injection, you should order which one of the following tests to confirm that this patient has a primary insufficiency and not a secondary (pituitary) disorder?

- A) ACTH
- B) Aldosterone
- C) Melanocyte-stimulating hormone
- D) Renin
- E) TSH

27. You see a 3-year-old female with a 2-day history of intermittent abdominal cramps, two episodes of emesis yesterday, and about five watery, nonbloody stools each day. She does not have a fever, her other vital signs are normal, and she has not traveled recently. Today she has tolerated sips of fluid but still has mild fatigue and thirst. An examination is normal except for mildly dry lips. A friend at preschool had a similar illness recently.

Which one of the following would be the most appropriate initial management of this patient?

- A) A sports drink and food on demand
 - B) Half-strength apple juice and food on demand
 - C) Ginger ale and no food yet
 - D) Water and no food yet
 - E) A bolus of intravenous normal saline and no food yet
28. A 32-year-old female requests a physical examination prior to participating in an adult soccer league. Her blood pressure is 118/70 mm Hg and her pulse rate is 68 beats/min. The examination is otherwise normal except for a systolic murmur that intensifies with Valsalva maneuvers. She says that she has recently been experiencing mild exertional dyspnea and moderate chest pain. The chest pain has been atypical and is not necessarily related to exertion. Echocardiography reveals hypertrophic cardiomyopathy.

In addition to referring the patient to a cardiologist, you recommended initiating therapy with

- A) amiodarone (Cordarone)
 - B) amlodipine (Norvasc)
 - C) furosemide (Lasix)
 - D) lisinopril (Prinivil, Zestril)
 - E) metoprolol
29. An 85-year-old female with advanced Alzheimer's disease is brought to your office for treatment of agitation, aggressive behavior, and delusions. Behavioral and psychological interventions have had little success and the family is willing to try medications because they prefer to keep the patient at home.

Which one of the following would most likely help control this patient's symptoms?

- A) Alprazolam (Xanax)
- B) Aripiprazole (Abilify)
- C) Clozapine (Clozaril)
- D) Donepezil (Aricept)
- E) Haloperidol

30. A 30-year-old female with anovulatory uterine bleeding asks about treatment options. An examination is normal and blood testing is negative. She is unmarried and is undecided about having children.

Which one of the following would be the most appropriate treatment for this patient?

- A) Oral progestin during the luteal phase
- B) A levonorgestrel-releasing IUD
- C) Endometrial ablation
- D) Hysterectomy

31. A 73-year-old male with advanced degenerative arthritis of the knees asks what you would recommend for relief. He does not wish to have a total knee replacement. He says that NSAIDs have not been effective.

Which one of the following would be the best recommendation?

- A) Acetaminophen
- B) Intra-articular corticosteroids
- C) Intra-articular hylan GF 20 (Synvisc)
- D) Physical therapy for quadriceps strengthening
- E) Tramadol (Ultram)

32. A 66-year-old male recently underwent percutaneous angioplasty for persistent angina with exertion. He does not have any symptoms now. His LDL-cholesterol level is 90 mg/dL.

Which one of the following would be most appropriate for secondary prevention of this patient's coronary artery disease?

- A) No drug treatment
- B) Evolocumab (Repatha), 140 mg subcutaneously every 2 weeks
- C) Ezetimibe (Zetia), 10 mg daily
- D) Rosuvastatin (Crestor), 20 mg daily
- E) Simvastatin (Zocor), 40 mg daily

33. A 62-year-old female who is a new patient requests a thyroid evaluation because she has a history of abnormal thyroid test results. You obtain a copy of her records, which include a TSH level of 0.2 $\mu\text{U/mL}$ (N 0.4–4.2) and a free T_4 level of 2.0 ng/dL (N 0.8–2.7) from 3 years ago. She reports feeling well and has no other health conditions. She does not take any medications.

A physical examination reveals normal vital signs, a BMI of 23.0 kg/m^2 , no neck masses, a normal thyroid size, and normal heart sounds. Laboratory studies reveal a TSH level of 0.1 $\mu\text{U/mL}$, a free T_4 level of 2.5 ng/dL, and a free T_3 level of 3.1 pg/mL (N 2.3–4.2).

Treatment for this condition would be indicated if the patient has an abnormal

- A) calcium level
 - B) DXA scan
 - C) glucose level
 - D) lipid level
 - E) thyroid ultrasonography study
34. A 43-year-old male who works in a warehouse sees you because of dizziness. He first noticed mild dizziness when he rolled over and got out of bed this morning. He had several more severe episodes that were accompanied by nausea, and on one occasion vomiting occurred after he tilted his head upward to look for items on the higher shelves at work. You suspect benign paroxysmal positional vertigo, so you perform the Dix-Hallpike maneuver as part of the examination.

Which one of the following findings during the examination would confirm the diagnosis?

- A) Nystagmus when vertigo is elicited
 - B) Vertigo that occurs immediately following the test-related head movement
 - C) Persistence of vertigo for 5 minutes following the test-related head movement
 - D) A drop in systolic blood pressure of > 10 mm Hg when supine
35. You are initiating pharmacologic therapy for a 75-year-old patient with depression. Which one of the following would be most appropriate for this patient?
- A) Amitriptyline
 - B) Escitalopram (Lexapro)
 - C) Imipramine (Tofranil)
 - D) Paroxetine (Paxil)

36. A 58-year-old male with a 30-pack-year smoking history comes to your office to discuss screening for COPD. His older brother and sister have both recently been diagnosed with COPD and he wants to be screened for this soon. He continues to smoke and does not express a desire to quit. He does not have shortness of breath, cough, orthopnea, paroxysmal nocturnal dyspnea, or dyspnea on exertion. His only medication is aspirin, 81 mg daily. He has never used inhaled medications such as albuterol (Proventil, Ventolin). His family history is otherwise negative. You counsel him on tobacco cessation today.

Which one of the following is recommended with regard to COPD screening for this patient?

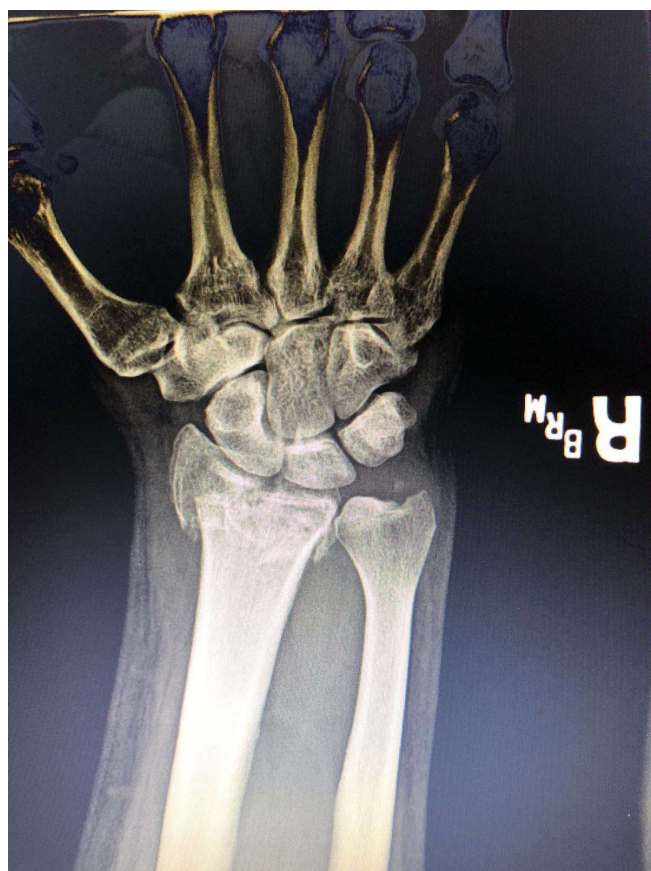- A) No screening
 - B) Spirometry with pre- and postbronchodilator testing
 - C) Posteroanterior and lateral chest radiographs
 - D) Noncontrast CT of the chest
 - E) α_1 -Antitrypsin deficiency gene testing
37. The dietary herbal supplement with the highest risk for drug interactions is
- A) black cohosh
 - B) ginseng
 - C) St. John's wort (*Hypericum perforatum*)
 - D) saw palmetto
 - E) valerian
38. A 32-year-old female sees you for a health maintenance visit. She reports that she experiences severe anxiety when involved in social situations. She lives with her mother and dreads meeting unfamiliar people. At work she remains in her cubicle throughout the day and avoids staff parties. She has a history of alcoholism in remission. She has otherwise been in good health and a physical examination is normal.

Which one of the following would be first-line treatment for this patient?

- A) Amitriptyline
 - B) Bupropion (Wellbutrin)
 - C) Escitalopram (Lexapro)
 - D) Lorazepam (Ativan)
 - E) Pregabalin (Lyrica)
39. A 67-year-old female presents with a swollen wrist after falling on her outstretched hand. A radiograph of the affected wrist is shown below.

Prior to surgical intervention, you recommend application of a

- A) radial gutter splint
- B) sugar tong splint
- C) thumb spica splint
- D) forearm circumferential cast



Item #39

40. A 7-year-old female with asthma is brought to your office because of her fourth episode of wheezing in the last 3 months. She has also had to use her short-acting β -agonist rescue inhaler more frequently.

Which one of the following should be added to reduce the frequency of asthma exacerbations?

- A) A leukotriene receptor antagonist
 - B) A long-acting β -agonist
 - C) An inhaled corticosteroid
 - D) Inhaled cromolyn via nebulizer
41. A 55-year-old female presents with the new onset of palpitations. An underlying cardiac cause should be suspected if the patient's palpitations
- A) affect her sleep
 - B) are associated with dry mouth
 - C) are worse in public places
 - D) last less than 5 minutes
42. A 69-year-old female presents with scaling, redness, and irritation under her breasts for the past several months. She has tried several over-the-counter antifungal creams without any improvement. On examination you note erythematous, well demarcated patches with some scale under both breasts. You examine the rash with a Wood's lamp to confirm your suspected diagnosis.

This rash is most likely to fluoresce

- A) bright yellow
 - B) coral pink
 - C) lime green
 - D) pale blue
 - E) totally white
43. A 25-year-old female who recently moved to the area comes in for a well woman visit. She reports that she has had yearly Papanicolaou (Pap) tests and sexually transmitted infection (STI) screening since age 21 with no abnormal results. She has had a total of six sexual partners. She is asymptomatic and does not have any history of STIs or new partners in the past year. Your nurse informs her that STI screening can be done, but a Pap test is not necessary at this time.

The patient is concerned about not having a Pap test this year and asks you why it is not recommended. You explain that the most important reason is that

- A) she has no history of STIs
- B) she has had several normal Pap tests in a row
- C) she is in a low-risk group for HPV infection
- D) Pap test abnormalities would require no further evaluation in a patient her age
- E) the risk of harm from unnecessary procedures and treatment exceeds the potential benefit at her age

44. A 42-year-old male with hypertension and hyperlipidemia sees you for a routine health maintenance examination. His blood pressure is 185/105 mm Hg. He does not have any current symptoms, including headache, chest pain, edema, or shortness of breath. He is adherent to his current medication regimen, which includes lisinopril (Prinivil, Zestril), 10 mg daily, and simvastatin (Zocor), 20 mg at night. A thorough history and physical examination are both unremarkable.

Which one of the following would be the most appropriate next step?

- A) A 30-minute rest period followed by a repeat blood pressure reading
 - B) Clonidine (Catapres), 0.2 mg given in the office
 - C) A comprehensive metabolic panel, fasting lipid profile, and TSH level
 - D) A stress test
 - E) Hospital admission for blood pressure reduction
45. You see a 53-year-old female with diabetes mellitus, hypertension, mixed hyperlipidemia, and GERD. Recent laboratory studies include an incidental finding of thrombocytopenia. The patient has no other significant past medical history, and she does not use tobacco or drink alcohol. Her current medications include metformin (Glucophage), lisinopril (Prinivil, Zestril), omeprazole (Prilosec), calcium citrate, and pravastatin (Pravachol). A physical examination is notable for a BMI of 31.3 kg/m². Her skin, heart, lungs, abdomen, and extremities are normal. Results of a CBC and a comprehensive metabolic panel are normal with the following exceptions:

Platelets	70,000 (N 150,000–379,000)
Glucose	108 mg/dL
Bilirubin	0.4 mg/dL (N 0.0–0.4)
Alkaline phosphatase	175 U/L (N 38–126)
ALT (SGPT)	52 U/L (N 10–28)

A peripheral smear is normal except for reduced platelets. Tests for hepatitis B, hepatitis C, and HIV are negative.

The most likely etiology of this patient's thrombocytopenia is

- A) a hematologic malignancy
 - B) chronic liver disease
 - C) drug-induced thrombocytopenia
 - D) immune thrombocytopenic purpura (ITP)
 - E) primary bone marrow failure
46. A patient has a past medical history that includes a sleeve gastrectomy for weight loss. Which one of the following medications should be AVOIDED in this patient?
- A) Acetaminophen
 - B) Gabapentin (Neurontin)
 - C) Hydrocodone
 - D) Ibuprofen
 - E) Tramadol (Ultram)

47. An 11-year-old female is referred to you after a sports physical examination because 2+ protein was found on a random dipstick urinalysis. She feels well and does not have any health concerns. She plays soccer an average of 5 days a week.

The patient's medical history is unremarkable and she takes no medications. Menarche has not occurred. She does not report any urinary or back symptoms, recent illness, edema, or weight change. A physical examination is normal. A dipstick urinalysis in your office shows 1+ protein but is otherwise normal.

Which one of the following would you recommend next?

- A) Withdrawing from all physical activity for 24 hours and a 24-hour urine for protein
 - B) A spot protein/creatinine ratio performed on first morning urine
 - C) Serum BUN, creatinine, electrolyte, and albumin levels
 - D) Ultrasonography of the kidneys and bladder
 - E) Referral to a pediatric nephrologist
48. Intensive behavioral intervention has more benefit than other treatment modalities in treating children who have been diagnosed with
- A) attention-deficit/hyperactivity disorder
 - B) autism
 - C) depression
 - D) obsessive-compulsive disorder
 - E) posttraumatic stress disorder
49. A patient asks which shingles vaccine he should receive. Which one of the following is an advantage of the recombinant zoster vaccine (Shingrix) compared to the live zoster vaccine (Zostavax)?
- A) Improved efficacy
 - B) Lower cost
 - C) Subcutaneous administration
 - D) Proven safety for immunocompromised patients
 - E) Administration as a single dose

50. A 45-year-old female sees you because of an increase in fibromyalgia pain. On examination she has a BMI of 35.6 kg/m² and normal vital signs except for a blood pressure of 156/91 mm Hg. Her other medical problems include obstructive sleep apnea, type 2 diabetes mellitus, hypertension, and generalized anxiety disorder. She smokes one pack of cigarettes daily and does not drink alcohol. She is currently taking metformin (Glucophage), 500 mg twice daily; lisinopril (Prinivil, Zestril), 10 mg daily; gabapentin (Neurontin), 300 mg 3 times daily; oxycodone (OxyContin), 10 mg every 6 hours; and lorazepam (Ativan), 1 mg 3 times daily.

Which one of the following findings in this patient's history greatly increases her risk of an accidental overdose?

- A) Tobacco use
 - B) Morbid obesity
 - C) Use of oxycodone
 - D) Use of oxycodone and lorazepam
 - E) Use of lorazepam and gabapentin
51. A 34-year-old female presents with a 3-month history of a minimally productive cough. She has never smoked. She does not have any fever, weight loss, rhinorrhea, congestion, or heartburn. She does not have a known history of allergies or asthma and has tried over-the-counter cold remedies, cough syrups, and cough drops without significant relief. She is otherwise healthy and takes no medications. On examination her vital signs are normal. An ear, nose, and throat examination is remarkable for swollen nasal turbinates. A lung examination is normal. Given the duration of the cough, you order a chest radiograph, which is normal as well.

Which one of the following would be most appropriate at this point?

- A) A trial of an intranasal corticosteroid
 - B) A trial of an inhaled bronchodilator
 - C) A trial of a proton pump inhibitor
 - D) A sinus radiograph
 - E) Referral for allergy testing
52. A 68-year-old female presents with a history of episodic severe lower abdominal pain relieved by defecation. She has had a long history of constipation with normal to very firm stools. Her history and a physical examination are otherwise normal. A colonoscopy 3 years ago was normal. You diagnose constipation-predominant irritable bowel syndrome.

Which one of the following agents would be the most appropriate treatment for this patient?

- A) Lactulose
- B) Magnesium citrate
- C) Milk of magnesia
- D) Polyethylene glycol
- E) Sodium phosphate

53. A 48-year-old male presents with pain in the right antecubital fossa after lifting a trailer in his garage. On examination you note ecchymosis and tenderness in the antecubital fossa. You suspect a possible distal biceps tendon rupture.

Which one of the following would be most appropriate at this point?

- A) A Speed's test
- B) Plain radiographs of the elbow
- C) MRI of the elbow
- D) A local corticosteroid injection
- E) Referral for physical therapy

54. A 72-year-old male with type 2 diabetes mellitus sees you for routine follow-up. He takes metformin (Glucophage), 1000 mg twice daily. He is sedentary and does not adhere to his diet. His BMI is 32.0 kg/m². The examination is otherwise within normal limits. His hemoglobin A_{1c} is 9.5%.

Which one of the following is recommended by the American Diabetes Association to better control his blood glucose?

- A) Start an intensive diet and exercise program for weight loss
- B) Start home monitoring of blood glucose with close follow-up
- C) Start basal insulin at 10 units/day
- D) Stop metformin and start a sulfonylurea
- E) Stop metformin and start a basal and bolus insulin regimen

55. A 47-year-old male presents with bilateral lower extremity edema of undetermined etiology extending to the proximal lower extremities, associated with fatigue. His lipid levels were also very high on recent testing. He does not take any daily medications and his thyroid function is normal. The only significant findings on examination are lower extremity edema and some periorbital edema.

Which one of the following urine tests could help confirm the most likely diagnosis?

- A) Crystals
- B) Ketones
- C) pH
- D) Protein
- E) Specific gravity

56. You are notified by the nurse that a 66-year-old female who was admitted for pain control for her bone metastases is still having breakthrough pain. You gave her 10 mg of immediate-release oxycodone (Roxicodone) 15 minutes ago.

You are hoping to optimize pain control and minimize sedation, so you advise the nurse that the last dose will have its peak effect

- A) now
 - B) 1 hour after it was given
 - C) 2 hours after it was given
 - D) 4 hours after it was given
57. A 62-year-old female has a history of COPD graded as moderate on pulmonary function testing, with an FEV₁ of 65 % of predicted and a PaO₂ of 57 mm Hg. Because her symptoms of dyspnea on exertion and fatigue seem out of proportion to her pulmonary function tests, you order echocardiography, which shows a pulmonary artery systolic pressure of 50 mm Hg, indicating pulmonary hypertension.

Which one of the following would be most effective for decreasing mortality in this situation?

- A) Supplemental oxygen
 - B) An endothelin receptor antagonist such as bosentan (Tracleer)
 - C) A calcium channel blocker such as nifedipine (Procardia)
 - D) A phosphodiesterase 5 inhibitor such as sildenafil (Revatio)
 - E) Referral for pulmonary artery endarterectomy
58. Which one of the following antihypertensive drugs may reduce the severity of sleep apnea?
- A) Amlodipine (Norvasc)
 - B) Hydralazine
 - C) Lisinopril (Prinivil, Zestril)
 - D) Metoprolol
 - E) Spironolactone (Aldactone)
59. The U.S. Preventive Services Task Force recommends screening all adults for obesity and offering intensive, multicomponent behavioral interventions to patients with a BMI ≥ 30 kg/m². This recommendation is based on trials that show that behavioral weight-loss interventions for overweight and obese patients with elevated plasma glucose levels reduce the incidence of diabetes mellitus by 30%–50% over 2–3 years and the number needed to treat is 7.

What is the absolute risk reduction for developing diabetes, based on these trials?

- A) 1/7
- B) 1/5
- C) 1/0.7
- D) 1/0.2
- E) 1/0.02

60. A 25-year-old female sees you because of irregular menses, hirsutism, and moderate acne. She is sexually active in a monogamous relationship with a male, has never been pregnant, and prefers not to become pregnant at this time.

Which one of the following is considered first-line therapy?

- A) Clomiphene (Clomid)
- B) Letrozole (Femara)
- C) Levonorgestrel/ethinyl estradiol
- D) Metformin (Glucophage)
- E) Spironolactone (Aldactone)

61. A 68-year-old male presents with chronic right knee pain from osteoarthritis that inhibits his activity and is associated with stiffness throughout the day. He has tried acetaminophen and NSAIDs with limited effect. He has consulted an integrative medicine specialist who recommended multiple modalities to reduce pain and increase function, and he asks whether you think they would be helpful.

Which one of the following measures recommended by the other physician has the STRONGEST evidence of benefit?

- A) A low-impact aerobic exercise program
- B) Lateral wedge insoles
- C) Oral glucosamine and chondroitin
- D) A platelet-rich plasma injection
- E) Needle lavage of the knee

62. A 52-year-old female nurse sees you for the first time. She was previously a patient of a recently retired physician in your practice. Her history is significant for a Roux-en-Y gastric bypass, degenerative joint disease of both knees and shoulders, and chronic low back pain. She takes oxycodone (Roxicodone), 5–10 mg every 4 hours. She tells you that she has been taking this for almost 10 years as treatment for various pains. She says that acetaminophen just “does not touch the pain” and that physical therapy has not worked. She asks you to continue this medication.

Which one of the following would be the most appropriate management of this patient?

- A) Add an NSAID to the current regimen
- B) Initiate weekly urine drug screens
- C) Taper oxycodone by 5%–10% every 1–4 weeks
- D) Discontinue oxycodone

63. A 13-year-old male sees you because of pain in his throwing arm. He is a very dedicated football quarterback and has been practicing throws and playing games every day for 2 months. The pain started gradually over the season, and there is no history of acute injury. The patient is right-hand dominant, and on examination he has pain when he raises his right arm above his shoulder. There is also tenderness to palpation of the proximal and lateral humerus.

Which one of the following would be most appropriate at this point?

- A) Injection of 10 mL of lidocaine into the subacromial space
- B) Plain radiographs of the shoulder
- C) Ultrasonography of the supraspinatus muscle
- D) MRI of the shoulder
- E) A bone scan of the shoulder

64. A 30-year-old female presents with an episode of recurrent, painful vesicular lesions on the labia. She noted a tingling, burning sensation a few days before the lesions appeared. A few years ago she had a similar outbreak just before the birth of her second child.

Which one of the following is indicated for this patient?

- A) Doxycycline
- B) Fluconazole (Diflucan)
- C) Metronidazole
- D) Penicillin G benzathine (Bicillin L-A)
- E) Valacyclovir (Valtrex)

65. A 62-year-old Asian female presents to your office with pain and redness in her left eye that started last night. She does not wear contact lenses. The pain has become more severe and she now has a headache, light sensitivity, and mild nausea. Examination of the eyes reveals diffuse conjunctival injection on the left. Her pupils are 4 mm bilaterally but the left one reacts poorly to light. Her visual acuity is 20/30 on the right and 20/100 on the left.

Which one of the following would be most appropriate at this time?

- A) Polymyxin B/trimethoprim ophthalmic drops (Polytrim)
- B) Prednisolone ophthalmic drops (Omnipred)
- C) An erythrocyte sedimentation rate and C-reactive protein level
- D) MRI of the brain with contrast
- E) Emergent evaluation by an ophthalmologist

66. A 24-year-old female with a history of bulimia nervosa sees you for treatment of depression. She is currently receiving cognitive-behavioral therapy. You decide that she requires medication to treat her depression.

Which one of the following medications has been associated with an increased risk of seizures in patients with bulimia nervosa?

- A) Bupropion (Wellbutrin)
- B) Fluoxetine (Prozac)
- C) Nortriptyline (Pamelor)
- D) Sertraline (Zoloft)
- E) Venlafaxine (Effexor XR)

67. At a routine well child visit the mother of a 3-year-old male expresses concern that his toes turn in, causing a clumsy gait when he walks. You diagnose internal tibial torsion, because his feet point inward when his patellae face forward. The examination is otherwise normal.

Which one of the following is recommended at this time?

- A) No intervention
- B) Shoe modification with wedges to externally rotate the feet while walking
- C) Night splinting with the feet externally rotated
- D) Serial casting to gradually externally rotate the feet
- E) Surgery to correct the deformity

68. A 24-year-old female seeks your advice regarding the recent onset of a cough when running. She moved to the United States from Mexico last year and her symptoms first became apparent during her first winter in the Midwest. The cough starts after she has been running approximately 1 mile but no sputum is produced and no other symptoms occur. She has no other health concerns.

A physical examination and office spirometry are consistent with a healthy young adult. You ask her to run around the outside of the clinic several times and then you reexamine her. The only change noted is an increase in her pulse rate and a 10% drop in her FEV₁.

Which one of the following would be the most appropriate initial treatment for this patient?

- A) An endurance conditioning program
- B) An over-the-counter antihistamine as needed
- C) An inhaled corticosteroid 2 hours before running
- D) An inhaled short-acting β_2 -agonist 15 minutes before running
- E) Daily use of an inhaled long-acting β_2 -agonist

69. Which one of the following malignancies is associated with hereditary hemochromatosis?

- A) Biliary carcinoma
- B) Chronic myeloid leukemia
- C) Hepatocellular carcinoma
- D) Multiple myeloma
- E) Pancreatic cancer

70. You admit a previously healthy 62-year-old female to the hospital for intractable nausea and vomiting with intravascular volume depletion and hypotension. She lives in rural northern New Mexico. Prior to the onset of her symptoms she had been gardening and cleaning out a chicken coop, where she encountered several rodents. She is febrile and you obtain blood and urine cultures. Two out of four blood culture bottles are positive for gram-negative rods.

Which one of the following is the most likely pathogen?

- A) *Brucella melitensis*
- B) *Coxiella burnetii*
- C) *Escherichia coli*
- D) *Listeria monocytogenes*
- E) *Yersinia pestis*

71. A 21-year-old female is being evaluated for secondary causes of refractory hypertension. Which one of the following would be most specific for fibromuscular dysplasia?

- A) A serum creatinine level
- B) An aldosterone:renin ratio
- C) 24-hour urine for metanephrines
- D) Renal ultrasonography
- E) Magnetic resonance angiography of the renal arteries

72. Of the following, which one is the greatest risk factor for developing knee osteoarthritis as an older adult?

- A) A sedentary lifestyle
- B) Cigarette smoking
- C) Low socioeconomic status
- D) Male sex
- E) Obesity

73. A staff member at a local assisted living facility calls you about an 88-year-old female who has chronic urinary incontinence and well controlled hypertension. A urinalysis was obtained after the patient reported some dizziness and malaise. She does not have dysuria and has had no change to her incontinence. The patient is afebrile and other vital signs are normal. The urine culture reveals >100,000 colony-forming units of *Escherichia coli*, with sensitivities pending.

In addition to supportive care and hydration, which one of the following would be indicated at this time?

- A) Ciprofloxacin (Cipro)
 - B) Fosfomycin (Monurol)
 - C) Nitrofurantoin (Macrochantin)
 - D) Trimethoprim/sulfamethoxazole (Bactrim)
 - E) No antibiotics
74. A 61-year-old white male with type 2 diabetes mellitus sees you for a follow-up visit. His blood pressure is 156/94 mm Hg. At a visit 1 week ago his blood pressure was 150/92 mm Hg. Laboratory studies obtained prior to this visit show a BUN of 16 mg/dL (N 6–20), a serum creatinine level of 0.9 mg/dL (N 0.7–1.3), and microalbuminuria on a urinalysis. His diabetes is well controlled with metformin (Glucophage) and he is taking aspirin.

Which one of the following would you recommend?

- A) Observation only
 - B) An ACE inhibitor
 - C) A β -blocker
 - D) A calcium channel blocker
 - E) A diuretic
75. A 66-year-old female with a previous history of hypertension, stable angina, and carotid endarterectomy presents with acute upper abdominal pain, which has developed over the past 3 hours. A physical examination reveals epigastric tenderness without guarding or rebound, but does not reveal a cause for the level of pain reported by the patient. Initial laboratory findings are within normal limits, including a CBC, glucose, lactic acid, amylase, lipase, liver enzymes, and kidney function tests. You suspect acute mesenteric ischemia.

Which one of the following diagnostic imaging tests is the preferred initial evaluation for this problem?

- A) Duplex ultrasonography
- B) CT angiography
- C) Catheter angiography
- D) Magnetic resonance angiography (MRA)
- E) Upper and lower GI endoscopy

76. A 38-year-old patient wishes to start contraception. She currently takes lisinopril (Prinivil, Zestril) for hypertension and also takes sumatriptan (Imitrex) occasionally for migraines at the first sign of flashing lights or zigzagging lines in her vision. Her medical, family, and social histories are otherwise unremarkable. An examination is notable only for a blood pressure of 130/80 mm Hg and a BMI of 36.0 kg/m².

The patient is interested in using either the vaginal ring or the contraceptive patch. Which one of the following would you recommend?

- A) Transdermal norelgestromin/ethinyl estradiol (Ortho Evra)
- B) The etonogestrel/ethinyl estradiol vaginal ring (NuvaRing)
- C) Neither method due to her migraines
- D) Neither method due to her age
- E) Losing weight before starting either method

77. A 45-year-old male sees you for follow-up of several chronic medical problems including hypertension, diabetes mellitus, and obesity. He is a truck driver, smokes one pack of cigarettes per day, and does not exercise. His blood pressure is 166/94 mm Hg and his hemoglobin A_{1c} is 9.7%. His medical conditions have been difficult to control with medications and he has been resistant to making lifestyle changes.

Which one of the following strategies would be most effective for inducing significant behavioral change?

- A) Counsel the patient on the complications of smoking and uncontrolled diabetes
- B) Utilize motivational interviewing to explore the patient's level of desire to change
- C) Treat the patient with an SSRI and refer him to a counselor
- D) Transfer the patient to another family physician in your community

78. A 47-year-old male who lives at sea level attempts to climb Mt. Rainier. On the first day he ascends to 3400 m (11,000 ft). The next morning he has a headache, nausea, dizziness, and fatigue, but as he continues the climb to the summit he becomes ataxic and confused.

Which one of the following is the treatment of choice?

- A) Administration of oxygen and immediate descent
- B) Dexamethasone, 8 mg intramuscularly
- C) Acetazolamide, 250 mg twice a day
- D) Nifedipine (Procardia), 10 mg immediately, followed by 30 mg in 12 hours
- E) Helicopter delivery of a portable hyperbaric chamber

79. A 60-year-old male presents with the lesion shown below. It has grown over the last few months. His past medical history includes well controlled hypertension. He takes lisinopril (Prinivil, Zestril), 10 mg daily, and aspirin, 81 mg daily.

After the diagnosis is established with a biopsy, which one of the following has the highest cure rate for this problem?

- A) Standard wide excision
- B) Electrodesiccation and curettage
- C) Mohs surgery
- D) Photodynamic therapy
- E) Radiation therapy

80. A 55-year-old female sees you for a preoperative evaluation prior to having cataract surgery. The patient has a previous history of type 1 diabetes mellitus. She reports that she takes a brisk daily walk and has no angina or other cardiac symptoms. The cardiovascular and pulmonary examinations are unremarkable.

Which one of the following would be most appropriate for the preoperative cardiac evaluation of this patient?

- A) No further evaluation
- B) An EKG
- C) A treadmill stress test
- D) Pharmacologic stress testing
- E) A chest radiograph

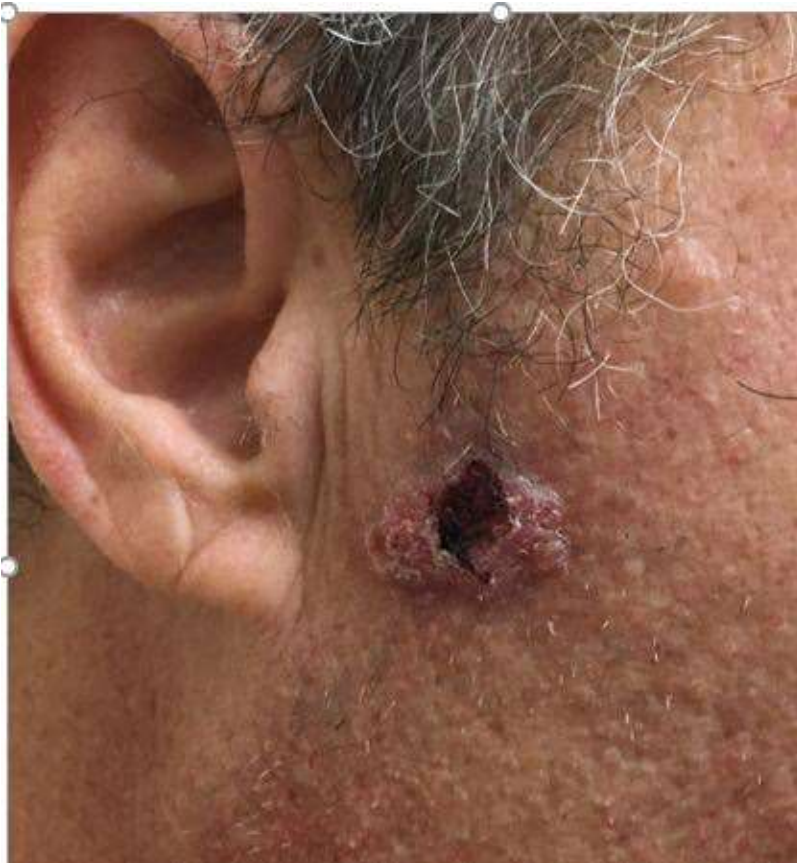81. The novel anticoagulants (NOACs) include apixaban (Eliquis), dabigatran (Pradaxa), edoxaban (Savaysa), and rivaroxaban (Xarelto). Which one of the following should be considered when starting or adjusting the dosage of a NOAC?

- A) Serum albumin
- B) INR
- C) Liver enzymes
- D) Partial thromboplastin time
- E) Renal function

82. A 42-year-old male with alcohol use disorder tells you that his last drink was 7 days ago and asks if there are any medications available to help him maintain abstinence from alcohol. He has no other medical or psychological problems.

Which one of the following pharmacologic agents could help reduce this patient's alcohol consumption and increase abstinence?

- A) Acamprosate
- B) Amitriptyline
- C) Paroxetine (Paxil)
- D) Promethazine
- E) Venlafaxine (Effexor XR)



Item #79

83. A 68-year-old male with a 40-pack-year history of smoking presents with a 2-month history of dyspepsia and difficulty swallowing. He also reports a 20-lb unintentional weight loss. He takes omeprazole (Prilosec), 20 mg daily.

Which one of the following would be most appropriate at this point?

- A) Increasing omeprazole to 40 mg twice daily
- B) Abdominal CT
- C) Barium esophagography
- D) Esophageal manometry
- E) Upper endoscopy

84. A 16-year-old white male sees you for a sports preparticipation examination. His height is 193 cm (76 in), his weight is 69 kg (152 lb), and he appears to have long arms. A physical examination reveals a high arched palate, kyphosis, myopia, and pectus excavatum.

Which one of the following valvular abnormalities is most likely in this patient?

- A) Mitral stenosis
- B) Pulmonic stenosis
- C) Aortic stenosis
- D) Aortic insufficiency
- E) Bicuspid aortic valve

85. A 46-year-old male with a 30-pack-year smoking history has had multiple episodes of coughing up blood that he describes as a “quarter size” amount. This has happened over the last couple of days. He has not had any chronic cough and has not been ill. A chest radiograph is negative.

Which one of the following would be the most appropriate management at this point?

- A) Observation with no further workup unless the cough persists for > 1 month or the quantity of hemoptysis increases
- B) CT of the chest
- C) Referral for bronchoscopy
- D) Referral for nasolaryngoscopy

86. A 68-year-old female presents for evaluation of shortness of breath with activity for the past several weeks. She used to walk 2 miles daily for exercise but can no longer do so because of dyspnea and chest tightness. She also reports mild lower extremity edema. She has a history of a bicuspid aortic valve and aortic stenosis. Echocardiography 1 year ago showed moderately severe aortic stenosis with a mean valve area of 1.1 cm^2 .

Echocardiography today shows aortic stenosis with an aortic valve area of 0.9 cm^2 , a mean pressure gradient of 42 mm Hg, and a transaortic velocity of 4.3 m/sec. The ejection fraction is estimated to be 50%.

Which one of the following is indicated at this time?

- A) Atorvastatin (Lipitor)
 - B) Furosemide (Lasix)
 - C) Lisinopril (Prinivil, Zestril)
 - D) Metoprolol succinate (Toprol-XL)
 - E) Referral for aortic valve replacement
87. You suspect a 45-year-old female may have irritable bowel syndrome. She has a 6-month history of crampy, diffuse abdominal pain associated with defecation. Her symptoms occur several days per week.

According to the Rome IV criteria, an associated symptom that would help in making this diagnosis is

- A) a change in stool frequency
 - B) increased gas and bloating
 - C) pain brought on by eating
 - D) waking up at night to defecate
 - E) weight loss of 5 lb (2 kg)
88. The U.S. Preventive Services Task Force recommends routine screening for gestational diabetes mellitus no sooner than
- A) 16 weeks gestation
 - B) 20 weeks gestation
 - C) 24 weeks gestation
 - D) 32 weeks gestation
89. A 20-year-old football player presents with pain in the proximal fifth metatarsal. The pain was initially present only after practices, but now it causes push-off pain during practice. There is tenderness to palpation. Plain films show no signs of fracture.

Which one of the following would be most appropriate at this point?

- A) Start NSAIDs and allow him to continue practicing as tolerated
- B) Place him at non-weight bearing for 2 weeks and repeat the plain films
- C) Place him in a hard shoe for 3 weeks and then reexamine
- D) Order MRI of the foot
- E) Order a bone scan of the foot

90. An 84-year-old female with severe dementia due to Alzheimer's disease is a resident of a long-term care facility. She has been hitting the staff while receiving personal care and recently had an altercation with another resident. Behavioral interventions have been unsuccessful in managing her symptoms and you suggest to the patient's family that she be started on low-dose risperidone (Risperdal). They ask about appropriate use of the drug and the potential for side effects.

Which one of the following would be appropriate advice?

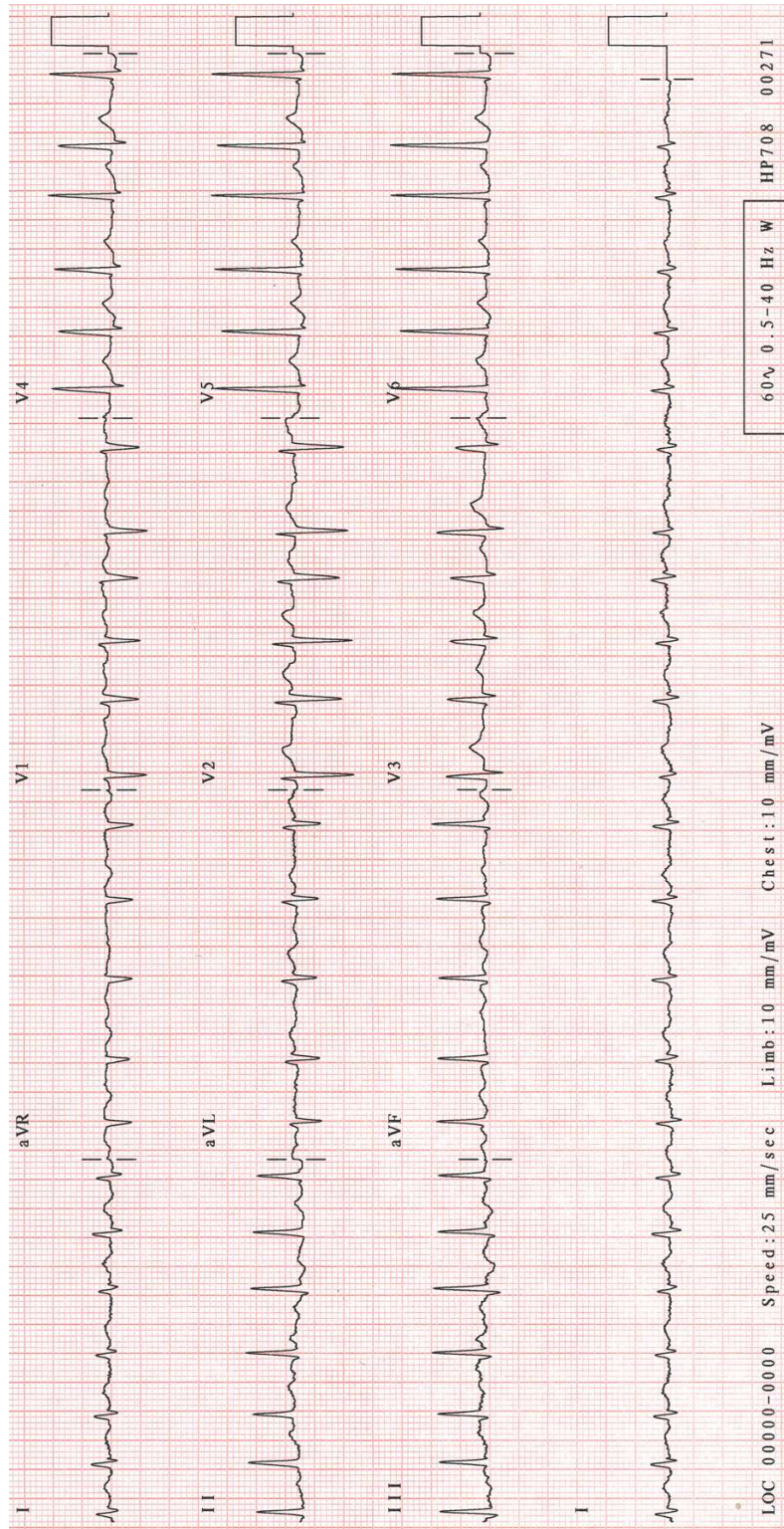
- A) Extrapyramidal side effects are more common compared to typical antipsychotics
 - B) Dementia-related psychosis is an FDA-approved indication
 - C) No monitoring will be necessary
 - D) The risk of diabetes mellitus is decreased
 - E) The risk of mortality is increased
91. Which one of the following diabetes mellitus medications is MOST likely to cause weight gain?

- A) Empagliflozin (Jardiance)
- B) Glimepiride (Amaryl)
- C) Liraglutide (Victoza)
- D) Metformin (Glucophage)
- E) Sitagliptin (Januvia)

92. A previously healthy 34-year-old female presents with a 1-hour history of palpitations. She does not have a cough, shortness of breath, wheezing, or chest pain. An EKG is shown below.

Which one of the following laboratory tests is most likely to demonstrate the cause of the patient's underlying problem?

- A) BNP
- B) D-dimer
- C) Lactic acid
- D) Troponin
- E) TSH



Item #92

93. A 14-year-old male is brought to your office with a 2-month history of a lump in his left chest. An examination reveals a slightly tender 2-cm area of concentric firm mobile tissue under the left areola. He has no skin changes, nipple discharge, or associated adenopathy. The right side is unremarkable. A genital examination reveals Tanner 3 development but is otherwise unremarkable. Growth curves are appropriate for the patient's age, with a BMI of 19.1 kg/m².

Which one of the following would be most appropriate at this point?

- A) Follow-up in 6–12 months
- B) A prolactin level
- C) Ultrasonography of the left breast
- D) Tamoxifen (Soltamox), 10 mg/day for 3 months
- E) A biopsy

94. A 52-year-old male presents for evaluation of a long-standing facial rash. He reports that the rash is itchy, with flaking and scaling around his mustache and nasolabial folds.

Which one of the following is most likely to be beneficial?

- A) Topical antibacterial agents
- B) Topical antifungal agents
- C) Topical vitamin D analogues
- D) Oral zinc supplementation

95. A 58-year-old male sees you for a routine health maintenance visit. He has a 20-pack-year smoking history and proudly tells you that he quit “for good” 1 year ago. You congratulate him on this accomplishment and encourage him to continue to abstain from tobacco. He has not seen a physician for 20 years.

U.S. Preventive Services Task Force recommendations for this patient include which one of the following?

- A) Abdominal aortic aneurysm screening
- B) Fall prevention screening
- C) Hepatitis C screening
- D) Lung cancer screening with low-dose CT

96. A 30-year-old female who gave birth to a healthy infant 3 months ago has had mildly depressed moods almost daily for the last 7 weeks. She takes very little joy in daily activities and interacting with her baby. She is exclusively breastfeeding and has difficulty sleeping. She says that she felt fine during the first month after the delivery, and has not experienced any homicidal or suicidal ideations. You rule out postpartum psychosis and bipolar disorder.

Which one of the following would be most appropriate at this point?

- A) Reassurance only
 - B) A home health visit
 - C) Oral contraceptives
 - D) Trazodone (Oleptro)
 - E) Referral for psychotherapy
97. Which one of the following is the preferred first-line agent in the treatment of rheumatoid arthritis?
- A) Adalimumab (Humira)
 - B) Etanercept (Enbrel)
 - C) Hydroxychloroquine (Plaquenil)
 - D) Methotrexate (Trexall)
 - E) Prednisone
98. A 68-year-old female sees you for a routine health maintenance visit. She feels well and says she has been eating more carefully and exercising for 45 minutes 4 days a week for the past 6 months. Her past medical history includes controlled hypertension and osteoarthritis of the knee. Her family history is notable for a myocardial infarction in her mother at 48 years of age. Her only medication is lisinopril (Prinivil, Zestril).

The physical examination is notable only for a BMI of 36.0 kg/m². Laboratory findings are notable for significant hyperlipidemia and you recommend starting a statin. She reports that she will undergo an elective total knee replacement next month and asks about the safety of starting a new medication before this surgery.

You recommend that she

- A) start a statin immediately to decrease her risk of cardiovascular disease and perioperative mortality
- B) start a statin immediately to decrease her risk of cardiovascular disease, although her risk of perioperative mortality will not be affected
- C) start a statin immediately to decrease her risk of cardiovascular disease, stop the statin 1 week before surgery, and resume taking it after the surgery, to decrease her risk of perioperative mortality
- D) start a statin immediately after the surgery to decrease her risk of cardiovascular disease and perioperative mortality
- E) start a statin after she is released postoperatively by her surgeon to decrease her risk of cardiovascular disease and perioperative mortality

99. A 40-year-old male presents to your office for follow-up of an abnormal clean-catch urine test performed at his employee health clinic during a preemployment screening examination. He had a positive urine dipstick for hemoglobin and 5 RBCs/hpf on microscopy. The urine was negative for protein, WBCs, and casts. A basic metabolic panel was notable for a creatinine level of 0.8 mg/dL (N 0.6–1.2) and a BUN of 15 mg/dL (N 8–23). He reports that he has been healthy and has not sought medical care in the last 5 years. He quit smoking 6 months ago and walks the dog daily for 30 minutes. A physical examination today is normal.

According to the guidelines of the American Urological Association, which one of the following would be the most appropriate next step in the workup?

- A) Repeat urine microscopy
 - B) Urine cytology
 - C) Cystoscopy
 - D) Renal ultrasonography
 - E) Retrograde pyelography
100. A 68-year-old female presents with a 3-month history of low back pain and fatigue. She has unintentionally lost 15 lb. A physical examination is positive for vertebral point tenderness over the third and fourth lumbar vertebrae. Initial laboratory testing reveals a normocytic anemia, elevated total protein, and a mild decrease in renal function.

You order a lumbar spine radiograph and additional diagnostic testing. Which one of the following would be most appropriate at this point?

- A) A serum ferritin level and iron studies
 - B) TSH and vitamin B₁₂ levels
 - C) Serum protein electrophoresis
 - D) MRI of the lumbar spine
 - E) A bone marrow biopsy
101. A 48-year-old female with type 2 diabetes mellitus has been unable to achieve optimal glycemic control with lifestyle modifications alone. You recommend that she start medication.

Which one of the following medications is generally recommended as the first-line medication for initiating treatment for type 2 diabetes mellitus?

- A) Alogliptin (Nesina)
- B) Empagliflozin (Jardiance)
- C) Glipizide (Glucotrol)
- D) Metformin (Glucophage)
- E) Pioglitazone (Actos)

102. A 22-year-old female presents to your office for evaluation of nasal and sinus congestion, frequent sneezing, and itchy red eyes. These symptoms have been present 5–7 days per week for the past 6 months. She has had similar symptoms in the past but they have never lasted this long. She moved into a new home 2 months ago. There are no animals in the house. She has tried over-the-counter fexofenadine (Allegra) with only partial relief of symptoms.

Which one of the following would be the most appropriate recommendation at this time?

- A) Use of a mite-proof impermeable pillow cover
- B) Intranasal saline irrigation
- C) Intranasal azelastine (Astepro)
- D) Intranasal budesonide (Rhinocort)
- E) CT of the sinuses

103. An elderly male presents with a shallow, irregularly shaped ulceration over the medial aspect of his right lower leg between the lower calf and medial malleolus. There is some surrounding edema with pigment deposition over the lower leg. He reports aching and burning pain in the lower leg with daytime swelling. His symptoms improve with leg elevation.

You make a diagnosis of venous stasis ulcer. Which one of the following would be the most appropriate management?

- A) The use of foam dressings rather than other standard dressings
- B) The use of silver-based antiseptic products even if there is no infection
- C) Compression therapy
- D) A 3-week course of systemic antibiotics

104. Which one of the following is the most reliable measure to protect children from lead toxicity in the United States?

- A) Anticipatory guidance for parents and caregivers during well child visits
- B) Checking the serum lead level after a known exposure
- C) Eliminating the sources of lead in the community
- D) Iron and calcium supplementation to reduce lead absorption
- E) Providing appropriate cleaning equipment to families with known lead in the home

105. A 64-year-old female with hypertension, diabetes mellitus, hyperlipidemia, and chronic kidney disease has had headaches that have been escalating over the past 6 months and are associated with double vision and ataxia. Her medications include lisinopril (Prinivil, Zestril) and atorvastatin (Lipitor). She weighs 61 kg (135 lb) and her blood pressure is 144/64 mm Hg. A basic metabolic panel is normal except for a creatinine level of 2.1 mg/dL (N 0.6–1.1) and an estimated glomerular filtration rate of 26 mL/min/1.73 m².

You decide to order MRI of the brain. Which one of the following would be most appropriate with regard to the use of gadolinium contrast in this patient?

- A) Use of gadolinium if the patient's blood pressure is controlled to a goal systolic pressure of < 130 mm Hg
- B) Use of gadolinium if the patient is pretreated with n-acetylcysteine and intravenous normal saline
- C) Use of gadolinium if lisinopril is stopped 48 hours before the MRI
- D) Avoiding the use of gadolinium contrast

106. A 29-year-old gravida 2 para 1 comes to the hospital for scheduled induction of labor. Her last delivery was a spontaneous vaginal delivery without complications. Her pregnancy has been uneventful. Oxytocin (Pitocin) is used during induction according to the hospital protocol and her labor progresses without difficulty.

Which one of the following should be AVOIDED to minimize the risk of postpartum hemorrhage in this patient?

- A) Administration of oxytocin with delivery of the anterior shoulder
- B) Controlled cord traction
- C) Active management of the third stage of labor
- D) Routine episiotomy
- E) Manual removal of a retained placenta

107. A 64-year-old male with midsternal chest pain is brought to the emergency department by ambulance. He is on oxygen and an intravenous line is in place. Shortly after arrival he loses consciousness and becomes pulseless and apneic, and CPR is begun. Cardiac monitoring shows ventricular tachycardia with a rate of 160 beats/min.

Which one of the following would be most appropriate at this point?

- A) Amiodarone, intravenous infusion, followed by synchronized cardioversion
- B) Adenosine (Adenocard), rapid intravenous push, repeated in 1–2 minutes if needed
- C) Epinephrine, intravenous push, followed by synchronized cardioversion
- D) Lidocaine (Xylocaine), intravenous push, repeated in 5 minutes if needed
- E) Defibrillation

108. In patients with COPD, which one of the following inhaled medications has been shown to reduce exacerbations and exacerbation-related hospitalizations?

- A) Albuterol (Proventil, Ventolin)
- B) Fluticasone (Flovent)
- C) Ipratropium (Atrovent)
- D) Salmeterol (Serevent)
- E) Tiotropium (Spiriva)

109. A 52-year-old male sees you for a routine health maintenance examination. He does not take any medications, does not drink alcohol, and is feeling well. A physical examination is normal with the exception of a BMI of 33.2 kg/m². Routine laboratory studies reveal mild elevations of ALT (SGPT) and AST (SGOT), which remain elevated on repeat testing 2 months later. Hepatitis B and hepatitis C testing are negative.

In addition to ultrasonography of the liver, which one of the following laboratory studies should be ordered to further evaluate this patient?

- A) Serum ferritin
- B) Serum phosphorus
- C) α -Fetoprotein
- D) Carcinoembryonic antigen (CEA)
- E) Serum protein electrophoresis

110. A 62-year-old white male with a 3-month history of diabetes mellitus has a hemoglobin A_{1c} of 7.8%. Which one of the following is the best parameter for determining if he can safely take metformin (Glucophage)?

- A) 24-hour urine for creatinine clearance
- B) BUN/creatinine ratio
- C) Estimated glomerular filtration rate
- D) Serum creatinine
- E) Urine microalbumin

111. A 43-year-old male presents with a 6-week history of right ankle pain. The pain worsens with walking or running for a moderate distance and fails to improve with heat application or reduction of activity. He has been following a moderate cardiovascular exercise program for several years without problems and did not increase his physical activity before the onset of the pain. He does not recall any injury to the ankle.

On examination the area of pain is localized in the right Achilles tendon proximal to its insertion. No swelling, redness, or deformity is apparent but tenderness is elicited with application of moderate fingertip pressure to the tendon.

Which one of the following would be the most appropriate initial treatment?

- A) Use of a heel cup in the right shoe
- B) A 1-month course of daily NSAIDs at a prescription dosage
- C) An eccentric gastrocnemius-strengthening program
- D) A corticosteroid injection into the right Achilles tendon sheath
- E) Immobilization of the right ankle for 3 weeks with a boot

112. A 45-year-old male presents to your office with a 2-month history of a nonproductive cough, mild shortness of breath, fatigue, and a 5-lb weight loss. On examination his lungs are clear. A PPD skin test is negative. A chest radiograph shows bilateral hilar adenopathy and his angiotensin converting enzyme level is elevated. A biopsy of the lymph node shows a noncaseating granuloma.

Which one of the following would be the most appropriate initial treatment?

- A) Azathioprine (Imuran)
- B) Fluconazole (Diflucan)
- C) Isoniazid
- D) Levofloxacin (Levaquin)
- E) Prednisone

113. A 40-year-old white female sees you for the first time. When providing a history she describes several problems, including anxiety, insomnia, fatigue, persistent depressed mood, and low libido. These symptoms have been present for several years and are worse prior to menses, although they also occur to some degree during menses and throughout the month. Her menstrual periods are regular for the most part.

Based on this history, the most likely diagnosis is

- A) premenstrual dysphoric disorder
- B) menopause
- C) dysthymia
- D) anorexia nervosa
- E) dementia

114. A 33-year-old gravida 3 para 2 presents for prenatal care 8 weeks after her last menstrual period. She asks if she will need any immunizations during this pregnancy.

Which one of the following vaccines is recommended for all women with each pregnancy?

- A) 13-valent pneumococcal conjugate vaccine (PCV13, Prevnar 13)
- B) Hepatitis B
- C) MMR
- D) Tdap
- E) Varicella

115. A 26-year-old male presents with a rash on his anterior neck in the area of his beard that has been present for over a year. On examination he has dark, curly facial hair, and you find slightly tender, red, hyperpigmented papules on the superior anterior neck.

Which one of the following would you recommend to improve this patient's rash?

- A) Shaving with a multi-blade razor
- B) Shaving with electric clippers
- C) Pulling the skin taut while shaving
- D) Plucking hairs rather than shaving
- E) Oral cephalexin (Keflex)

116. A 54-year-old male comes to your office to establish care. He has a past history of hypertension treated with lisinopril (Prinivil, Zestril) and hydrochlorothiazide but has not taken his medications for over a year. He does not have any symptoms, including chest pain, shortness of breath, or headache. On examination his blood pressure is 200/115 mm Hg on two separate readings taken 5 minutes apart. The remainder of the physical examination is normal.

Which one of the following management options would be most appropriate?

- A) Institute out-of-office monitoring with an ambulatory device and follow up in 2 weeks
- B) Restart the patient's previous antihypertensive medications and follow up within 1 week
- C) Administer a short-acting antihypertensive medication in the office to lower his blood pressure to <160/100 mm Hg
- D) Hospitalize for hypertensive emergency

117. A 17-year-old female comes to your office with an 8-month history of amenorrhea. Menarche occurred at age 12 and her menses were regular until the past year. On examination the patient's vital signs are in the normal range for her age but she has a BMI of 16.1 kg/m², which is below the third percentile for her age. She is a high school senior who dances with the local ballet company. She practices dance several hours a day and works out regularly. She tells you that she follows a strict 800-calorie/day diet to keep in shape for ballet.

You order a CBC, a comprehensive metabolic panel, a urine β -hCG level, FSH and LH levels, and a TSH level. Which one of the following is also recommended as part of the workup?

- A) An EKG
- B) Pelvic ultrasonography
- C) Abdominal/pelvic CT
- D) A DXA scan
- E) A nuclear bone scan

118. A 45-year-old electrician presents to your office with concerns about a bump on his left elbow. He does not recall any injury. The bump is painful to touch but causes no other symptoms. He is worried since it has been present for at least a month and never goes away.

On examination the patient is afebrile. He has a 4-cm movable fluctuant growth at the tip of his left olecranon that is slightly tender to touch. There is no warmth or erythema and he has full range of motion of his elbow. There is no other joint involvement.

Which one of the following would you recommend?

- A) No further evaluation
- B) Laboratory testing, including a CBC with differential
- C) Plain radiography
- D) Ultrasonography
- E) Aspiration

119. A 25-year-old gravida 1 para 0 at 24 weeks gestation comes to your office with right lower extremity swelling and pain. Her pregnancy has been uncomplicated so far and her only medication is a prenatal vitamin. She does not have chest pain, shortness of breath, or fever. She recently started feeling the baby move, and an anatomy scan at 20 weeks gestation was normal.

Lower extremity Doppler ultrasonography confirms a right lower extremity deep vein thrombosis (DVT). Laboratory studies including a CBC, coagulation studies, and renal function are normal.

Which one of the following would be the most appropriate initial treatment of her DVT?

- A) Oral apixaban (Eliquis)
- B) Oral aspirin
- C) Oral warfarin (Coumadin)
- D) Subcutaneous enoxaparin (Lovenox)
- E) Subcutaneous heparin

120. A 46-year-old female with a past medical history of polycystic ovary syndrome and migraine headaches presents with bilateral, hyperpigmented patches along her mandible. The patches are asymptomatic but bother her cosmetically and seem to be darkening.

Which one of her medications would be most likely to contribute to her melasma?

- A) B-complex vitamins
- B) Metformin (Glucophage)
- C) Oral contraceptives
- D) Spironolactone (Aldactone)
- E) Sumatriptan (Imitrex)

121. A 73-year-old female is brought to your office by her daughter, who is concerned that there may be some memory changes in her mother. She has noticed that her mother frequently repeats herself and has made several medication errors lately.

The patient has type 2 diabetes mellitus, hypertension, depression, and hypothyroidism. Her current medications include glyburide (DiaBeta), aspirin, lisinopril (Prinivil, Zestril), hydrochlorothiazide, atorvastatin (Lipitor), and sertraline (Zoloft).

A physical examination reveals a blood pressure of 136/72 mm Hg. She scores 26/30 on a Saint Louis University Mental Status (SLUMS) examination, which suggests mild cognitive impairment. A cardiac examination and a foot examination are normal.

Laboratory studies reveal a hemoglobin A_{1c} of 7.0% and a TSH level of 3.8 μ U/mL (N 0.4–4.2). A basic metabolic panel is normal and her glucose level is 93 mg/dL. A CBC is normal.

Which one of the following medications should be stopped in this patient?

- A) Atorvastatin
- B) Glyburide
- C) Hydrochlorothiazide
- D) Lisinopril
- E) Sertraline

122. A 75-year-old white male presents to your office following hospitalization for an episode of heart failure. His edema has resolved but he still becomes symptomatic with minor exertion such as walking less than a block. A recent chest radiograph shows cardiomegaly, and echocardiography reveals an ejection fraction of 25%. He is currently taking furosemide (Lasix), 20 mg daily; carvedilol (Coreg), 25 mg twice daily; and lisinopril (Prinivil, Zestril), 20 mg daily. His vital signs include a pulse rate of 60 beats/min, a blood pressure of 110/70 mm Hg, a respiratory rate of 18/min, and a temperature of 37.0°C (98.6°F). No crackles or hepatojugular reflux are noted on auscultation.

Which one of the following would improve this patient's symptoms and decrease his mortality risk?

- A) Digoxin
- B) Hydralazine and isosorbide dinitrate (BiDil)
- C) Hydrochlorothiazide
- D) Spironolactone (Aldactone)

123. A 67-year-old female who was recently diagnosed with colon cancer presented to the emergency department 2 days ago with acute shortness of breath and was diagnosed with a pulmonary embolism. She was started on enoxaparin (Lovenox) and was hemodynamically stable during her stay in the hospital. Her shortness of breath has improved and her oxygen saturation is currently 95% on room air.

Which one of the following would be most appropriate for this patient?

- A) Continue enoxaparin upon discharge
- B) Discontinue enoxaparin and start rivaroxaban (Xarelto)
- C) Discontinue enoxaparin and start warfarin (Coumadin)
- D) Start warfarin and continue enoxaparin until the INR is ≥ 2.0

124. A 32-year-old Yazidi female from Iraq is brought to your office to establish care. She is a refugee who was relocated 2 weeks ago.

Which one of the following would be appropriate at this visit?

- A) Having a family member who speaks English serve as an interpreter
- B) Screening for posttraumatic stress disorder
- C) Hepatitis B vaccine
- D) Varicella vaccine

125. A 35-year-old male has a negative past medical history and a normal physical examination. He reports that he smokes half a pack of cigarettes per day and has 3–4 beers per week. A comprehensive metabolic panel reveals an ALT (SGPT) of 30 U/L (N 10–40) and an AST (SGOT) of 84 U/L (N 10–30). The remaining laboratory studies are negative. There is no family history of liver disease.

The laboratory findings suggest which one of the following?

- A) Hepatitis C
- B) Hemochromatosis
- C) Gilbert syndrome
- D) Alcoholic liver disease
- E) Nonalcoholic liver disease

126. A 48-year-old female presents with dyspnea with exertion. She has never smoked. A physical examination is normal, including vital signs and pulse oximetry. A chest radiograph reveals mild hyperexpansion of the chest, and pulmonary function testing reveals an FEV₁/FVC ratio of 0.67, unchanged after bronchodilator use. An EKG and stress echocardiogram are normal. You suspect COPD.

Which one of the following is the most likely underlying cause of this patient's pulmonary disease?

- A) Allergic bronchopulmonary aspergillosis
- B) α_1 -Antitrypsin deficiency
- C) Hemochromatosis
- D) Primary pulmonary hypertension
- E) Hypertrophic obstructive cardiomyopathy

127. A 52-year-old pianist is concerned that she may have carpal tunnel syndrome. Which one of the following would be consistent with this problem?

- A) Weakness of thumb adduction
- B) Decreased sensation over the thenar eminence
- C) Decreased sensation over the dorsal aspect of the fourth finger
- D) Decreased sensation over the dorsal aspect of the fifth finger
- E) Decreased sensation over the palmar aspect of the thumb, index, and middle finger

128. A 67-year-old female with hypertension and atrial fibrillation has been taking warfarin (Coumadin) for the past 10 years. She has been hemodynamically stable for many years with no complications from her atrial fibrillation. She is scheduled to undergo elective bladder sling surgery for urinary incontinence. She does not have any other significant past medical history.

Which one of the following would be the most appropriate perioperative management of her warfarin?

- A) Continue warfarin without interruption
 - B) Discontinue warfarin the day prior to surgery and provide bridge therapy with low molecular weight heparin
 - C) Discontinue warfarin 2 days prior to surgery and restart it 2 days postoperatively unless there is a bleeding complication
 - D) Discontinue warfarin 2 days prior to surgery and restart it 5 days postoperatively unless there is a bleeding complication
 - E) Discontinue warfarin 5 days prior to surgery and restart it 12–24 hours postoperatively unless there is a bleeding complication
129. A 48-year-old female smoker presents with solid, but not liquid, dysphagia that causes her to feel as if food is “getting stuck.” She sometimes regurgitates this food. When you ask her where it feels like the food is sticking she points to a location below the suprasternal notch.

The most appropriate next step is

- A) a fluoroscopic swallowing study
- B) barium radiography
- C) CT of the chest
- D) endoscopy
- E) esophageal manometry

130. A 7-year-old female is brought to your office by her mother for follow-up of an urgent care visit. The child has a 5-day history of abdominal pain and low-grade fevers to 100.1°F. Her mother took her to an urgent care clinic last night when the patient developed the rash shown below. The rash is not pruritic or painful. She does not have any sick contacts, urinary symptoms, or changes in bowel habits.

A physical examination is normal except for the rash and minimal diffuse abdominal tenderness. A CBC and basic metabolic panel are normal and a urinalysis is notable only for microhematuria (30–40 RBCs/hpf) and mild proteinuria (30 mg/dL).

The following laboratory studies were obtained at the urgent care clinic.

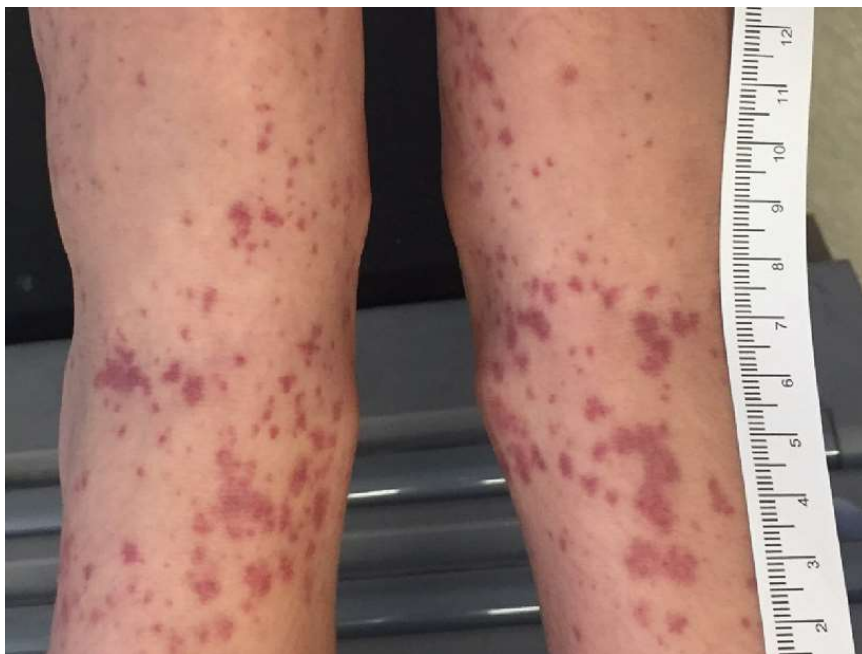Basic metabolic panel	normal
Urinalysis	
Color	yellow/clear
Leukocyte esterase	negative
Nitrite	negative
Protein	30 mg/dL (normal negative)
Glucose	negative (normal)
Bilirubin	negative (normal)
RBCs	34/hpf (N < 4)
WBCs	4/hpf (N < 5)
Bacteria	none
Squamous epithelial cells	< 1 (normal)
Ketones	negative (normal)
Blood	large (normal negative)
Urine Gram stain	no bacteria, no PMNs
Urine culture	negative × 24 hours

In addition to close follow-up, which one of the following is the next appropriate step in the management of this child?

- A) Supportive care only
 - B) Amoxicillin for 10 days
 - C) Prednisone tapered over 10 days
 - D) A biopsy of a skin lesion
 - E) Referral to a nephrologist for consideration of a renal biopsy
131. An 18-month-old female is brought to your office in January for evaluation of a cough and fever. She has no chronic medical conditions. She abruptly developed a barking cough and hoarseness with a low-grade fever 2 days ago. The cough is worse at night. She has been drinking normally but is not interested in eating. On examination she is alert and resists the examination. Her respiratory rate and effort are normal. She has no stridor or wheezing.

Which one of the following would be most appropriate at this point?

- A) A nasal swab for influenza testing
- B) A chest radiograph
- C) A single dose of oral dexamethasone
- D) Azithromycin (Zithromax)
- E) Oseltamivir (Tamiflu)



Item #130

132. You are reviewing the home health care progress report of a 68-year-old female who was hospitalized with pneumonia 2 months ago. The patient moved to the area to live with her daughter following treatment for breast cancer 5 years earlier. Before the hospitalization her only medical needs had been for preventive services, treatment for hypertension, and surveillance for problems related to her chemotherapy and for return of her cancer. During the recent hospitalization oxygen supplementation was required to maintain healthy oxygen saturation levels, and after failing several attempts at weaning, home oxygen service was arranged.

You ask the home health nurse to test the patient's oxygen saturation after 1 hour on room air and the nurse reports that the patient's oxygen saturation is now consistently above 90% on room air. The care plan provided by the home health service includes a recommendation for the continuation of supplemental oxygen.

Which one of the following would be most appropriate for this patient?

- A) Order arterial blood gas studies to confirm her oxygenation status
 - B) Discontinue oxygen supplementation
 - C) Discontinue daytime use of oxygen and continue nighttime oxygen
 - D) Continue oxygen use, but only as needed when short of breath
 - E) Continue oxygen use to obtain a saturation >92% on room air
133. A 27-year-old female with a past medical history of polycystic ovary syndrome (PCOS) would like to become pregnant. Which one of the following treatments for PCOS is associated with greater live-birth and ovulation rates?
- A) Finasteride (Proscar)
 - B) Letrozole (Femara)
 - C) Metformin (Glucophage)
 - D) Spironolactone (Aldactone)
134. A 58-year-old male with a history of tobacco and alcohol abuse presents with the sudden onset of many well circumscribed brown, oval, rough papules with a "stuck-on" appearance on his trunk and proximal extremities. On examination you also note an unintentional 6-kg (13-lb) weight loss over the last 3 months and conjunctival pallor. A review of systems is positive for more frequent stomachaches, decreased appetite, and mild fatigue.

You order a laboratory workup. Which one of the following would be most appropriate at this point?

- A) Reassurance that the skin lesions are benign
- B) A skin biopsy
- C) Referral to a dermatologist
- D) CT of the abdomen and pelvis
- E) Upper and lower endoscopy

135. A previously healthy 6-year-old male is brought to your office because he has a fever. After a complete history and physical examination you are concerned that the child has Rocky Mountain spotted fever.

Which one of the following would be the most appropriate management?

- A) Supportive care only
- B) Amoxicillin
- C) Doxycycline
- D) Rifampin (Rifadin)

136. A 38-year-old female presents for ongoing management of type 2 diabetes mellitus, obesity, and chronic abdominal pain related to her history of recurrent pancreatitis. She says that her self-monitored blood glucose has been running in the range of 200–300 mg/dL on most occasions. She is not currently taking any medications but has tried metformin (Glucophage) and extended-release metformin (Glucophage XR) unsuccessfully in the past. On both occasions she experienced worsening abdominal pain and diarrhea. She does not feel she can manage insulin and requests an oral medication. Her hemoglobin A_{1c} in your office today is 9.0%.

In addition to lifestyle and nutrition counseling, which one of the following would be the best treatment at this time?

- A) Restart metformin
- B) Start empagliflozin (Jardiance)
- C) Start liraglutide (Victoza)
- D) Start sitagliptin (Januvia)

137. According to the American Academy of Pediatrics guidelines, when school personnel suspect that a child has head lice, which one of the following is the most appropriate management strategy?

- A) The child should be sent home until treated, and a notice should be sent to the parents of the child's classmates that a case of lice has occurred at the school
- B) The child should be sent home and may return to school after an over-the-counter treatment has been started
- C) The child should be sent home and may return to school after treatment prescribed by a licensed clinician has been started
- D) The child should be sent home and may return to school once treatment has been completed and the child is free of all nits and lice
- E) The child should remain in class and should not be treated unless there is a clear diagnosis and live lice are seen

138. Which one of the following comorbidities would falsely lower the hemoglobin A_{1c} level in a patient with type 2 diabetes mellitus?

- A) Vitamin B₁₂ deficiency
- B) Iron deficiency anemia
- C) Hemolytic anemia
- D) Chronic kidney disease
- E) A history of splenectomy

139. A 52-year-old male with a long-standing history of hypertension, COPD, type 2 diabetes mellitus, and bipolar disorder is brought to your office by his daughter because of a new onset of tremors. He is currently taking aspirin, hydrochlorothiazide, atenolol (Tenormin), glyburide (DiaBeta), lithium, inhaled albuterol, and inhaled tiotropium (Spiriva). Except for a recent episode of dehydration, his medication has worked well and no medication changes have been made within the past 2 years. On examination his heart rate is 52 beats/min and a neurologic examination reveals mild ataxia and coarse tremors. The remainder of the physical examination is normal.

Which one of the following is the most likely cause of his clinical findings?

- A) Albuterol
- B) Atenolol
- C) Lithium
- D) Tiotropium

140. A previously healthy 57-year-old patient who smokes is hospitalized and treated with a fluoroquinolone for community-acquired pneumonia. Which one of the following could be expected with a 5-day course of antibiotics compared to a longer course in patients such as this?

- A) Slower clinical improvement
- B) Higher hospital readmission rates
- C) Higher mortality rates
- D) Slower resumption of normal activity
- E) No difference in clinical outcome

141. A 45-year-old female has a history of intermittent asthma and her only medication is an albuterol (Proventil, Ventolin) inhaler. Over the past 2 months her asthma has limited her activities. She is using her inhaler daily and waking up at night once or twice a week with a cough.

Which one of the following would be the preferred medication to control her asthma?

- A) Fluticasone (Flovent)
- B) Salmeterol (Serevent Diskus)
- C) Fluticasone/salmeterol (Advair)
- D) Montelukast (Singulair)

142. In addition to group B *Streptococcus* (GBS), which one of the following is the most common cause of neonatal sepsis?

- A) *Escherichia coli*
- B) Group A *Streptococcus*
- C) *Listeria monocytogenes*
- D) *Staphylococcus aureus*
- E) *Streptococcus pneumoniae*

143. The U.S. Preventive Services Task Force recommends which one of the following screening options for major depressive disorder (MDD) in adolescents 12–18 years of age?

- A) Do not screen because the harms outweigh the benefits
- B) Do not screen because valid screening tools are not available for this population
- C) Do not screen because reliable treatment options are not effective unless MDD is clinically apparent
- D) Screen if systems are in place for diagnosis, treatment, and follow-up
- E) The evidence is currently insufficient to recommend for or against screening

144. An otherwise healthy 64-year-old male comes to your office accompanied by his wife because of tinnitus that has affected both ears for the last 3 years. It has been most troublesome at bedtime. His wife says that he is becoming irritable and depressed because he is bothered by the buzzing in his ears many times during the day. His only medication is allopurinol (Zyloprim) for the prevention of gout.

The most likely identifiable cause of this patient's tinnitus is

- A) medication
- B) Meniere's disease
- C) temporomandibular joint dysfunction
- D) sensorineural hearing loss
- E) impacted cerumen

145. A 49-year-old male is concerned about lesions on his penis that he has noticed over the past 6 months. He was circumcised as a child and has had the same female sexual partner for 5 years. He does not have any pain, itching, or dysuria. On examination you note multiple reddish-blue papules on the scrotum and a few similar lesions on the shaft of the penis.

The most likely diagnosis is

- A) pearly penile papules
- B) lichen nitidus
- C) lichen sclerosus
- D) angiokeratomas
- E) squamous cell carcinoma in situ (Bowen's disease)

146. A 36-year-old female presents with a 10-year history of daily headaches. The headaches are bilateral, have a pressure and tightening quality, and are not aggravated by activity. They tend to worsen as the day progresses. There is no associated prodrome, nausea, or sensitivity to light or noise. A neurologic examination is normal.

Which one of the following has been shown to reduce the severity and duration of this type of headache?

- A) Amitriptyline
- B) OnabotulinumtoxinA (Botox)
- C) Propranolol
- D) Sertraline (Zoloft)
- E) Topiramate (Topamax)

147. A 38-year-old female with a 5-year history of diabetes mellitus has developed a “pins and needles” sensation in her feet. Which one of the following is considered first-line therapy for her condition?

- A) Acupuncture
- B) Lidocaine 5% spray
- C) Oxycodone (Roxicodone)
- D) Pregabalin (Lyrica)
- E) Venlafaxine (Effexor XR)

148. A 32-year-old female sees you for evaluation of hair loss. On examination she has a smooth, circular area of complete hair loss on her scalp with no other skin changes.

Which one of the following would you recommend?

- A) An oral antifungal agent
- B) Topical minoxidil (Rogaine)
- C) Topical immunotherapy
- D) Topical corticosteroids
- E) Intralesional corticosteroids

149. You are evaluating a 64-year-old female in the emergency department for pyelonephritis. Her past medical history is negative and she has previously been in good health. The patient appears acutely ill but is oriented. On examination her weight is 100 kg (220 lb), her temperature is 38.9°C (102.0°F), her pulse rate is 110 beats/min, her respiratory rate is 24/min, her blood pressure is 136/72 mm Hg, and her oxygen saturation is 94% on room air. Initial laboratory findings include a venous lactate level of 4.0 mmol/L (N 0.6–1.7).

You decide to start normal saline intravenously. Which one of the following would be the most appropriate initial rate?

- A) 100 mL/hr
- B) 150 mL/hr
- C) 200 mL/hr
- D) 3000 mL over 30 minutes
- E) 3000 mL over 3 hours

150. A 54-year-old female sees you for a wellness examination. Her last screening mammography 10 years ago revealed dense breasts but was otherwise normal.

A past history of which one of the following would indicate the need for MRI of the breasts?

- A) Very dense breasts
- B) Morbid obesity
- C) Combination estrogen/progesterone therapy for the last 3 years
- D) Chest radiation for Hodgkin's disease
- E) Radioiodine treatment for Graves disease

151. You prescribe amoxicillin suspension, 480 mg twice daily for 10 days, for a child who weighs 12 kg (26 lb). To decrease the risk of a dosing error with this prescription, you ask your nurse to provide the parents with appropriate education and

- A) a written copy of the prescription
- B) a disposable teaspoon
- C) a medication cup
- D) an oral syringe

152. A 26-year-old female presents with a skin rash and chronic diarrhea. She reports being previously diagnosed with eczema, and while the rash has responded well to topical corticosteroids it flares when they are stopped. The skin rash is very itchy and appears as mildly erythematous papules and vesicles clustered on the elbows and knees, as well as the posterior neck and scalp. A comprehensive metabolic panel is normal, and a CBC reveals a mild microcytic, hypochromic anemia. Antinuclear antibodies are negative, a TSH level is normal, and a tissue transglutaminase antibody test is positive.

Which one of the following is the most likely diagnosis?

- A) Cutaneous lupus erythematosus
- B) Dermatitis herpetiformis
- C) Eczema
- D) Eczema herpeticum
- E) Lichen simplex chronicus

153. You see a 26-year-old male for the first time. He has a history of major depression over the past 4–5 years. He currently does not take any medications. His psychiatric history reveals at least two episodes of mania, most recently 1 year ago when he was hospitalized during the episode.

Which one of the following is CONTRAINDICATED as monotherapy in treating this patient's depression at this time?

- A) Divalproex (Depakote)
- B) Fluoxetine (Prozac)
- C) Lamotrigine (Lamictal)
- D) Lithium
- E) Quetiapine (Seroquel)

154. A 35-year-old white female presents with recurrent wheezing and coughing over the past few weeks, and recent production of brown sputum plugs. She is a regular patient of yours and has a long history of asthma and multiple allergies. She has been treated four times in the last 3 months for asthma exacerbations and generally feels better the first day she takes her corticosteroid, but any attempt at tapering leads to a recurrence of symptoms. She previously had good control of her asthma, although she has required regular use of a high-dose inhaled corticosteroid and a long-acting β -agonist. In spite of just completing a course of levofloxacin (Levaquin) for suspected pneumonia she returns today with a recurrence of the same symptoms.

A physical examination is unremarkable with the exception of diffuse expiratory wheezing. She has no fever or other abnormal vital signs. A chest radiograph shows opacities in the upper and middle lobes and a CBC is concerning for eosinophilia.

Which one of the following is the most likely diagnosis?

- A) Allergic bronchopulmonary aspergillosis
- B) Community-acquired pneumonia
- C) Pulmonary embolism
- D) Medication nonadherence

155. An 89-year-old female with a history of hypertension and glaucoma is brought to the emergency department by her family with shortness of breath. She has been trying to get her home ready for sale prior to moving into an assisted living facility. She says that she has not been sleeping well for weeks because she is worried about the move.

On admission the patient has a blood pressure of 140/92 mm Hg, a pulse rate of 86 beats/min, a respiratory rate of 26/min, a temperature of 36.6°C (97.9°F), and an oxygen saturation of 95% on room air. A physical examination is normal other than faint basilar crackles. A chest radiograph shows a slightly prominent cardiac silhouette, peribronchial cuffing, and coarse perihilar lung markings. An EKG reveals a normal sinus rhythm with global T-wave inversion of the precordial and limb leads. Her troponin I peaks at 0.953 ng/mL (N 0.000–0.780). Echocardiography reveals a normal size right ventricle with moderate right ventricular hypokinesis, left ventricular apical ballooning, a left ventricular ejection fraction estimated at 30%, and a moderately increased pulmonary artery pressure estimated at 43 mm Hg. A radionuclide myocardial perfusion imaging study is normal.

Which one of the following is the most likely diagnosis?

- A) Acute coronary syndrome
- B) Acute pericarditis
- C) Cardiac amyloidosis
- D) Takotsubo cardiomyopathy
- E) Viral myocarditis

156. Which one of the following is the leading cause of cancer death in men in the United States?

- A) Colorectal cancer
- B) Liver cancer
- C) Lung cancer
- D) Non-melanoma skin cancer
- E) Prostate cancer

157. You see a patient who is being treated for opioid use disorder with buprenorphine. Which one of the following can be used as adjuvant treatment to reduce stress-related opioid cravings and increase abstinence?

- A) Clonidine (Catapres)
- B) Methadone
- C) Naloxone
- D) Naltrexone (Vivitrol)
- E) Nifedipine (Procardia)

158. A 5-month-old female is brought to your office for evaluation of a fever to 103.1°F over the past 2 days. Her immunizations are up to date. On examination she does not appear ill. Her vital signs include a rectal temperature of 39.0°C (102.2°F), a heart rate of 90 beats/min, a respiratory rate of 40/min, and an oxygen saturation of 98% on room air. The child is alert and responsive, appears well hydrated, and has no rash or petechiae. The HEENT examination, including fontanelles, is normal, the chest is clear, there are no murmurs, and the abdomen is soft.

Which one of the following would be most appropriate at this time?

- A) No further testing or treatment at this visit, with close outpatient follow-up
- B) A urinalysis and culture, with close outpatient follow-up
- C) A CBC with differential, a urinalysis and culture, and close outpatient follow-up
- D) A CBC, a urinalysis and culture, a chest radiograph, a lumbar puncture, and consideration of inpatient monitoring
- E) A CBC with differential, blood cultures, a urinalysis and culture, a chest radiograph, a lumbar puncture, and empiric inpatient antibiotic treatment

159. As the newly appointed medical director in your primary care community health center, you identify antibiotic stewardship as a priority. You communicate with all clinical and administrative staff members to express a consistent message to patients about appropriate indications for antibiotic use.

Which one of the following is an example of an action aimed at improving antibiotic prescribing practices?

- A) Avoiding the use of in-house rapid strep testing for pediatric patients
- B) Considering patient expectations and satisfaction when prescribing antibiotic therapy
- C) Ensuring that patients with common cold symptoms are seen for evaluation
- D) Reducing the use of clinical decision support tools in the electronic health record
- E) Writing a delayed antibiotic prescription when appropriate

160. The presence of RBC casts on microscopic examination of a spun urine sediment is pathognomonic for which one of the following conditions?

- A) Acute glomerulonephritis
- B) Acute papillary necrosis
- C) Acute pyelonephritis
- D) Acute tubular necrosis
- E) Nephrotic syndrome

161. A 15-year-old male sees you after injuring his right index finger while playing volleyball. He has pain and a flexion deformity at the distal interphalangeal (DIP) joint.

Which one of the following would be an indication for further evaluation before splinting?

- A) The patient wants to continue athletic activities
- B) The patient first presented for treatment 3 weeks after the injury
- C) The patient is unable to passively fully extend the joint
- D) The patient is unable to actively fully extend the joint
- E) A radiograph shows a bony avulsion of 10% of the joint space

162. A 42-year-old male presents with a fever, cough, and chest pain. A rapid influenza test is positive.

Which one of the following would be most appropriate for the management of this patient's pleuritic chest pain?

- A) Colchicine (Colcris)
- B) Hydrocodone
- C) Ibuprofen
- D) Prednisone
- E) Tramadol (Ultram)

163. A 55-year-old male sees you for an annual health maintenance visit. He is a former smoker and has a history of type 2 diabetes mellitus, hypertension, and hyperlipidemia. He had a normal colonoscopy at age 50, and had an ST-elevation myocardial infarction 2 years ago treated with a drug-eluting stent. He is currently asymptomatic and does not have any chest pain, hypoglycemia, dyspepsia, melena, or rectal bleeding. His medications include metformin (Glucophage), 2000 mg daily; glimepiride (Amaryl), 2 mg daily; bisoprolol (Zebeta), 5 mg daily; losartan/hydrochlorothiazide (Hyzaar), 50 mg/12.5 mg daily; rosuvastatin (Crestor), 20 mg daily; clopidogrel (Plavix), 75 mg daily; and aspirin, 81 mg daily. His blood pressure is 128/76 mm Hg and his heart rate is 63 beats/min. A physical examination is unremarkable. His hemoglobin A_{1c} is 6.4%.

You recommend that the patient stop taking

- A) aspirin
- B) clopidogrel
- C) aspirin and clopidogrel
- D) metformin

164. In a 60-year-old patient who has not previously received pneumococcal vaccine, which one of the following would be an indication for both 13-valent pneumococcal conjugate vaccine (PCV13, Prevnar 13) and 23-valent pneumococcal polysaccharide vaccine (PPSV23, Pneumovax 23)?

- A) Alcoholism
- B) Chronic renal failure
- C) Cigarette smoking
- D) COPD
- E) Diabetes mellitus

165. A 36-year-old male presents with a 2-day history of painless right-sided facial droop. There are no associated symptoms and his medical history is otherwise unremarkable. An examination is remarkable for an unfurrowed right brow, mouth droop, a sagging right lower eyelid, and a complete inability to move the muscles of the right face and forehead. No other weakness is elicited and no rash is seen.

Which one of the following would be the most appropriate management at this point?

- A) Reassurance only
- B) Valacyclovir (Valtrex) alone
- C) A tapering dose of prednisone alone
- D) Valacyclovir and a tapering dose of prednisone
- E) Immediate transfer to the emergency department

166. A 35-year-old female presents with fatigue. She has been falling asleep at work for the past 6 weeks. She is married with two children and works as a nurse at the community hospital. Since she returned to work 12 weeks ago after maternity leave, her infant has had multiple respiratory infections and has not slept well through the night. Her menstrual cycle has been irregular and heavy for the past several months. A CBC and TSH level are normal.

Which one of the following laboratory tests would be appropriate at this visit?

- A) 25-Hydroxyvitamin D
- B) β -hCG
- C) D-dimer
- D) A serum antibody test for Lyme disease

167. In a patient presenting with truncal obesity, hypertension, type 2 diabetes mellitus, hirsutism, osteopenia, and skin fragility, which one of the following tests is needed to confirm the diagnosis of Cushing syndrome?

- A) A dexamethasone suppression test
- B) Inferior petrosal sinus sampling
- C) Plasma corticotropin
- D) Plasma free cortisol
- E) Urinary free cortisol

168. A 42-year-old female presents with shortness of breath that has slowly worsened over the past 6 months. She can now walk only 10 feet without becoming short of breath. She does not have a cough or chest pain. Her history is significant only for obesity. She smoked one pack of cigarettes per day for 20 years and quit smoking 6 years ago. Her blood pressure is 138/88 mm Hg, pulse rate 92 beats/min, respiratory rate 18/min, and oxygen saturation 92% on room air. Her BMI is 42.4 kg/m².

Her heart has a regular rate and rhythm with no murmurs and her lungs are clear to auscultation. Her lower extremities have bilateral 1+ edema. A chest radiograph is normal. Spirometry reveals a decreased FVC with a normal FEV₁/FVC ratio. A CBC, a TSH level, and a basic metabolic panel are all normal except for a serum bicarbonate level of 35 mEq/L (N 22–29).

These findings are most consistent with

- A) asthma
 - B) COPD
 - C) obstructive sleep apnea
 - D) obesity hypoventilation syndrome
 - E) pulmonary fibrosis
169. You see a 58-year-old female who received a drug-eluting stent 10 days ago during a hospitalization for acute coronary syndrome and coronary artery disease. She asks for recommendations about anticoagulation. You determine that she is not at high risk for bleeding.

Which one of the following would you recommend?

- A) Long-term aspirin use
 - B) Clopidogrel (Plavix) and aspirin for 30 days and then aspirin alone
 - C) Clopidogrel alone for 1 year and then aspirin alone
 - D) Clopidogrel and aspirin for 1 year and then aspirin alone
 - E) Prasugrel (Effient) for 1 year with no anticoagulation after that
170. A 45-year-old female presents with throbbing right-sided heel pain that started a few weeks ago. She says the pain is worst in the morning and seems to improve during the day but will return after a long day on her feet. She does not have a history of trauma, change in exercise, unexplained fever, or unintended weight loss.

On examination the patient's vital signs are normal. You note pain on palpation of the right medial calcaneal tuberosity and along the plantar fascia, and pain with passive dorsiflexion of the right foot. The skin over the foot reveals no sign of trauma, lesions, or masses.

Which one of the following is the most likely cause of this patient's heel pain?

- A) The heel spur
- B) A calcaneal stress fracture
- C) Heel pad syndrome
- D) Plantar fasciitis
- E) Sever's disease

171. A 36-year-old female singer presents with a 10-day history of hoarseness. She has never smoked and does not take any medications. Her vital signs are normal. An oropharyngeal examination is normal, her chest is clear to auscultation, and there is no cervical adenopathy and no masses. She is anxious to be able to sing again as soon as possible.

Which one of the following would you advise at this time?

- A) No talking, whispering, or throat clearing for 48 hours
- B) No singing or loud talking for 5–7 days
- C) Nebulized hypertonic saline treatments 3 times daily for 2–3 days
- D) Nebulized ribavirin twice daily for 3 days
- E) Inhaled corticosteroids twice daily for 5 days

172. A 74-year-old female with a long-standing history of coronary artery disease is hospitalized for pneumonia. The patient improves with treatment and is hemodynamically stable. An EKG performed on the third day of hospitalization is shown below.

Which one of the following would be the most appropriate next step?

- A) Cardiac rhythm monitoring with no additional treatment
- B) Atropine
- C) Transcutaneous pacing
- D) Transvenous pacing

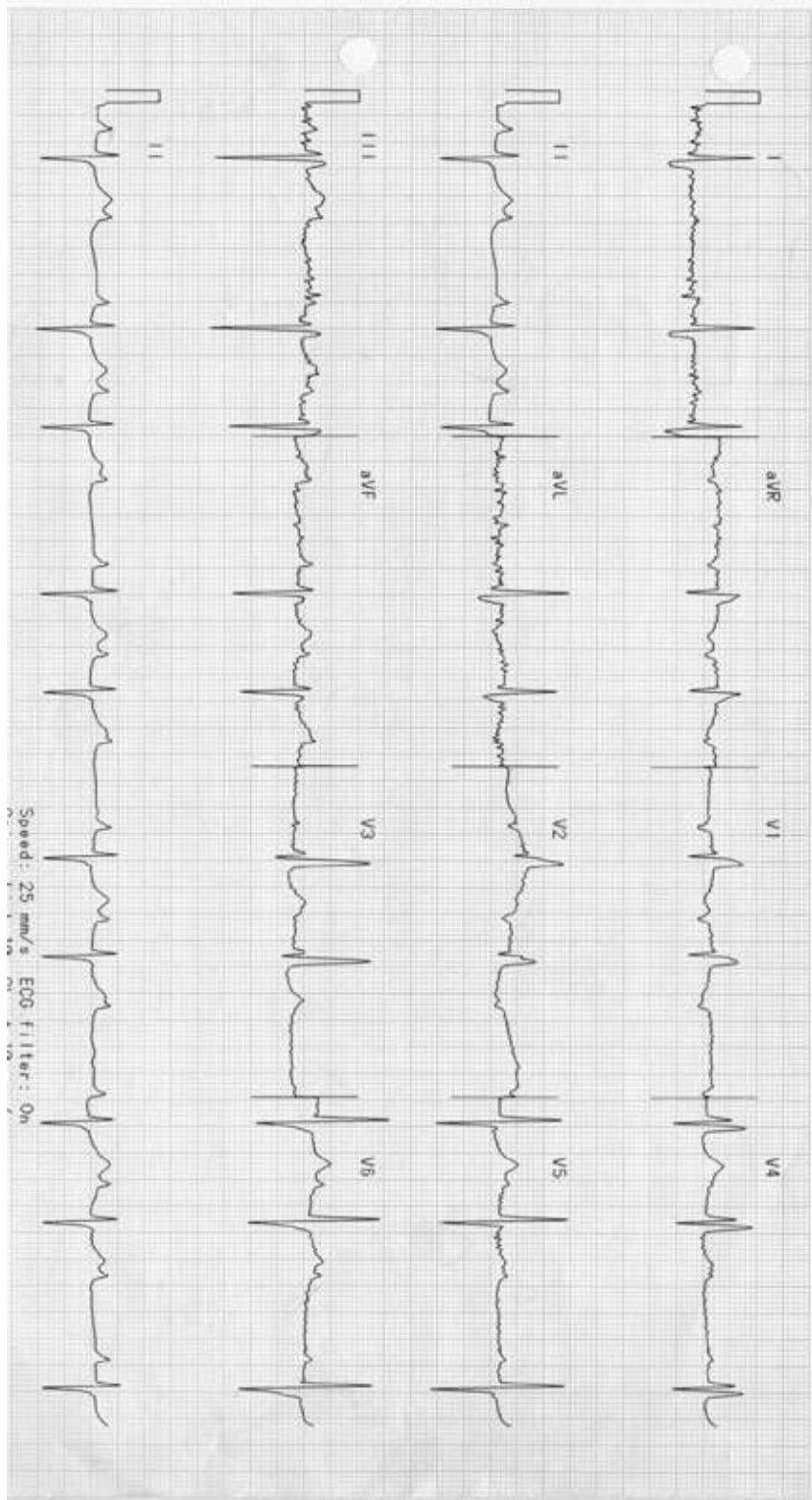
173. While sitting in the waiting room a patient develops the acute onset of diffuse hives, itching, and flushing; swelling of the lips, tongue, and uvula; and bilateral wheezing. He becomes weak and almost passes out.

Which one of the following would be the most appropriate immediate treatment?

- A) Corticosteroids
- B) Diphenhydramine (Benadryl)
- C) Epinephrine
- D) Glucagon
- E) Normal saline

174. A 50-year-old male with hypertension who is not at increased risk for gastrointestinal bleeding should begin low-dose aspirin at what 10-year risk level for cardiovascular disease?

- A) 1%
- B) 7.5%
- C) 10%
- D) 15%
- E) 20%



Item #172

175. A U.S. hospital or birthing center seeking to be certified as “Baby-Friendly” by the Baby-Friendly Hospital Initiative must satisfy which one of the following criteria in addition to meeting other requirements?

- A) Demonstrating proper use of an infant car seat to parents prior to discharge
- B) Providing no other food or fluids to breastfeeding infants without a medical indication
- C) Providing a pacifier to each baby prior to discharge
- D) Providing easy access to a variety of infant formulas
- E) Providing on-site daycare facilities for staff

176. A 50-year-old gravida 2 para 2 who is 3 years post menopausal presents with fatigue, headache, galactorrhea, and loss of libido. Your evaluation reveals elevated serum prolactin and a pituitary adenoma of 5–6 mm.

You recommend

- A) bromocriptine (Parlodel)
- B) estrogens
- C) haloperidol
- D) testosterone
- E) neurosurgical consultation

177. Referral for bariatric surgical evaluation is indicated for patients with a BMI of

- A) 35 kg/m² and mild cognitive impairment
- B) 36 kg/m² and type 2 diabetes mellitus
- C) 37 kg/m² and no other medical problems
- D) 40 kg/m² and active alcohol abuse
- E) 42 kg/m² and uncontrolled schizophrenia

178. A 75-year-old patient is admitted to the hospital. The Joint Commission National Patient Safety Goals program requires medication reconciliation for this patient both on admission and at the time of discharge.

The primary intent of this reconciliation is to detect

- A) potentially inappropriate medication use in the elderly
- B) high-risk medication use
- C) medication discrepancies
- D) polypharmacy
- E) adverse drug effects

179. A 29-year-old male smoker presents with a 10-day history of a cough. He also had a low-grade fever for 2 days that has resolved. He has had some mild rhinorrhea and has noted that the cough has become productive of greenish sputum over the past 3–4 days. He has not tried any medication. An examination reveals some mild rhinorrhea but his lungs are clear.

Which one of the following would be most appropriate at this point?

- A) Supportive care only
 - B) A chest radiograph
 - C) Albuterol (Proventil, Ventolin)
 - D) Antibiotic therapy
 - E) An inhaled corticosteroid
180. According to the recommendations of the American Heart Association, which one of the following patients requires endocarditis prophylaxis?
- A) A 10-year-old female with a previous history of Kawasaki disease without valvular dysfunction
 - B) A 22-year-old female who underwent surgical repair of a ventricular septal defect 1 year ago
 - C) A 28-year-old female with mitral valve prolapse without regurgitation
 - D) A 35-year-old female with a history of infectious endocarditis in her 20s that was related to intravenous drug use
 - E) A 42-year-old female with a history of rheumatic fever with chorea who has normal cardiovascular findings
181. A 69-year-old male presents with acute right hip pain, which has been worsening over the past week and is now causing difficulty walking. He has had occasional hip pain in the past but this is more severe than previous episodes. He has no history of trauma and he feels well otherwise. His medical history includes hypertension, hyperlipidemia, osteoarthritis, and psoriasis. His current medications include lisinopril/hydrochlorothiazide (Zestoretic), aspirin, and adalimumab (Humira).

An examination reveals normal vital signs and a BMI of 29.3 kg/m². The joint is not red or swollen. There is no tenderness over the greater trochanter, groin, or buttock. Active and passive range of motion of the hip is limited in all directions due to pain. A radiograph shows mild degenerative changes of the hip joint. A C-reactive protein level is mildly elevated.

Which one of the following would be indicated at this point to rule out a serious cause of joint pain?

- A) A radionuclide bone scan
- B) Arthrocentesis
- C) CT
- D) MR arthrography
- E) MRI

182. Which one of the following is the most appropriate psychotherapy for patients with obsessive-compulsive disorder?

- A) Traditional psychotherapy
- B) Cognitive-behavioral therapy
- C) Psychoanalysis
- D) Psychodynamic therapy

183. A 63-year-old female is concerned about her long-term use of medication. She has been taking omeprazole (Prilosec), 20 mg daily for the past 4 months, and tells you that it works well to relieve her symptoms of heartburn and regurgitation. She notes, however, that if she misses a dose her symptoms return.

You tell her that long-term proton pump inhibitor use is associated with which one of the following complications?

- A) Gastrointestinal malignancy
- B) Hip fracture
- C) Myocardial infarction
- D) Nephrotic syndrome
- E) Vitamin D deficiency

184. A 4-year-old male is brought to your office for a well child examination. The patient has no significant medical history. The mother has noted new skin lesions first appearing on the back, with a new lesion behind the right knee. She has not used any new detergents or skin or hair care products. She has not made any changes in the patient's diet. The child does not have pruritus.

The examination reveals a temperature of 37.2°C (99.0°F), a pulse rate of 80 beats/min, and a blood pressure within normal limits. The examination is unremarkable except for nonerythematous flesh-colored, dome-shaped papules with a central indentation, on the lower back and popliteal fossa.

Which one of the following would be most appropriate for the initial management of this condition?

- A) Observation only
- B) Consistent use of emollients and avoiding frequent hot baths
- C) Use of a topical low-dose corticosteroid cream once daily until resolved
- D) Use of a topical antifungal cream until resolved
- E) Paring, followed by topical salicylic acid or cryotherapy

185. A 34-year-old male has a 3-day history of a runny nose, postnasal drainage, sinus congestion, and left-sided facial pain. He also reports a mild cough and difficulty sleeping due to the congestion. He is afebrile and the examination reveals inflammation of the nasal mucosa, purulent rhinorrhea, and mild left maxillary sinus tenderness to percussion.

Which one of the following would be the most appropriate pharmacotherapy?

- A) Amoxicillin/clavulanate (Augmentin)
- B) Levofloxacin (Levaquin)
- C) Loratadine (Claritin)
- D) Mometasone (Nasonex)

186. At what age should a patient at average risk be switched from a universal screening strategy for colon cancer to a more individualized strategy?

- A) 45
- B) 55
- C) 65
- D) 75
- E) 85

187. An 18-month-old male is brought to your office for a well child check. He is walking only with assistance. You and the parents are concerned about gross motor delay.

Which one of the following findings would be most suggestive of muscular dystrophy in this patient?

- A) A cross-legged “scissoring” posturing
- B) Head lag when sitting up
- C) Hyperreflexia in the legs
- D) Partial hemiparesis of the lower extremities
- E) Toe walking

188. Which one of the following is most commonly associated with oligohydramnios?

- A) Anencephaly
- B) Esophageal atresia
- C) Hydrops
- D) Maternal α -thalassemia
- E) Posterior urethral valves

189. You see a 47-year-old female for follow-up of a rash. She is a carpenter and was seen 4 days ago for increasing redness and tenderness of her anterior shin after hitting the area with a board 3 days earlier. She was afebrile during that visit and the area was red but not fluctuant. She chose observation rather than treatment at that time. The patient smokes 10 cigarettes daily. Past medical, surgical, and family histories are otherwise negative. Screening for diabetes mellitus was normal last year.

Today the patient's anterior shin is still tender. She is afebrile and other vital signs are unremarkable. The extent of the infection was drawn 4 days ago with an indelible marker by your partner. Currently the area of redness extends beyond this border. There is no fluctuance or drainage of the wound. The skin appears mildly indurated.

Which one of the following would be best to provide coverage against *Streptococcus pyogenes* or methicillin-resistant *Staphylococcus aureus* (MRSA) in this patient?

- A) Amoxicillin/clavulanate (Augmentin) and ciprofloxacin (Cipro)
 - B) Cephalexin and dicloxacillin
 - C) Dicloxacillin and fosfomycin (Monurol)
 - D) Doxycycline and trimethoprim/sulfamethoxazole (Bactrim)
 - E) Trimethoprim/sulfamethoxazole and cephalexin
190. A 65-year-old male brings in results from a health fair screening. He was advised to see you because he had a hemoglobin level of 10.2 g/dL (N 14.0–18.0) and a mean corpuscular volume of 80 μm^3 (N 80–94). A review of systems is unremarkable except for recent fatigue, and a physical examination is also unremarkable. You order laboratory testing, with the following results:

Ferritin	15 ng/mL (N 20–150)
Vitamin B ₁₂	420 pg/mL (N 200–900)
Folate	12 ng/mL (N 2–20)
Reticulocyte index	0.3 % (N 0.5–1.0)

The most likely diagnosis is

- A) iron deficiency anemia
 - B) vitamin B₁₂ deficiency
 - C) anemia of chronic disease
 - D) hemolysis
 - E) myelodysplastic anemia
191. The mother of a newborn infant is concerned because her baby's eyes are sometimes crossed. Assuming the intermittent eye crossing persists, which one of the following is the most appropriate age for ophthalmologic referral?
- A) 10–14 days
 - B) 6 months
 - C) 12 months
 - D) 24 months

- 192.** A 47-year-old male presents with a 3-day history of fever, chills, low back pain, and urinary frequency. He does not have any nausea, vomiting, or abdominal pain. There is no significant past medical history.

The patient's vital signs include a temperature of 38.1°C (100.6°F), a pulse rate of 88 beats/min, and a respiratory rate of 14/min. The examination reveals a mildly tender lower abdomen with no guarding or rebound tenderness; no costovertebral angle tenderness; and an enlarged, homogeneous, exquisitely tender prostate.

Which one of the following is indicated to help guide this patient's treatment?

- A) A serum prostate-specific antigen level
 - B) A culture of prostate secretions after massage of the prostate
 - C) A culture of midstream voided urine
 - D) CT of the abdomen and pelvis with intravenous and oral contrast
 - E) An ultrasound-guided prostate biopsy
- 193.** A 57-year-old female is admitted to the hospital with lower lobe pneumonia. She has no history of diabetes mellitus. She has not met sepsis criteria but had a blood glucose level of 172 mg/dL in the emergency department.

Insulin should be started if this patient has a persistent blood glucose level greater than or equal to

- A) 120 mg/dL
 - B) 140 mg/dL
 - C) 160 mg/dL
 - D) 180 mg/dL
- 194.** A healthy 33-year-old male sees you for a pretravel consultation. He plans to attend a 4-week intensive Spanish language course in Antigua, Guatemala. You discuss immunizations, malaria prophylaxis, injury prevention, and traveler's diarrhea.

Which one of the following interventions is most likely to prevent traveler's diarrhea?

- A) Avoiding food from street vendors
- B) Avoiding the use of ice in beverages
- C) Taking a probiotic
- D) Taking a prophylactic antibiotic
- E) Washing hands frequently

195. A 52-year-old male smoker presents to your office in January with worsening respiratory symptoms over the past 24 hours, along with a rapid onset of fever and chills, nausea, myalgias, and sore throat. He has a history of mild chronic bronchitis and hypertension, and his medications include tiotropium (Spiriva) inhaled daily; lisinopril/hydrochlorothiazide (Zestoretic), 20/12.5 mg daily; and albuterol (Proventil, Ventolin) as needed.

On examination the patient has a temperature of 38.8°C (101.8°F), a heart rate of 102 beats/min, a respiratory rate of 24/min, and an oxygen saturation of 94% on room air. He is ill-appearing and pale. Examination of his throat reveals mild erythema, and chest auscultation reveals bilateral bronchovesicular breath sounds with no crackles or wheezing. The examination is otherwise unremarkable. Laboratory and radiology services are not available.

Which one of the following would be most appropriate at this point?

- A) Observation only, with follow-up in a few days
 - B) Azithromycin (Zithromax)
 - C) Oseltamivir (Tamiflu)
 - D) Penicillin VK
 - E) Prednisone
196. A 33-year-old gravida 2 para 2 presents with a 1-year history of amenorrhea, hot flashes, and vaginal dryness. She previously had normal menses and takes no medications. Her past medical and surgical histories are negative. The patient is 178 cm (70 in) tall and her BMI is 22.0 kg/m². Her vital signs are normal. A physical examination is normal except for vaginal dryness. Laboratory studies reveal a negative urine pregnancy test, normal TSH and prolactin levels, and elevated LH and FSH levels.

The most likely diagnosis is

- A) intrauterine synechiae (Asherman syndrome)
 - B) functional hypothalamic amenorrhea
 - C) polycystic ovary syndrome
 - D) primary ovarian insufficiency
 - E) Turner's syndrome
197. A 62-year-old female presents for a health maintenance visit. She is interested in staying up to date on her preventive care recommendations. She smoked for 4 years during college. Her BMI is 23.0 kg/m². She feels well and does not have any specific health concerns. She had a colonoscopy 4 years ago and no polyps were found. A screening mammogram 6 months ago was normal.

Which one of the following screening measures is recommended by the U.S. Preventive Services Task Force for this patient?

- A) A urinalysis to detect asymptomatic bacteriuria
- B) Measurement of hemoglobin A_{1c}
- C) Screening for hepatitis A and B viruses
- D) Screening for hepatitis C virus
- E) Lung cancer screening with low-dose CT of the lungs without contrast

198. A 69-year-old male presents for follow-up of hypertension treated with spironolactone (Aldactone) and amlodipine (Norvasc). His past medical history is remarkable only for a kidney stone several years ago. A physical examination is unremarkable. A comprehensive metabolic panel is unremarkable except for a calcium level of 12.0 mg/dL (N 8.0–10.0).

Which one of the following is the most likely cause of his elevated calcium level?

- A) Excessive ingestion of calcium supplements
- B) His current medication regimen
- C) Occult malignancy
- D) Primary hyperparathyroidism
- E) Vitamin D deficiency

199. A 7-month-old male is admitted to the hospital for respiratory syncytial virus bronchiolitis. His temperature is 37.9°C (100.2°F), pulse rate 160 beats/min, respiratory rate 70/min, and oxygen saturation 92% on room air. Auscultation of the lungs reveals diffuse wheezing and crackles accompanied by nasal flaring and retractions.

Which one of the following interventions would most likely be beneficial?

- A) Bronchodilators
- B) Corticosteroids
- C) Epinephrine
- D) Nasogastric fluids
- E) Oxygen supplementation to maintain O₂ saturation above 95%

200. A 30-year-old male presents with intermittent right upper quadrant pain after meals. He has been in moderate pain for the past 3 hours. On examination the patient's vital signs are normal except for a temperature of 39.2°C (102.6°F). He appears toxic. Examination of the abdomen reveals a positive Murphy's sign.

Laboratory Findings

WBCs	3000/mm ³ (N 4300–10,800)
ALT (SGPT)	132 U/L (N 10–55)
AST (SGOT)	123 U/L (N 9–25)
Alkaline phosphatase	200 U/L (N 45–115)
Bilirubin	2.6 mg/dL (N 0.0–1.0)
Lipase	15 U/dL (N 3–19)

Ultrasonography reveals cholelithiasis. Other findings include an enlarged gallbladder, thickening of the gallbladder wall, and a common bile duct diameter of 11 mm.

Which one of the following is the most likely cause of this patient's symptoms?

- A) Acute cholangitis
- B) Acute viral hepatitis
- C) Cholangiocarcinoma
- D) Gallstone pancreatitis

201. A 73-year-old female presents with a 3-day history of pain, numbness, and weakness in her right arm and shoulder. She reports that the problem began when she went out for a walk, tripped on an asphalt ledge, and fell to the ground. She was able to get herself back up and walk home but has had upper extremity problems since then. Her chronic medical conditions include early Alzheimer's dementia and hyperlipidemia. After a full examination you order radiographs (shown below).

Which one of the following would be most appropriate at this point?

- A) Figure-of-eight bandaging
- B) Physical therapy
- C) Shoulder reduction
- D) Sling immobilization
- E) Surgical decompression

202. The U.S. Preventive Services Task Force recommends which one of the following for women who are planning on or are capable of becoming pregnant?

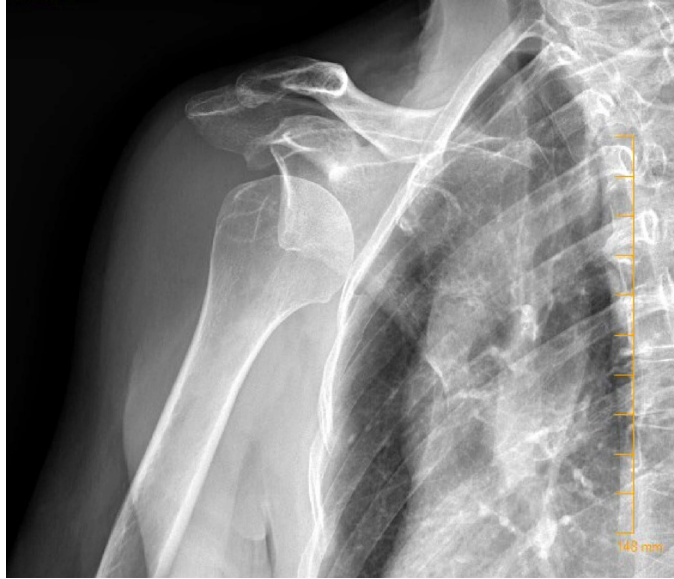- A) Testing for hepatitis C
- B) Annual pelvic examinations
- C) Folic acid, 0.4–0.8 mg daily
- D) Vitamin B₁₂, 1000 µg daily
- E) Vitamin D, 400–800 IU daily

203. An 11-year-old female is brought to your office for a well child visit. The mother is concerned because the patient's back seems to have a curve. The patient is not aware of this although she has frequent back pain.

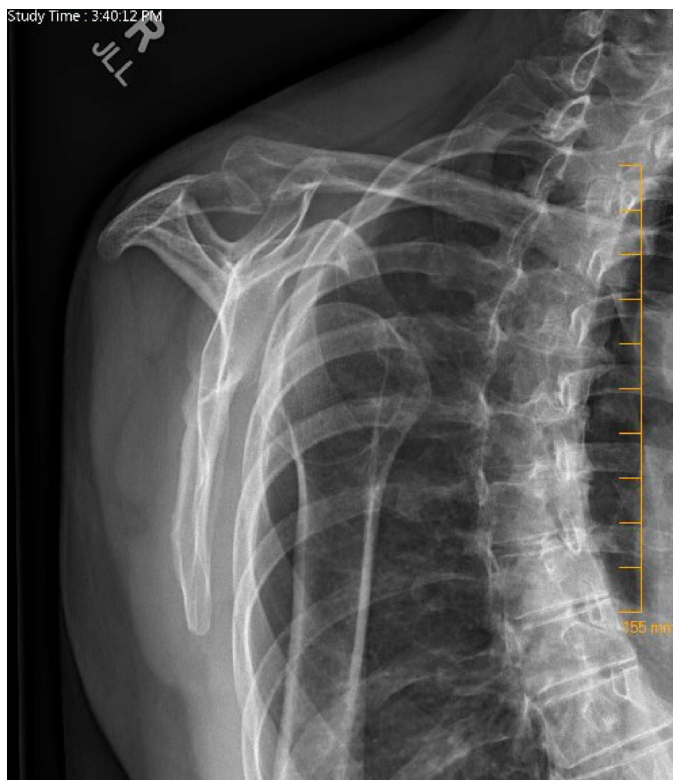
An examination is notable for a BMI above the 95th percentile for her age, and breast bud development. Menarche has not occurred. When she leans forward with her arms outstretched there is a 12° curve in her spine with a rib hump. Radiography reveals a measured Cobb angle of 20°.

Which one of the following indicates a need for referral to a specialist?

- A) Back pain
- B) A Cobb angle of 20°
- C) Female sex
- D) Obesity
- E) Premenarchal status



Item #201



Item #201

204. A healthy 43-year-old executive presents with problems falling asleep and staying asleep. Doxepin (Silenor) and extended-release melatonin have not helped.

In addition to behavioral interventions, which one of the following would be the most appropriate pharmacologic therapy for this patient's insomnia at this time?

- A) Diphenhydramine (Benadryl)
- B) Doxylamine (Unisom)
- C) Eszopiclone (Lunesta)
- D) Olanzapine (Zyprexa)
- E) Zaleplon (Sonata)

205. A 46-year-old male presents with a persistent cough that has been present for several months and was not preceded by an upper respiratory infection. He does not have a history of asthma, does not smoke, and takes no medications. His symptoms consist of short bursts of coughing that produce a small amount of mucoid sputum during the day. He does not have emesis or nausea. The cough sometimes wakes him at night but does not seem to be specific to any particular posture. He does not have a fever, shortness of breath, wheezing, heartburn, or nasal symptoms. A thorough physical examination is normal and a chest radiograph appears normal.

Which one of the following would be the most appropriate next step in the management of this patient?

- A) Amoxicillin/clavulanate (Augmentin)
- B) An empiric trial of a proton pump inhibitor
- C) CT of the chest
- D) CT of the sinuses
- E) Referral for bronchoscopy

206. A 25-year-old female comes to your office at 30 weeks gestation for a routine obstetric follow-up. Her pregnancy has been uncomplicated except for a lack of insurance. She is an immigrant from Guatemala and does not speak English. You have used a telephone interpreting service for her previous visits, but today her 15-year-old niece is with her and she says that she would be happy to interpret for you.

Which one of the following would be most appropriate?

- A) Have the niece ask the patient for permission to act as interpreter
- B) Proceed with the visit, since it is unlikely that you will need to discuss complicated medical issues
- C) Confirm the niece's significant understanding of English, then have her interpret
- D) Recommend the use of the telephone interpreting service as best medical practice
- E) Tell her that it is illegal to use interpreters who are not certified

207. A 65-year-old female presents for follow-up of a DXA scan for osteoporosis screening. Results of the scan reveal osteopenia, with a T-score of -2.0 .

Treatment for osteopenia is indicated when the 10-year risk of a major fracture reaches

- A) 5%
 - B) 10%
 - C) 20%
 - D) 35%
208. A 21-year-old gravida 1 para 0 is diagnosed with overt hyperthyroidism early in the first trimester. The most appropriate management at this time is
- A) observation only
 - B) methimazole (Tapazole)
 - C) propylthiouracil
 - D) radioactive iodine
 - E) thyroidectomy
209. A 55-year-old male presents with severe pain, swelling, and erythema in his left first metatarsophalangeal joint. His symptoms started yesterday and he has never had this problem in the past. He has a history of hypertension, but normal renal function and no diabetes mellitus. There is no overlying skin lesion or obvious source of infection.
- Which one of the following would be the most appropriate treatment for this patient?
- A) Allopurinol (Zyloprim)
 - B) Cephalexin (Keflex)
 - C) Colchicine (Colcrys)
 - D) Febuxostat (Uloric)
210. A 30-year-old male is treated with topical medications for his papulopustular rosacea with only partial improvement. The preferred antibiotic is
- A) amoxicillin
 - B) cephalexin (Keflex)
 - C) doxycycline
 - D) erythromycin
 - E) trimethoprim/sulfamethoxazole (Bactrim)

211. A 75-year-old female sees you because of a bulge at the vaginal opening. A pelvic examination confirms descent of the vaginal wall to just beyond the hymen. This protrusion is bothering her and interfering with her quality of life. She has had two vaginal deliveries. She is sexually active and has not had any pelvic surgery.

Which one of the following would be the most appropriate initial treatment for this problem?

- A) Kegel exercises
- B) A ring pessary
- C) A space-occupying pessary
- D) Hysteropexy
- E) Hysterectomy

212. A mother brings in her 2-week-old infant for a well child check. She reports that she is primarily breastfeeding him, with occasional formula supplementation.

Which one of the following should you advise her regarding vitamin D intake for her baby?

- A) Breastfed infants do not need supplemental vitamin D
- B) He does not need supplemental vitamin D if he is taking at least 16 oz of formula per day
- C) Vitamin D supplementation should not be started until he is at least 6 months old
- D) He should be given 400 IU of supplemental vitamin D daily
- E) Intake of vitamin D in excess of 200 IU/day is potentially toxic

213. A 70-year-old male comes to your office for preoperative clearance for a right total hip replacement. He is a nonsmoker and has a history of mild hypertension controlled with amlodipine (Norvasc). The history indicates that he is able to perform 7–8 METS of activity without any concerning symptoms. A physical examination, including vital signs, is normal.

Your evaluation should include which one of the following tests?

- A) A chest radiograph
- B) Coagulation testing
- C) An EKG
- D) Liver function studies
- E) Renal function studies

214. A 12-year-old female is brought to your office with a 3-week history of left groin pain that is most bothersome after she participates in gym class at her middle school. She does not recall a specific injury and does not participate in extracurricular sports. She had an upper respiratory infection about a month ago but has otherwise been well.

An examination reveals a BMI at the 95th percentile for her age. Her vital signs are within normal limits. A musculoskeletal examination is remarkable for limited internal rotation of the hip.

Which one of the following is the most likely diagnosis?

- A) Adductor muscle strain
- B) Apophysitis of the anterior superior iliac spine
- C) Legg-Calvé-Perthes disease
- D) Slipped capital femoral epiphysis
- E) Transient synovitis

215. A 36-year-old male presents with a 4-month history of persistent nasal congestion and rhinorrhea. On examination he has clear nasal discharge and edema of the nasal mucosa but no nasal polyps are noted. His current medications include intranasal fluticasone (Flonase).

Which one of the following would be the most appropriate management of his chronic symptoms?

- A) Recommend neti pot nasal irrigation
- B) Add oral amoxicillin
- C) Add oral prednisone
- D) Replace fluticasone with budesonide (Rhinocort) nasal spray

216. A 45-year-old male with a 30-pack-year smoking history reports a chronic cough with a small amount of phlegm production and dyspnea with strenuous exercise. You order spirometry, which shows a pre- and postbronchodilator FEV₁/FVC ratio of 0.6 and an FEV₁ of 85% of predicted.

Which one of the following agents would be the best initial pharmacologic management?

- A) An inhaled corticosteroid
- B) A short-acting anticholinergic
- C) A long-acting anticholinergic
- D) A long-acting β_2 -agonist
- E) Theophylline

217. A 50-year-old female sees you for follow-up of her hypertension. At her last visit 4 weeks ago you started her on lisinopril (Prinivil, Zestril), 10 mg daily, because of a blood pressure of 158/92 mm Hg and confirmed hypertension on ambulatory blood pressure monitoring. She is tolerating the medication well and has no side effects. She does not take any other medications. Today her blood pressure is 149/90 mm Hg, which you confirm on repeat measurement. This is also consistent with her home measurements. At her last visit a basic metabolic panel was normal.

You repeat a basic metabolic panel today and the results are normal except for a BUN of 25 mg/dL (N 8–23) and a creatinine level of 1.5 mg/dL (N 0.6–1.1). At her last visit her BUN was 12 mg/dL and her creatinine level was 0.7 mg/dL.

Which one of the following would be most appropriate at this time?

- A) Continue her current treatment regimen
 - B) Increase lisinopril to 20 mg daily
 - C) Continue lisinopril at the current dosage and add amlodipine (Norvasc), 5 mg daily
 - D) Discontinue lisinopril and begin amlodipine, 5 mg daily
 - E) Discontinue lisinopril and begin losartan (Cozaar), 25 mg daily
218. A 50-year-old female presents with pain in her right forefoot. She recently ran her first full marathon after several years of inactivity and says the pain started gradually over the last few weeks of her training and has slowly gotten worse. You order radiographs of the foot, which show a stress fracture of the second metatarsal.

You would recommend

- A) resumption of regular activity if the pain does not recur with activity after 1 week of rest
- B) no weight bearing on the right foot for 6 weeks
- C) no weight bearing for a few days, followed by a walking boot, then a rigid-soled shoe in 4–6 weeks
- D) a walking boot for 12 weeks
- E) referral to an orthopedic surgeon for further evaluation

219. A healthy 55-year-old white male with a family history of coronary artery disease sees you for a routine health maintenance visit. He asks you what he could do to decrease his risk of cardiovascular disease. He is a nonsmoker, does not drink alcohol, and has no history of substance abuse. His BMI is normal and the physical examination is otherwise unremarkable. His vital signs include a heart rate of 80 beats/min, a blood pressure of 119/70 mm Hg, a respiratory rate of 15/min, and a temperature of 37.0°C (98.6°F).

Laboratory Findings

Fasting glucose.	92 mg/dL
Total cholesterol.	190 mg/dL
LDL-cholesterol.	98 mg/dL
HDL-cholesterol	50 mg/dL
Triglycerides	145 mg/dL

His calculated 10-year risk for cardiovascular disease is 5.4%. Which one of the following has the best evidence to prevent cardiovascular disease in a patient such as this?

- A) Moderate-intensity exercise, 150 minutes weekly
 - B) A low-dose statin
 - C) Aspirin, 81 mg daily
 - D) Fish oil supplements
 - E) Niacin supplements
220. An asymptomatic 42-year-old female sees you for a routine evaluation. On examination her uterus is irregularly enlarged to the size seen at approximately 8 weeks gestation. Pelvic ultrasonography shows several uterine fibroid tumors measuring <5 cm. The patient does not desire future fertility.

Which one of the following would be the most appropriate management option?

- A) Observation only
 - B) An oral contraceptive
 - C) A gonadotropin-releasing hormone (GnRH) agonist
 - D) Laparoscopic myomectomy
 - E) Hysterectomy
221. A 34-year-old female sees you because of cramping diarrhea for the past several months following resection of her terminal ileum as treatment for Crohn's disease. She is not aware of any exposure to individuals with similar symptoms. She has not had any fever, chills, nausea, vomiting, or myalgias, and she has not noticed any blood in her stool. She is passing several loose stools daily, mostly after meals. She has not been able to identify any clear relationship to the type of food she eats.

Which one of the following would be the best initial treatment option for this patient?

- A) A dairy-free diet
- B) Cholestyramine (Questran) daily
- C) A *Lactobacillus* probiotic supplement (Lactinex) 4 times daily
- D) Loperamide (Imodium) as needed
- E) Psyllium fiber (Metamucil) twice daily

222. A 48-year-old male comes to your office for follow-up of recently diagnosed panic attacks. As part of his treatment plan he is taking sertraline (Zoloft), 50 mg daily, and working with a mental health provider who has diagnosed posttraumatic stress disorder associated with a traumatic childhood. He reports that his sleep continues to be interrupted by nightmares.

Which one of the following additional medications may provide long-term control of his symptoms?

- A) Atenolol (Tenormin)
- B) Lorazepam (Ativan)
- C) Prazosin (Minipress)
- D) Risperidone (Risperdal)
- E) Zolpidem (Ambien)

223. A 55-year-old female presents with a 3-month history of right shoulder pain. The pain has begun to limit some daily activities such as brushing her hair and reaching high shelves, and it is waking her up at night, especially when she lies on her right side.

On examination the shoulder appears normal. There is moderate subacromial tenderness, a positive painful arc at 90°, normal range of motion and abduction strength, and a positive Hawkins impingement sign. You diagnose rotator cuff impingement syndrome.

You consider performing a subacromial corticosteroid injection. Which one of the following is the most likely result?

- A) More pain relief and functional improvement compared to NSAIDs
- B) More effective pain relief compared to physical therapy
- C) More durable relief if an image-guided intra-articular injection is used
- D) A possibility of temporary pain relief, but no change in the long-term outcome

224. A patient is being discharged from the hospital following an acute non-ST-elevation myocardial infarction. He is currently being treated with aspirin, lisinopril (Prinivil, Zestril), and metoprolol. An echocardiogram performed in the hospital was normal and a lipid panel included a total cholesterol level of 200 mg/dL and a triglyceride level of 225 mg/dL. On examination he has a pulse rate of 68 beats/min and a blood pressure of 130/80 mm Hg.

Which one of the following additional medications has been shown to improve survival in patients like this?

- A) Amlodipine (Norvasc)
- B) Atorvastatin (Lipitor)
- C) Gemfibrozil (Lopid)
- D) Isosorbide mononitrate
- E) Spironolactone (Aldactone)

225. Acne appearing at which one of the following ages should prompt detailed endocrine laboratory testing for possible underlying systemic disease?

- A) 3 weeks
- B) 7 months
- C) 5 years
- D) 9 years
- E) 13 years

226. A 30-year-old white male presents to the emergency department with a 4-day history of fever to 101°F, a sore throat, rhinorrhea, and cough. An examination reveals rhinorrhea and a boggy nasal mucosa, but is otherwise unremarkable. A chest radiograph shows a questionable infiltrate.

Which one of the following would help determine if antibiotic treatment would be appropriate?

- A) A C-reactive protein level
- B) A procalcitonin level
- C) A WBC count with differential
- D) An erythrocyte sedimentation rate
- E) CT of the chest

227. A 5-year-old male is brought to your office after passing an intestinal worm. He lives on a farm with cattle, pigs, and dogs. He has never traveled very far from home. He does not have any respiratory symptoms or diarrhea, but has experienced some abdominal bloating. A picture of the worm taken by his mother is shown below.

Which one of the following is the infecting organism?

- A) *Ascaris lumbricoides* (roundworm)
- B) *Enterobius vermicularis* (pinworm)
- C) *Giardia lamblia*
- D) *Necator americanus* (hookworm)
- E) *Taenia solium* (tapeworm)



Item #227

- 228.** A 55-year-old male veteran sees you for a routine health maintenance visit. He is up to date on recommended immunizations. His father was diagnosed with colon cancer at age 70 and his family history is otherwise negative. The patient underwent a colonoscopy at age 50 and has a copy of his pathology results, which describe a single hyperplastic polyp taken from the rectum.

Which one of the following would be the most appropriate screening for colorectal cancer in this patient?

- A) Annual fecal immunochemical testing (FIT) starting now
- B) Repeat colonoscopy now
- C) Repeat colonoscopy at age 60
- D) Referral to a gastroenterologist for further management

- 229.** Additional workup or referral to an endocrinologist for evaluation of precocious puberty would be indicated in which one of the following patients?

- A) A 7-year-old female with some pubic hair
- B) An 8-year-old female with breast buds
- C) An 8-year-old male with some pubic hair and axillary odor
- D) An 8-year-old male with penile enlargement
- E) A 10-year-old female who has recently begun having menses

- 230.** An obese 37-year-old white female sees you because of fatigue. She is otherwise asymptomatic and has normal vital signs. A complete physical examination is unremarkable with the exception of obesity. A CBC shows no anemia, but her WBC count is $12,500/\text{mm}^3$ (N 4500–11,000). A TSH level and a comprehensive metabolic panel are normal. She does not take any medications and has not had any recent illnesses.

Which one of the following would be most appropriate at this point?

- A) Reassurance that her leukocytosis is likely caused by her obesity and counseling about weight loss
- B) A repeat CBC with differential and a review of the peripheral smear
- C) A blood culture
- D) Flow cytometric testing
- E) Referral to a hematologist for further workup

- 231.** The drug class of choice for the management of breathlessness in end-of-life care is

- A) anticholinergics
- B) antipsychotics
- C) benzodiazepines
- D) corticosteroids
- E) opiates

232. A 34-year-old male presents with low back pain and stiffness that has been slowly worsening over the past 6 months. It is especially bothersome at night and in the morning when he gets out of bed. It improves with physical activity. He has taken ibuprofen, 400 mg several times a day, which provides moderate pain relief but is not working as well as it used to. He does not have any other joint pain, there is no history of trauma, and he is otherwise well. His BMI is 24.8 kg/m². Radiographs of the lumbar spine show mild degenerative changes of the lumbar vertebrae without other abnormalities.

Which one of the following additional tests would most likely lead to a specific diagnosis?

- A) An erythrocyte sedimentation rate
 - B) C-reactive protein
 - C) Antinuclear antibody
 - D) HLA-B27
 - E) Rheumatoid factor
233. An 80-year-old male sees you for the first time. He is asymptomatic except for some fatigue. His pulse rate is 50 beats/min. An EKG shows a prolonged PR interval.

Which one of the following medications in his current regimen is the most likely explanation for these findings?

- A) Donepezil (Aricept)
 - B) Escitalopram (Lexapro)
 - C) Lisinopril (Prinivil, Zestril)
 - D) Memantine (Namenda)
 - E) Zolpidem (Ambien)
234. A 14-year-old female is brought to your office for an annual well child check and sports preparticipation physical examination. She says she does a lot of running during basketball practices and games but has trouble controlling her weight. Most of her family is overweight. She does not have any difficulty participating in sports, and has no symptoms such as chest pain, shortness of breath, or headaches. She has no significant past medical history.

On examination the patient's height is 154 cm (61 in) and she weighs 63 kg (139 lb). Her BMI is 26.4 kg/m², which places her in the 90th percentile for her age. Her blood pressure is 130/85 mm Hg, which places her between the 95th and 99th percentile for her age, height, and sex. Her chart reveals that her blood pressure was at this level at the last two visits. The physical examination is otherwise normal.

In addition to counseling and support for weight loss, which one of the following would be most appropriate at this point?

- A) Informing the patient and her parents that she is prehypertensive and having her return for a blood pressure check in 3 months
- B) Plasma renin and catecholamine levels
- C) An imaging study of the renal arteries
- D) A fasting basic metabolic panel, a lipid profile, and a urinalysis
- E) Antihypertensive drug therapy

235. A 55-year-old male is hospitalized because of altered mental status. His group home caregiver reports a 1-week history of the patient being confused and unable to perform his activities of daily living. He has a history of hypertension, COPD, and bipolar disorder, and his medications include losartan (Cozaar), inhaled tiotropium (Spiriva), and valproic acid (Depakene).

On examination the patient's vital signs are normal and he is oriented to person, but not to time or place. The remainder of the physical examination is within normal limits. Laboratory findings, including liver enzymes and renal function tests, are normal except for an elevated ammonia level. Ultrasonography of the abdomen does not show any liver abnormalities. Lactulose therapy is started.

Which one of the following is the most likely cause of this patient's elevated ammonia level?

- A) Valproic acid
- B) Occult upper gastrointestinal bleeding
- C) Portal vein thrombosis
- D) Gilbert syndrome

236. A 75-year-old male with a history of hypertension, TIA, and atrial fibrillation sees you for follow-up. Ten days ago he was on vacation in another state when he developed chest pain. He went to a local hospital where he was diagnosed with an ST-elevation myocardial infarction (STEMI) and was taken immediately for cardiac catheterization. He had a drug-eluting stent placed in his left anterior descending artery. He brings some discharge paperwork with him, including a medication list, but has not yet seen a local cardiologist. He is concerned that he is taking too many blood thinners. He feels well and does not have any chest pain, shortness of breath, or excessive bleeding or bruising.

Prior to his STEMI the patient was taking lisinopril (Prinivil, Zestril), 10 mg daily; warfarin (Coumadin), 2.5 mg daily; and metoprolol succinate (Toprol-XL), 25 mg daily. Upon discharge he was instructed to continue all of those medications and to add clopidogrel (Plavix), 75 mg daily, and aspirin, 81 mg daily.

The patient's vital signs and physical examination are normal except for an irregularly irregular rhythm on the cardiovascular examination. His INR is 2.5.

Which one of the following would be most appropriate at this time?

- A) Continue the current regimen
- B) Discontinue aspirin
- C) Discontinue clopidogrel
- D) Discontinue warfarin
- E) Decrease warfarin with a goal INR of 1.5–2.0

237. A 38-year-old white female presents with abdominal pain and insists that she be referred for surgical evaluation. She has a history of multiple unexplained physical symptoms that began in her late teenage years. She is vague about past medical evaluations, but a review of her extensive medical record reveals multiple normal blood and imaging tests, several surgical procedures that have failed to alleviate her symptoms, and frequent requests for refills of narcotic analgesics.

This patient's history is most compatible with

- A) illness anxiety disorder
 - B) malingering
 - C) panic disorder
 - D) generalized anxiety disorder
 - E) somatic symptom disorder
238. A 20-year-old college student comes to the urgent care clinic with right knee pain and swelling after injuring her knee in a recreational basketball game. Her feet were planted when another player collided with her, causing her upper torso to rotate. She felt immediate pain in the knee and was unable to complete the game.

Which one of the following is the most accurate and appropriate maneuver to detect an anterior cruciate ligament tear?

- A) The anterior drawer test
- B) The lever sign test
- C) The Lachman test
- D) The McMurray test
- E) The pivot shift test

American Board of Family Medicine

239. A 54-year-old male is concerned about testosterone deficiency. He has erectile dysfunction with impaired erections and decreased libido. He has also noted hair loss on his legs, breast tenderness, and fatigue. He has chronic renal disease and compensated heart failure, and he takes opioids for chronic pain. Five years ago he had a non-ST-elevation myocardial infarction and has done well with medical management.

The patient's mor
initiate testosteron

parate readings and you want to

Estimated gl
Creatinine .
Hematocrit
Prostate-spe

L/min/1.73 m²
ng/dL (N 0.7–1.3)
(N 42–52)
g/dL (N 0.0–4.0)

Which one of the
testosterone in this:

- A) The histor
- B) Benign pr
- C) Chronic renal disease
- D) Compensated heart failure
- E) Polycythemia



cation to starting treatment with

240. A 62-year-old female comes to your office for evaluation of pain in her right thumb and wrist associated with sewing. She does not have any injury, numbness, tingling, or weakness. An examination reveals an otherwise healthy-appearing female with normal vital signs and no deformity or swelling in her wrists or hands. She has tenderness to palpation at the first dorsal compartment over the radial styloid and has pain with active and passive stretching of the thumb tendons over the radial styloid. She is very worried that she will have to stop sewing and asks if there is anything she could try to alleviate her symptoms.

Which one of the following would be most appropriate at this point?

- A) Reassurance that it will likely improve on its own within about a year
- B) A corticosteroid injection into the first extensor compartment
- C) Immobilization in a thumb spica splint and an NSAID for 1–4 weeks
- D) Radiographs of the thumb and wrist
- E) Referral to an orthopedic surgeon

This book contains the answers to each question in the In-Training Examination, as well as a critique that provides a rationale for the correct answer. Bibliographic references are included at the end of each critique to facilitate any further study you may wish to do in a particular area.

Item 1

ANSWER: E

A urine test for *Legionella pneumophila* antigen is the preferred method to confirm Legionnaires' disease. This test is rapid and will only detect *Legionella pneumophila* antigen. A sputum culture is the gold standard for the diagnosis of Legionnaires' disease but it requires 48–72 hours. A chest radiograph does not confirm the diagnosis but may show the extent of disease. Responding to antibiotic treatment does not confirm a specific diagnosis.

Ref: Mercante JW, Winchell JM: Current and emerging Legionella diagnostics for laboratory and outbreak investigations. *Clin Microbiol Rev* 2015;28(1):95-133. 2) National Center for Immunization and Respiratory Diseases: *Legionella* (Legionnaires' disease and Pontiac fever): Diagnosis, treatment, and prevention. Centers for Disease Control and Prevention, 2017.

Item 2

ANSWER: C

Risk factors for developmental dysplasia of the hip in infants include a breech presentation in the third trimester, regardless of whether the delivery was cesarean or vaginal. Other indications to evaluate an infant for this condition include a positive family history, a history of previous clinical instability, parental concern, a history of improper swaddling, and a suspicious or inconclusive physical examination. Twin birth, a large-for-gestational age infant, and prematurity are not considered risk factors.

Ref: Shaw BA, Segal LS: Section on Orthopaedics: Evaluation and referral for developmental dysplasia of the hip in infants. *Pediatrics* 2016;138(6):pii:e20163107. 2) Hauk L: Developmental dysplasia of the hip in infants: A clinical report from the AAP on evaluation and referral. *Am Fam Physician* 2017;96(3):196-197.

Item 3

ANSWER: C

Experts recommend that a refusal to vaccinate form be signed by patients or parents who refuse a recommended vaccine. This form should document that the patient/parents were provided the vaccine information statement (SOR C). The CDC recommends against dismissing a patient or family from a practice if they refuse vaccination. Physicians should continue to discuss the benefits of immunizations at subsequent visits, because some patients/parents may reconsider their decision not to vaccinate.

Ref: Spencer JP, Trondsen Pawlowski RH, Thomas S: Vaccine adverse events: Separating myth from reality. *Am Fam Physician* 2017;95(12):786-794.

Item 4**ANSWER: A**

Prepatellar bursitis is a common superficial bursitis caused by microtrauma from repeated kneeling and crawling. Other terms for this include housemaid's knee, coal miner's knee, and carpet layer's knee. It is usually associated with minimal to no pain. This differs from inflammatory processes such as acute gouty superficial bursitis, which presents as an acutely swollen, red, inflamed bursa and, in rare cases, progresses to chronic tophaceous gout with minimal or no pain.

The proper management of prepatellar bursitis is conservative and includes ice, compression wraps, padding, elevation, analgesics, and modification of activity. There is little evidence that a corticosteroid injection is beneficial, even though it is often done. If inflammatory bursitis is suspected, a corticosteroid injection may be helpful. Fluid aspiration is indicated if septic bursitis is suspected. Surgery can be considered for significant enlargement of a bursa if it interferes with function.

Ref: Khodae M: Common superficial bursitis. *Am Fam Physician* 2017;95(4):224-231.

Item 5**ANSWER: E**

A history of an ischemic stroke within the past 3 months is an absolute contraindication to fibrinolytic therapy in patients with an ST-elevation myocardial infarction (STEMI), unless the stroke is diagnosed within 4½ hours. Poorly controlled hypertension, dementia, peptic ulcer disease, and major surgery less than 3 weeks before the STEMI are relative contraindications that should be considered on an individual basis.

Ref: O'Gara PT, Kushner FG, Ascheim DD, et al: 2013 ACCF/AHA guideline for the management of ST-elevation myocardial infarction: A report of the American College of Cardiology Foundation/American Heart Association Task Force on Practice Guidelines. *Circulation* 2013;127(4):e362-e425.

Item 6**ANSWER: E**

This patient has sudden sensorineural hearing loss (SSNHL) of the left ear without any accompanying features to suggest a clear underlying cause. An appropriate evaluation will fail to identify a cause in 85%–90% of cases. Idiopathic SSNHL can be diagnosed if a patient is found to have a 30-dB hearing loss at three consecutive frequencies and an underlying condition is not identified by the history and physical examination.

The most recent guideline from the American Academy of Otolaryngology–Head and Neck Surgery recommends that oral corticosteroids be considered as first-line therapy for patients who do not have a contraindication. While there is equivocal evidence of benefit, for most patients the risk of a short-term course of corticosteroids is thought to be outweighed by the potential benefit, especially when considering the serious consequences of long-term profound hearing loss. Because the greatest improvement in hearing tends to occur in the first 2 weeks, corticosteroid treatment should be started immediately. The recommended dosage is 1 mg/kg/day with a maximum dosage of 60 mg daily for 10–14 days.

Antiviral medications, antiplatelet agents, and vasodilators such as nifedipine have no evidence of benefit. Antibiotics also have no evidence of benefit in the absence of signs of infection.

Ref: Stachler RJ, Chandrasekhar SS, Archer SM, et al: Clinical practice guideline: Sudden hearing loss. *Otolaryngol Head Neck Surg* 2012;146(3 Suppl):S1-S35.

Item 7

ANSWER: D

The Ottawa foot and ankle rules should be used to determine the need for radiographs in foot and ankle injuries. A radiograph of the ankle is recommended if there is pain in the malleolar zone along with the inability to bear weight for at least four steps immediately after the injury and in the physician's office or emergency department (ED), or tenderness at the tip of the posterior medial or lateral malleolus. A radiograph of the foot is recommended if there is pain in the midfoot zone along with the inability to bear weight for four steps immediately after the injury and in the physician's office or ED, or tenderness at the base of the fifth metatarsal or over the navicular bone. The Ottawa foot and ankle rules are up to 99% sensitive for detecting fractures, although they are not highly specific. In this case there are no findings that would require radiographs, so treatment for the ankle sprain would be recommended. Compression combined with lace-up ankle support or an air cast, along with cryotherapy, is recommended and can increase mobility. Early mobilization, including weight bearing as tolerated for daily activities, is associated with better long-term outcomes than prolonged rest.

Ref: Tiemstra JD: Update on acute ankle sprains. *Am Fam Physician* 2012;85(12):1170-1176. 2) Bica D, Sprouse RA, Armen J: Diagnosis and management of common foot fractures. *Am Fam Physician* 2016;93(3):183-191.

Item 8

ANSWER: A

Alcohol consumption greater than one drink/day has been associated with atrial fibrillation. While not recommended to prevent atrial fibrillation, pioglitazone and lisinopril have both been associated with lower rates of atrial fibrillation compared to alternative therapies. Treatment of obstructive sleep apnea, along with a regular fitness regimen, has been associated with a decrease in the recurrence of atrial fibrillation.

Ref: Morin DP, Bernard ML, Madias C, et al: The state of the art: Atrial fibrillation epidemiology, prevention, and treatment. *Mayo Clin Proc* 2016;91(12):1778-1810.

Item 9**ANSWER: A**

The reticulocyte count is the first and best indicator of iron absorption and bone marrow response to oral iron therapy in the treatment of iron deficiency anemia. An increase in reticulocytes is seen as early as 4 days, peaking at 7–10 days. The rate of production of new RBCs slows thereafter due to a compensatory decrease in erythropoietin as more iron becomes available. It typically takes 4–6 weeks before seeing recovery in the hematocrit, and for the RBC count and indices to normalize. However it is usually 4–6 months before iron stores are fully restored to normal levels, so treatment should continue for at least that long.

Ref: Killip S, Bennett JM, Chambers MD: Iron deficiency anemia. *Am Fam Physician* 2007;75(5):671-678. 2) Kasper DL, Fauci AS, Hauser SL, et al (eds): *Harrison's Principles of Internal Medicine*, ed 19. McGraw-Hill, 2015, pp 628-629.

Item 10**ANSWER: C**

First- and second-generation H₁ antihistamine receptor antagonists are generally considered first-line treatment for chronic urticaria, and approximately 60% of patients experience a satisfactory result. Second-generation options such as loratadine have the added benefit of a lower likelihood of side effects such as drowsiness. For those who fail to achieve the desired result with monotherapy using an H₁ antihistamine receptor antagonist, the addition of an H₂ antihistamine receptor antagonist such as cimetidine or ranitidine is often beneficial. The tricyclic antidepressant doxepin has strong H₁ and H₂ antihistamine receptor antagonist effects and has been used as an off-label treatment option in some studies. A short course of oral corticosteroids, narrow-band UV light treatment, or cyclosporine can be used in the management of recalcitrant chronic urticaria, but these are considered second- or third-line adjunctive options.

Ref: Perera E, Sinclair R: Evaluation, diagnosis and management of chronic urticaria. *Aust Fam Physician* 2014;43(9):621-625.

Item 11**ANSWER: D**

This patient's close contact with a person known to be infected with tuberculosis (TB) places him at risk for infection, so screening for TB is indicated. For this patient, testing with either a tuberculin skin test or an interferon-gamma release assay is appropriate. Based on CDC guidelines an induration ≥ 5 mm at 48–72 hours following an intradermal injection of tuberculin is a positive test in individuals who have been in recent contact with a person with infectious TB, those with radiographic evidence of prior TB, HIV-infected persons, and immunosuppressed patients. For other individuals at increased risk for TB, the threshold for a positive test is an induration ≥ 10 mm at 48–72 hours. For those with no known risks for TB infection, the induration must exceed 15 mm in size to be considered positive. Once positive, there is no indication for additional skin tests.

A positive screening test along with a review of systems, a physical examination, and a chest radiograph that do not show evidence of active infection confirms the diagnosis of latent TB. For children age 2–11 years, treatment with isoniazid, 10–20 mg/kg daily or 20–40 mg/kg twice weekly for 9 months, is the preferred and most efficacious treatment regimen. The shorter 6-month treatment course is considered an acceptable option for adults, but it is not recommended for children. The use of rifampin alone or in combination with isoniazid is also an acceptable option for adults but not for children under the age of 12.

Ref: National Center for HIV/AIDS, Viral Hepatitis, STD, and TB Prevention: *Latent Tuberculosis Infection: A Guide for Primary Health Care Providers*. Centers for Disease Control and Prevention, 2013. 2) Lewinsohn DM, Leonard MK, LoBue PA, et al: Official American Thoracic Society/Infectious Diseases Society of America/Centers for Disease Control and Prevention clinical practice guidelines: Diagnosis of tuberculosis in adults and children. *Clin Infect Dis* 2017;64(2):111-115.

Item 12

ANSWER: B

Evaluation of this patient should include CT of the abdomen and pelvis with oral and intravenous (IV) contrast. There is no reason to inquire about shellfish allergies prior to CT with IV contrast, because premedication is not needed. There is no correlation between shellfish allergies and allergic reactions to contrast. Patients with moderately severe to severe reactions to IV contrast in the past would need pretreatment with corticosteroids.

Ref: Narayan AK, Durand DJ, Feldman LS: Avoiding contrast-enhanced computed tomography scans in patients with shellfish allergies. *J Hosp Med* 2016;11(6):435-437.

Item 13

ANSWER: C

This patient's pain and weakness while pushing against resistance reveals weakness on internal rotation of the shoulder, which suggests a possible tear of the subscapularis tendon. The inability to keep her hand away from her body when it is placed behind her back describes a positive internal lag test, also suggesting involvement of the subscapularis tendon. The infraspinatus and teres minor are involved in external rotation rather than internal rotation. The supraspinatus and deltoid are involved in abduction of the shoulder.

Ref: Woodward TW, Best TM: The painful shoulder: Part I. Clinical evaluation. *Am Fam Physician* 2000;61(10):3079-3088. 2) Verry C, Fernando S: Rotator cuff disease: Diagnostic tests. *Am Fam Physician* 2016;94(11):925-926.

Item 14

ANSWER: B

Ultrasonography is recommended as the first imaging modality to evaluate acute abdominal pain in children. It avoids radiation exposure and is useful for detecting many causes of abdominal pain, including appendicitis. After ultrasonography, CT or MRI can be used if necessary to diagnose appendicitis. Abdominal radiography is helpful in patients with constipation, possible bowel obstruction, or a history of previous abdominal surgery.

The American Academy of Pediatrics Choosing Wisely recommendation on the evaluation of abdominal pain states that CT is not always necessary. The American College of Surgeons Choosing Wisely recommendation on the evaluation of suspected appendicitis in children says that CT should be avoided until after ultrasonography has been considered as an option.

Ref: American Academy of Pediatrics: Computed tomography (CT) scans are not necessary in the routine evaluation of abdominal pain. ABIM Foundation Choosing Wisely campaign, 2013. 2) Reust CE, Williams A: Acute abdominal pain in children. *Am Fam Physician* 2016;93(10):830-836. 3) ACR appropriateness criteria. American College of Radiology, 2018.

Item 15

ANSWER: B

The syndrome of inappropriate antidiuresis (SIAD, formerly SIADH) is related to a variety of pulmonary and central nervous system disorders in which hyponatremia and hypo-osmolality are paradoxically associated with an inappropriately concentrated urine. Most cases are associated with increased levels of the antidiuretic hormone arginine vasopressin (AVP). Making a diagnosis of SIAD requires that the patient be euvoletic and has not taken diuretics within the past 24–48 hours, and the urine osmolality must be high in conjunction with both low serum sodium and low osmolality. The BUN should be normal or low and the fractional excretion of sodium $> 1\%$.

Fluid restriction (< 800 cc/24 hrs) over several days will correct the hyponatremia/hypo-osmolality, but definitive treatment requires eliminating the underlying cause, if possible. In the case of severe, acute hyponatremia with symptoms such as confusion, obtundation, or seizures, hypertonic (3%) saline can be slowly infused intravenously but might have dangerous neurologic side effects.

Elevated serum glucose levels may cause a factitious hyponatremia, but not SIAD.

Ref: Ellison DH, Berl T: The syndrome of inappropriate antidiuresis. *N Engl J Med* 2007;356(2):2064-2072. 2) Verbalis JG, Goldsmith SR, Greenberg A, et al: Diagnosis, evaluation, and treatment of hyponatremia: Expert panel recommendations. *Am J Med* 2013;126(10 Suppl 1):S1-S42.

Item 16**ANSWER: A**

Lifestyle modifications addressing diet, physical activity, and weight are important in the treatment of hypertension, particularly for African-American and Hispanic patients. When antihypertensive drugs are also required, the best options may vary according to the racial and ethnic background of the patient. The presence or absence of comorbid conditions is also important to consider. For African-Americans, thiazide diuretics and calcium channel blockers, both as monotherapy and as a component in multidrug regimens, have been shown to be more effective in lowering blood pressure than ACE inhibitors, angiotensin II receptor blockers, or β -blockers, and should be considered as first-line options over the other classes of antihypertensive drugs unless a comorbid condition is present that would be better addressed with a different class of drugs. Racial or ethnic background should not be the basis for the exclusion of any drug class when multidrug regimens are required to reach treatment goals.

Ref: James PA, Oparil S, Carter BL, et al: 2014 evidence-based guideline for the management of high blood pressure in adults: Report from the panel members appointed to the Eighth Joint National Committee (JNC 8). *JAMA* 2014;311(5):507-520.
2) Whelton PK, Carey RM, Aronow WS, et al: 2017 ACC/AHA/AAPA/ABC/ACPM/AGS/APhA/ASH/ASPC/NMA/PCNA guideline for the prevention, detection, evaluation, and management of high blood pressure in adults: A report of the American College of Cardiology/American Heart Association Task Force on clinical practice guidelines. *J Am Coll Cardiol* 2017;pii:S0735-1097(17)41519-1.

Item 17**ANSWER: D**

Eligibility for hospice care is based on a life expectancy of 6 months or less in the natural course of an illness. A majority of hospice patients have cancer but it is not a requirement to qualify for hospice care. Age is not relevant. Comorbid conditions may affect longevity but are not required. For those insured by Medicare, Medicare Part A provides hospice care but Medicare Part B does not.

Ref: *Medicare Hospice Benefits*. Centers for Medicare & Medicaid Services, 2018, p 7.

Item 18**ANSWER: A**

The U.S. Preventive Services Task Force recommends depression screening for all adolescents 12–18 years of age. Although this patient has abdominal pain, the history and physical examination suggest that depression may be playing a role in her somatic complaints. She had a positive initial depression screen on her PHQ-2. This is a brief screening tool, and a positive result merits further evaluation. The evaluation should include a full PHQ-A or a discussion with a qualified clinician. If the patient meets the criteria for major depressive disorder then she should receive treatment for her depression, which could include medication. Both fluoxetine and citalopram have been approved by the FDA to treat depression in this age group. She could also be referred for psychotherapy. Further laboratory studies and imaging may be appropriate at some point, but the most urgent need is to evaluate her positive depression screen.

Ref: Richardson LP, Rockhill C, Russo JE, et al: Evaluation of the PHQ-2 as a brief screen for detecting major depression among adolescents. *Pediatrics* 2010;125(5):e1097-e1103. 2) *Final Recommendation Statement: Depression in Children and Adolescents: Screening*. US Preventive Services Task Force, 2016.

Item 19

ANSWER: C

Liraglutide, exenatide, and dulaglutide are all GLP-1 receptor agonists. Of these, only liraglutide has been shown to lower the risk of recurrent cardiovascular events and has received FDA approval for this indication. Glipizide (a sulfonylurea), rosiglitazone, and sitagliptin have not been associated with improved cardiovascular outcomes. Empagliflozin, an SGLT2 inhibitor, has also been associated with secondary prevention of cardiovascular disease.

Ref: Marso SP, Daniels GH, Brown-Frandsen K, et al: Liraglutide and cardiovascular outcomes in type 2 diabetes. *N Engl J Med* 2016;375(4):311-322. 2) Sattar N, Petrie MC, Zinman B, Januzzi JL Jr: Novel diabetes drugs and the cardiovascular specialist. *J Am Coll Cardiol* 2017;69(21):2646-2656.

Item 20

ANSWER: E

Individuals with sickle cell disease are at increased risk for vascular disease, especially stroke. All sickle cell patients 2–16 years of age should be screened with transcranial Doppler ultrasonography (SOR A). A chest radiograph, abdominal ultrasonography, a DXA scan, and renal Doppler ultrasonography are not recommended for screening patients with sickle cell disease.

Ref: Yawn BP, John-Sowah J: Management of sickle cell disease: Recommendations from the 2014 Expert Panel report. *Am Fam Physician* 2015;92(12):1069-1076.

Item 21

ANSWER: A

In addition to clinodactyly, fetal alcohol syndrome is associated with camptodactyly (flexion deformity of the fingers), other flexion contractures, radioulnar synostosis, scoliosis, and spinal malformations. It is also associated with many neurologic, behavioral, and cardiovascular abnormalities, as well as other types of abnormalities. Plagiocephaly, supernumerary digits, syndactyly, and metatarsus adductus are common in newborns but are not related to fetal alcohol spectrum disorders.

Ref: Denny L, Coles S, Blitz R: Fetal alcohol syndrome and fetal alcohol spectrum disorders. *Am Fam Physician* 2017;96(8):515-522.

Item 22**ANSWER: A**

This child has otitis media with effusion, and the recommended course of action is to follow up in 3 months. Medications, including decongestants, antihistamines, antibiotics, and corticosteroids, are not recommended.

Ref: Lambert M: AAO-HNS releases updated guideline on management of otitis media with effusion. *Am Fam Physician* 2016;94(9):747-749.

Item 23**ANSWER: D**

This patient has acute to subacute nonspecific low back pain. Combination treatment with an NSAID and a skeletal muscle relaxant is recommended as second-line therapy when an NSAID is ineffective as monotherapy. Opioids have not been shown to have significant benefit when added to an NSAID and would not be recommended as a second-line treatment. Systemic corticosteroids do not have evidence to support their use in the treatment of acute nonspecific back pain. Gabapentin does not have evidence to support its use in treating acute back pain and has been shown to produce only minimal improvement in chronic back pain. This patient has no red-flag symptoms so imaging studies are not recommended at this time.

Ref: Qaseem A, Wilt TJ, McLean RM, et al: Noninvasive treatments for acute, subacute, and chronic low back pain: A clinical practice guideline from the American College of Physicians. *Ann Intern Med* 2017;166(7):514-530.

Item 24**ANSWER: E**

This patient has polyneuropathy, macrocytic anemia, and a history of chronic proton pump inhibitor use. The most likely cause is vitamin B₁₂ deficiency and a serum level is indicated. Her hemoglobin A_{1c} is 5.8%, which puts her at risk of developing diabetes mellitus but is not indicative of diabetes. Charcot-Marie-Tooth disease is a rare cause of polyneuropathy and unlikely in this case. Hypothyroidism, and not hyperthyroidism, is associated with polyneuropathy. Tarsal tunnel syndrome causes a mononeuropathy.

Ref: Langan RC, Goodbred AJ: Vitamin B₁₂ deficiency: Recognition and management. *Am Fam Physician* 2017;96(6):384-389.

Item 25**ANSWER: C**

Family physicians should be aware of the environmental exposures associated with pulmonary disease. Stone cutting, sand blasting, mining, and quarrying expose patients to silica, which is an inorganic dust that causes pulmonary fibrosis (silicosis). Occupational exposure to beryllium, which is also an inorganic dust, occurs in the high-tech electronics manufacturing industry and results in chronic beryllium lung disease. Exposure to organic agricultural dusts (fungal spores, vegetable products, insect fragments, animal dander, animal feces, microorganisms, and pollens) can result in “farmer’s lung,” a hypersensitivity pneumonitis. Other organic dust exposures, such as exposures to grain dust in bakers, can lead to asthma, chronic bronchitis, and COPD. Firefighters are at risk of smoke inhalation and are exposed to toxic chemicals that can cause many acute and chronic respiratory symptoms.

Ref: Kasper DL, Fauci AS, Hauser SL, et al (eds): *Harrison’s Principles of Internal Medicine*, ed 19. McGraw-Hill, 2015, pp 1687-1694, 1708-1716.

Item 26**ANSWER: A**

A plasma ACTH level is recommended to establish primary adrenal insufficiency. The sample can be obtained at the same time as the baseline sample in the corticotropin test. A plasma ACTH greater than twice the upper limit of the reference range is consistent with primary adrenal insufficiency. Aldosterone and renin levels should be obtained to establish the presence of adrenocortical insufficiency, but these do not differentiate primary from secondary adrenal insufficiency. The hyperpigmentation of Addison’s disease is caused by the melanocyte-stimulating hormone (MSH)–like effect of the elevated plasma levels of ACTH. ACTH shares some amino acids with MSH and also produces an increase in MSH in the blood. TSH is not part of the feedback loop of adrenal insufficiency.

Ref: Bornstein SR, Allolio B, Arlt W, et al: Diagnosis and treatment of primary adrenal insufficiency: An Endocrine Society clinical practice guideline. *J Clin Endocrinol Metab* 2016;101(2):364-389.

Item 27**ANSWER: B**

Family physicians often see patients with diarrheal illnesses and most of these are viral. Patients sometimes have misconceptions about preferred fluid and feeding recommendations during these illnesses. The World Health Organization recommends oral rehydration with low osmolarity drinks (oral rehydration solution) and early refeeding. Half-strength apple juice has been shown to be effective, and it approximates an oral rehydration solution. Its use prevents patient measurement errors and the purchase of beverages with an inappropriate osmolarity. Low osmolarity solutions contain glucose and water, which decrease stool frequency, emesis, and the need for intravenous fluids compared to higher osmolarity solutions like soda and most sports drinks. Water increases the risk of hyponatremia in children. This patient is not ill enough to need intravenous fluids. Early refeeding has been shown to decrease the duration of illness.

Ref: The treatment of diarrhoea: A manual for physicians and other senior health workers. World Health Organization, 2005.
2) Barr W, Smith A: Acute diarrhea. *Am Fam Physician* 2014;89(3):180-189. 3) Chang JG: Oral rehydration solutions for the treatment of acute watery diarrhea. *Am Fam Physician* 2017;96(11):700-701.

Item 28

ANSWER: E

Hypertrophic cardiomyopathy is the most common primary cardiomyopathy, with a prevalence of 1:500 persons. Many patients with hypertrophic cardiomyopathy are asymptomatic and are diagnosed during family screening, by auscultation of a heart murmur, or incidentally after an abnormal result on electrocardiography. On examination physicians may hear a systolic murmur that increases in intensity during Valsalva maneuvers. The main goals of therapy are to decrease exertional dyspnea and chest pain and prevent sudden cardiac death. β -Blockers are the initial therapy for patients with symptomatic hypertrophic cardiomyopathy. Nondihydropyridine calcium channel blockers such as verapamil can be used if β -blockers are not well tolerated.

Ref: Brieler J, Breeden MA, Tucker J: Cardiomyopathy: An overview. *Am Fam Physician* 2017;96(10):640-646.

Item 29

ANSWER: B

Nonpharmacologic interventions are the first-line treatment for patients with behavioral and psychological symptoms of dementia. Antipsychotic medications can be prescribed for refractory cases but this is an off-label use. Both the patient and family should be aware that the use of atypical antipsychotics for behavioral symptoms of dementia is associated with increased mortality. Patients should be monitored for side effects and the medication should be discontinued if there is no evidence of symptom improvement after a month.

Typical antipsychotics such as haloperidol have significant side effects and would not be a good choice. Donepezil is initiated early in the course of Alzheimer's disease to delay progression of the disease. Benzodiazepines are likely to cause significant side effects including sedation, increased confusion, and falls. Several of the antipsychotics, such as ziprasidone and clozapine, are ineffective. Results with olanzapine, quetiapine, and risperidone are inconsistent. Aripiprazole produces small reductions in behavioral and psychological symptoms of dementia, and it has the least adverse effects of the atypical antipsychotics.

Ref: Reese TR, Thiel DJ, Cocker KE: Behavioral disorders in dementia: Appropriate nondrug interventions and antipsychotic use. *Am Fam Physician* 2016;94(4):276-282.

Item 30**ANSWER: B**

Few treatments for dysfunctional uterine bleeding have been studied. NSAIDs, oral contraceptive pills, and danazol have not been shown to have sufficient evidence of effect for the treatment of dysfunctional uterine bleeding. Progestin is effective when used on a 21-day cycle, but not if used only during the luteal phase. Hysterectomy and ablation are very effective, but both eliminate fertility. In a young woman unsure about having children, the levonorgestrel-releasing IUD is the most effective treatment that preserves fertility (SOR A).

Ref: Sweet MG, Schmidt-Dalton TA, Weiss PM, Madsen KP: Evaluation and management of abnormal uterine bleeding in premenopausal women. *Am Fam Physician* 2012;85(1):35-43. 2) Kellerman RD, Bope ET (eds): *Conn's Current Therapy 2018*. Elsevier Saunders, 2018, pp 1073-1074.

Item 31**ANSWER: D**

Quadriceps-strengthening exercises have been shown in good studies to stabilize the knee and reduce pain for patients with degenerative arthritis. Acetaminophen has not been shown to produce clinically significant improvement from baseline pain. Intra-articular corticosteroids can acutely relieve pain and effusions but do not affect moderate-term outcomes. Hyaluronate products are minimally effective. Opiates and other similar drugs are addictive and should be avoided.

Ref: Cohen D: Exercise for osteoarthritis of the knee. *Am Fam Physician* 2015;92(9):774-776. 2) Bannuru RR, Schmid CH, Kent DM, et al: Comparative effectiveness of pharmacologic interventions for knee osteoarthritis: A systematic review and network meta-analysis. *Ann Intern Med* 2015;162(1):46-54.

Item 32**ANSWER: D**

Patients <75 years of age with established coronary artery disease should be on high-intensity statin regimens if tolerated. These regimens include atorvastatin, 40–80 mg/day, and rosuvastatin, 20–40 mg/day. Moderate-intensity regimens include simvastatin, 40 mg/day. Monotherapy with non-statin medications (bile acid sequestrants, niacin, ezetimibe, and fibrates) does not reduce cardiovascular morbidity or mortality. The PCSK9 inhibitors evolocumab and alirocumab are second-line or add-on therapies at this time.

Ref: Braun MM, Stevens WA, Barstow CH: Stable coronary artery disease: Treatment. *Am Fam Physician* 2018;97(6):376-384.

Item 33**ANSWER: B**

This patient has subclinical hyperthyroidism as evidenced by her low TSH level with normal free T₄ and free T₃ levels. Common causes of subclinical hyperthyroidism include Graves disease, autonomous functioning thyroid adenoma, and multinodular toxic goiter. Subclinical hyperthyroidism may progress to overt hyperthyroidism; this is more likely in patients with TSH levels <0.1 µU/mL. Even in the absence of overt hyperthyroidism these patients are at higher risk for several health conditions, including atrial fibrillation, heart failure, and osteoporosis. For this reason it is important to assess for these conditions and consider treating the underlying thyroid condition, as well as the complication. The American Thyroid Association recommends treating patients with complications who are either over age 65 or have a TSH level <0.1 µU/mL.

Lipid and glucose abnormalities are not known to be related to subclinical hyperthyroidism. Calcium levels may be abnormal in hyperparathyroidism but not hyperthyroidism. Thyroid ultrasonography may be helpful to determine the cause of hyperthyroidism but is not used to help decide when to treat subclinical hyperthyroidism.

Ref: Donangelo I, Suh SY: Subclinical hyperthyroidism: When to consider treatment. *Am Fam Physician* 2017;95(11):710-716.

Item 34**ANSWER: A**

Benign paroxysmal positional vertigo (BPPV) originates in the posterior semicircular canal in the majority of patients (85%–95% range reported). The Dix-Hallpike maneuver, which involves moving the patient from an upright to a supine position with the head turned 45° to one side and the neck extended 20° with the affected ear down, will elicit a specific series of responses in these patients. Following a latency period that typically lasts 5–20 seconds but sometimes as long as 60 seconds, the patient will experience the onset of rotational vertigo. The objective finding of a torsional, upbeating nystagmus will be associated with the vertigo. The vertigo and nystagmus typically increase in intensity and then resolve within 1 minute from onset.

Ref: Bhattacharyya N, Gubbels SP, Schwartz SR, et al: Clinical practice guideline: Benign paroxysmal positional vertigo (update). *Otolaryngol Head Neck Surg* 2017;156(3 Suppl):S1–S47.

Item 35**ANSWER: B**

Escitalopram is a preferred antidepressant for older patients (SOR C). Paroxetine should generally be avoided in older patients due to a higher likelihood of adverse effects (SOR C). Amitriptyline, imipramine, and paroxetine are highly anticholinergic and sedating, and according to the Beers Criteria, they can cause orthostatic hypotension. They have an “avoid” recommendation (SOR A).

Ref: Kovich H, DeJong A: Common questions about the pharmacologic management of depression in adults. *Am Fam Physician* 2015;92(2):94-100. 2) CCSMH national guidelines for seniors' mental health. Canadian Coalition for Seniors' Mental Health. 3) By the American Geriatrics Society 2015 Beers Criteria Update Expert Panel: American Geriatrics Society 2015 updated Beers Criteria for potentially inappropriate medication use in older adults. *J Am Geriatr Soc* 2015;63(11):2227-2246.

Item 36

ANSWER: A

All patients with a smoking history and symptoms of COPD such as a chronic cough with sputum production and/or chronic and progressive dyspnea should be screened for COPD with spirometry. However, asymptomatic individuals such as this patient should not be screened with spirometry regardless of risk factors. Neither chest radiography nor chest CT has a role in screening for COPD. Screening for α_1 -antitrypsin deficiency in the absence of a family history is not recommended.

Ref: *Final Recommendation Statement: Chronic Obstructive Pulmonary Disease: Screening*. US Preventive Services Task Force, 2016. 2) Press VG, Cifu AS, White SR: Screening for chronic obstructive pulmonary disease. *JAMA* 2017;318(17):1702-1703.

Item 37

ANSWER: C

St. John's wort can reduce the effectiveness of multiple medications because it is an inducer of CYP3A4 and P-glycoprotein synthesis. Concurrent use of St. John's wort with drugs that are metabolized with these systems should be avoided. These include cyclosporine, warfarin, theophylline, and oral contraceptives. St. John's wort should be avoided in patients taking either over-the-counter or prescription medications.

Ref: Asher GN, Corbett AH, Hawke RL: Common herbal dietary supplement—Drug interactions. *Am Fam Physician* 2017;96(2):101-107.

Item 38

ANSWER: C

Social anxiety disorder can be treated with psychotherapy, pharmacotherapy, or both. Several medications have been used for the treatment of social anxiety disorder. SSRIs are considered to be the first-line pharmacologic treatment. Response rates reported for the SNRI venlafaxine have been similar to those reported for SSRIs. Randomized trials have also supported the efficacy of benzodiazepines for social anxiety disorder, but they carry a risk of physiologic dependence and withdrawal symptoms and are not recommended for patients with coexisting depression or a history of substance abuse. Response rates to pregabalin have been lower than with SSRIs. Tricyclic antidepressants and bupropion are not considered to be useful in the treatment of social anxiety disorder.

Ref: Leichsenring F, Leweke F: Social anxiety disorder. *N Engl J Med* 2017;376(23):2255-2264.

Item 39**ANSWER: B**

Fractures involving the distal end of the radius are the most common upper extremity fractures and are most common in elderly women. The mechanism of injury is usually from falling on an outstretched hand (FOOSH). Prompt surgical intervention is recommended in patients with neurovascular compromise, open fractures, or evidence of compartment syndrome. In general, circumferential casts should be avoided, as the underlying swelling can compromise distal circulation. The splint of choice in patients with these fractures is a sugar tong splint. Radial gutter splints are indicated for uncomplicated fractures of the second and third metacarpals. Thumb spica splints are often used in patients with suspected scaphoid fractures (SOR B).

Ref: Eiff MP, Hatch R: *Fracture Management for Primary Care*, ed 3. Elsevier Saunders, 2018, p 367.

Item 40**ANSWER: C**

Pediatric asthma is the most commonly encountered chronic illness, occurring in nearly one out of seven individuals. Short-acting β -agonists in the form of metered-dose inhalers are clearly favored for acute exacerbations, as well as for intermittent asthma. Treatment for persistent asthma requires the use of inhaled corticosteroids, with short-acting β -agonists used for exacerbations. For patients not well controlled with those options, either a long-acting β -agonist or a leukotriene receptor antagonist may be added. While both cromolyn and nedocromil are fairly devoid of adverse effects, their use is limited because of a lack of efficacy in the prevention of acute asthma exacerbations.

Ref: Dunn NA, Neff LA, Maurer DM: A stepwise approach to pediatric asthma. *J Fam Pract* 2017;66(5):280-286. 2) Global strategy for asthma management and prevention. Global Initiative for Asthma, 2018.

Item 41**ANSWER: A**

Palpitations are a common symptom in ambulatory care. Cardiac causes are the most worrisome so it is important to distinguish cardiac from noncardiac causes. Patients with a history of cardiovascular disease, palpitations that affect their sleep, or palpitations that occur at work have an increased risk of an underlying cardiac cause (positive likelihood ratio 2.0–2.3) (SOR C). Psychiatric illness, adverse effects of medications, and substance abuse are other common causes.

Palpitations that are worse in public places and those of very short duration (<5 minutes), especially if there is a history of anxiety, are often related to panic disorder. However, even a known behavioral issue should not be presumed to be the cause of palpitations, as nonpsychiatric causes are found in up to 13% of such cases. The use of illicit substances such as cocaine and methamphetamine can cause palpitations that are associated with dry mouth, pupillary dilation, sweating, and aberrant behavior. Excessive caffeine can also cause palpitations.

Ref: Wexler RK, Pleister A, Raman SV: Palpitations: Evaluation in the primary care setting. *Am Fam Physician* 2017;96(12):784-789.

Item 42**ANSWER: B**

A Wood's lamp may assist with the diagnosis of certain skin conditions. This patient's presentation is consistent with erythrasma caused by a *Corynebacterium minutissimum* infection, and use of an ultraviolet light would reveal a coral pink color. Pale blue fluorescence occurs with *Pseudomonas* infections, yellow with tinea infections, and totally white with vitiligo. A lime green fluorescence is not characteristic of a particular skin condition.

Ref: Kasper DL, Fauci AS, Hauser SL, et al (eds): *Harrison's Principles of Internal Medicine*, ed 19. McGraw-Hill, 2015, pp 339-344. 2) Habib TP: *Clinical Dermatology: A Color Guide to Diagnosis and Therapy*, ed 6. Elsevier, 2016.

Item 43**ANSWER: E**

Annual HPV screening in patients age 21–29 years has very little effect on cancer prevention and leads to an increase in procedures and treatments without significant benefit. In this age group there is a high prevalence of high-risk HPV infections but a low incidence of cervical cancer. If this patient were due for a Papanicolaou (Pap) test and results were ASC-US with a positive high-risk HPV or a higher grade abnormality, colposcopy would be recommended. Current recommendations are for a Pap test with cytology every 3 years for women age 21–29 years with normal results, and the frequency does not change with an increased number of normal screens. HPV is the most common sexually transmitted infection (STI) and up to 79% of sexually active women contract HPV infection in their lifetime, so the lack of other STIs does not preclude the possibility of an HPV infection.

Ref: Juckett G, Hartman-Adams H: Human papillomavirus: Clinical manifestations and prevention. *Am Fam Physician* 2010;82(10):1209-1213. 2) Massad LS, Einstein MH, Huh WK, et al: 2012 updated consensus guidelines for the management of abnormal cervical cancer screening tests and cancer precursors. *Obstet Gynecol* 2013;121(4):829-846. 3) ACOG releases guideline on cervical cancer screening. *Am Fam Physician* 2013;88(11):776-777.

Item 44**ANSWER: A**

The first step in the management of severe hypertension is determining whether a hypertensive emergency is present. A thorough history and physical examination are crucial (SOR C). Severe hypertension (blood pressure >180 mm Hg systolic or >110 mm Hg diastolic) with end-organ damage constitutes a hypertensive emergency. A physical examination should center on evaluating for papilledema, neurologic deficits, respiratory compromise, and chest pain. If end-organ damage is present the patient should be hospitalized for monitored blood pressure reduction and further diagnostic workup. If end-organ damage is not present and the physical examination is otherwise normal, a 30-minute rest with reevaluation is indicated. Approximately 30% of patients will improve to an acceptable blood pressure without treatment (SOR C). Home medications should then be adjusted with outpatient follow-up and home blood pressure monitoring (SOR A). Short-acting antihypertensives are indicated if mild symptoms are noted such as headache, lightheadedness, nausea, shortness of breath, palpitations, anxiety, or epistaxis. Diagnostic testing is not immediately indicated for asymptomatic patients (SOR C). A basic metabolic panel or other testing should be considered if mild symptoms are present. Aggressive lowering of blood pressure can be detrimental and a gradual reduction over days to weeks is preferred (SOR C).

Ref: Oza R, Garcellano M: Nonpharmacologic management of hypertension: What works? *Am Fam Physician* 2015;91(11):772-776. 2) Gauer R: Severe asymptomatic hypertension: Evaluation and treatment. *Am Fam Physician* 2017;95(8):492-500.

Item 45

ANSWER: B

This patient presents with a typical example of nonalcoholic steatohepatitis (NASH) progressing toward cirrhosis, with multiple risk factors including diabetes mellitus, hyperlipidemia, obesity, and mildly elevated hepatic transaminases. Abnormalities of other cell lines would likely occur if a hematologic malignancy or bone marrow failure were present. While immune thrombocytopenic purpura is a diagnostic consideration, it is much less common than NASH and requires other causes to be ruled out. This patient is not taking any medications that have been frequently reported to cause drug-induced thrombocytopenia.

Ref: Gauer RL, Braun MM: Thrombocytopenia. *Am Fam Physician* 2012;85(6):612-622.

Item 46

ANSWER: D

NSAIDs such as ibuprofen are thought to increase the risk of anastomotic ulcerations or perforations in patients who have had bariatric surgery and should be completely avoided after such surgery if possible (C Recommendation, Level of evidence 3). It is also recommended that alternative pain medications that can be used are identified prior to the surgery (D Recommendation). Options such as acetaminophen, gabapentin, hydrocodone, and tramadol can be considered in patients who have had bariatric surgery if the medications are clinically appropriate otherwise.

Ref: Mechanick JI, Youdim A, Jones DB, et al: Clinical practice guidelines for the perioperative nutritional, metabolic, and nonsurgical support of the bariatric surgery patient—2013 update: Cosponsored by American Association of Clinical Endocrinologists, the Obesity Society, and American Society for Metabolic & Bariatric Surgery. *Obesity (Silver Spring)* 2013;21(Suppl 1):S1-S27. 2) Schroeder R, Harrison TD, McGraw SL: Treatment of adult obesity with bariatric surgery. *Am Fam Physician* 2016;93(1):31-37.

Item 47

ANSWER: B

It is important to distinguish serious illness from benign causes of proteinuria, which are the most common etiology in children. Confirming the presence of proteinuria is the next step in this case because functional (exercise/stress-induced) and orthostatic proteinuria are common types of proteinuria and are transient. A 24-hour urine for protein is a possible option, but would be impractical and burdensome for a healthy-acting 11-year-old. The pediatric nephrology panel of the National Kidney Foundation reported that a spot protein/creatinine ratio is a reliable test for ruling out proteinuria. A specialist referral, blood analysis, and ultrasonography are unnecessary unless persistent proteinuria is identified.

Ref: Hogg RJ, Portman RJ, Milliner D, et al: Evaluation and management of proteinuria and nephrotic syndrome in children: Recommendations from a pediatric nephrology panel established at the National Kidney Foundation conference on proteinuria, albuminuria, risk, assessment, detection, and elimination (PARADE). *Pediatrics* 2000;105(6):1242-1249. 2) Leung AK, Wong AH, Barg SS: Proteinuria in children: Evaluation and differential diagnosis. *Am Fam Physician* 2017;95(4):248-254.

Item 48

ANSWER: B

The only evidence-based treatment that confers significant benefits to children with autism is intensive behavioral interventions, which should be initiated before 3 years of age. Attention-deficit/hyperactivity disorder can be treated with cognitive-behavioral therapy (CBT) but medication is often required. CBT is as effective, if not more effective, than medication for treating anxiety, depression, and trauma-related disorders.

Ref: Coffey SF, Banducci AN, Vinci C: Common questions about cognitive behavior therapy for psychiatric disorders. *Am Fam Physician* 2015;92(9):807-812.

Item 49

ANSWER: A

The recombinant zoster vaccine is preferred over the live zoster vaccine due to its increased efficacy. The recombinant vaccine is estimated to be about 97% effective for preventing shingles, compared to 51% with the live vaccine. It requires two intramuscular doses separated by 2–6 months, compared to only one subcutaneous dose with the live vaccine. It is also slightly more expensive than the live vaccine. Although the recombinant vaccine is not a live vaccine, studies are still ongoing as to whether it is safe to give to immunocompromised patients.

Ref: Le P, Sabella C, Rothberg MB: Preventing herpes zoster through vaccination: New developments. *Cleve Clin J Med* 2017;84(5):359-366. 2) Shingrix: A new herpes zoster vaccine. *Prescriber's Letter* 2017;24(12).

Item 50

ANSWER: D

The increase in opiate-related accidental overdoses has become a significant concern in recent years, prompting the CDC to release updated guidelines for the use of narcotic medications for chronic noncancer pain. There are several concerning issues in this patient's care. Her obstructive sleep apnea, psychiatric ailments, and concurrent use of opiates and benzodiazepines all increase the risk of an accidental overdose. The CDC also warns against using opiates in patients with heart failure, chronic pulmonary diseases, and a personal history of drug or alcohol abuse.

These risks are so great that the CDC recommends that chronic noncancer pain be primarily treated with nonpharmacologic and nonopioid medications. The use of opioids should be reserved for recalcitrant cases under close supervision at the lowest effective dose for the shortest time possible. The CDC also recommends against using opiates in fibromyalgia and neuropathy due to limited efficacy and side-effect profiles (SOR B). The concurrent use of opiates and benzodiazepines should be avoided in nearly all situations (SOR C). Safety should never be compromised for reduced pain and increased functionality.

Ref: Hudson S, Wimsatt LA: How to monitor opioid use for your patients with chronic pain. *Fam Pract Manag* 2014;21(6):6-11. 2) Raleigh MF, Dunn AM: Controlled-release oxycodone for neuropathic pain and fibromyalgia in adults. *Am Fam Physician* 2015;91(5):286-287. 3) Bredemeyer M: CDC develops guideline for opioid prescribing. *Am Fam Physician* 2016;93(12):1042-1043. 4) Wingrove P, Park B, Bazemore A: Rural opioid use disorder treatment depends on family physicians. *Am Fam Physician* 2016;94(7):546. 5) Lembke A, Humphreys K, Newmark J: Weighing the risks and benefits of chronic opioid therapy. *Am Fam Physician* 2016;93(12):982-990.

Item 51

ANSWER: A

According to the CDC, cough is the most common symptom resulting in primary care visits. Chronic cough in adults is defined as one that lasts 8 weeks or more. The workup should include a history focusing on potential triggers, as well as the identification of any red flags. If the physical examination is normal and the patient's history does not indicate the cause of the cough, a chest radiograph is appropriate.

The most common cause of chronic cough in adults is upper airway cough syndrome. Patients might have nasal symptoms such as rhinorrhea or congestion. Physical findings can include swollen turbinates and posterior pharyngeal cobblestoning, or they can be unremarkable. Initial treatment may include the use of decongestants, oral or intranasal antihistamines, intranasal corticosteroids, or saline nasal rinses (SOR C). Symptoms should resolve within a few weeks, and referral for allergy testing can be considered if they are not resolved within 2 months. CT of the sinuses can be considered as well, but sinus radiographs are more specific.

Other common causes of chronic cough include asthma, nonasthmatic eosinophilic bronchitis, and GERD. If asthma is suspected, spirometry is indicated. If spirometry is positive for asthma, a trial of an inhaled bronchodilator is indicated. If there are other indications of GERD such as heartburn, globus sensation, or hoarseness, an antacid or a trial of a proton pump inhibitor is indicated.

Ref: Michaudet C, Malaty J: Chronic cough: Evaluation and management. *Am Fam Physician* 2017;96(9):575-580.

Item 52**ANSWER: D**

Hypertonic osmotic laxatives such as milk of magnesia, magnesium citrate, and sodium phosphate draw water into the bowel and should be used with caution in older adults and those with renal impairment because of the risk of electrolyte abnormalities and dehydration in patients with irritable bowel syndrome (IBS). Lactulose, also an osmotic laxative, should be avoided in patients with IBS because it is broken down by colonic flora and produces excessive gas. Polyethylene glycol, a long-chain polymer of ethylene oxide, is a large molecule that causes water to be retained in the colon, which softens the stool and increases the number of bowel movements. It is approved by the FDA for short-term treatment in adults and children with occasional constipation and is commonly prescribed for patients with IBS. It is considered safe and effective for moderate to severe constipation when used either daily or as needed.

Ref: Sultan S, Malhotra A: Irritable bowel syndrome. *Ann Intern Med* 2017;166(11):ITC81-ITC96.

Item 53**ANSWER: C**

Distal biceps tendon ruptures are relatively uncommon, accounting for about 3% of tendon ruptures. In a patient with a suspected distal biceps tendon rupture, clinical signs can be unreliable and MRI imaging is the test of choice. Bony abnormalities do not contribute to the evaluation of this tendon. A Speed's test is used to evaluate pain related to the long head of the biceps tendon. Surgical repair is the treatment of choice when the tendon is ruptured. Physical therapy and local corticosteroid injections are not beneficial.

Ref: Churgay CA: Diagnosis and treatment of biceps tendinitis and tendinosis. *Am Fam Physician* 2009;80(5):470-476. 2) Kane SF, Lynch JH, Taylor JC: Evaluation of elbow pain in adults. *Am Fam Physician* 2014;89(8):649-657.

Item 54**ANSWER: C**

According to the American Diabetes Association's 2018 guidelines for the management of diabetes, a healthy person with a reasonable life expectancy should have a hemoglobin A_{1c} goal of <7%. Metformin is recommended as first-line therapy as long as there are no contraindications. If the hemoglobin A_{1c} is not at the goal or is ≥9%, then adding another agent to metformin is recommended. Basal insulin at 10 units/day is an acceptable choice for additional therapy to improve blood glucose control. Diet, exercise, and home monitoring of blood glucose are recommended in addition to starting another agent for blood glucose control.

Ref: American Diabetes Association: 6. Glycemic targets: Standards of medical care in diabetes-2018. *Diabetes Care* 2018;41(Suppl 1):S55-S64. 2) American Diabetes Association: 8. Pharmacologic approaches to glycemic treatment: Standards of medical care in diabetes-2018. *Diabetes Care* 2018;41(Suppl 1):S73-S85.

Item 55**ANSWER: D**

Nephrotic syndrome includes peripheral edema, heavy proteinuria, and hypoalbuminemia. Hyperlipidemia also occurs frequently and can be significant. Nephrotic-range proteinuria is a spot urine showing a protein/creatinine ratio >3.0 – 3.5 mg protein/mg creatinine or a 24-hour urine collection showing >3.0 – 3.5 g of protein. Testing urine for ketones, pH, specific gravity, or crystals does not help to diagnose nephrotic syndrome.

Ref: Kodner C: Diagnosis and management of nephrotic syndrome in adults. *Am Fam Physician* 2016;93(6):479-485.

Item 56**ANSWER: B**

Most orally administered immediate-release opioids such as morphine, oxycodone, and hydromorphone reach their peak effect at about 1 hour, at which time additional medication can be given if the patient is still in pain. Intravenous opioids reach their peak effect at about 10 minutes and intramuscular and subcutaneous opioids at about 20–30 minutes. Additional medication may therefore be given at those intervals if additional pain relief is required.

Ref: Groninger H, Vijayan J: Pharmacologic management of pain at the end of life. *Am Fam Physician* 2014;90(1):26-32.

Item 57**ANSWER: A**

The only proven therapy for pulmonary hypertension related to COPD is supplemental oxygen. Supplemental oxygen should be recommended when the PaO_2 is <60 mm Hg, because it has been shown to improve mortality by lowering pulmonary arterial pressures. Treatments effective for pulmonary artery hypertension should not be used. Pulmonary vasodilators such as nifedipine, sildenafil, and bosentan may cause a ventilation-perfusion mismatch. Pulmonary endarterectomy may be indicated for pulmonary hypertension caused by chronic thromboembolic disease.

Ref: Mandel J, Poch D: Pulmonary hypertension. *Ann Intern Med* 2013;158(9):ITC5-1-ITC5-16. 2) Dunlap B, Weyer G: Pulmonary hypertension: Diagnosis and treatment. *Am Fam Physician* 2016;94(6):463-469.

Item 58**ANSWER: E**

Diuretics lessen the severity of obstructive sleep apnea and reduce blood pressure. Aldosterone antagonists offer further benefit beyond that of traditional diuretics. Resistant hypertension is common in patients with obstructive sleep apnea. Resistant hypertension is also associated with higher levels of aldosterone, which can lead to secondary pharyngeal edema, increasing upper airway obstruction.

Ref: Torres G, Sánchez-de-la-Torre M, Barbé F: Relationship between OSA and hypertension. *Chest* 2015;148(3):824-832.

Item 59**ANSWER: A**

The number needed to treat (NNT) is defined as the number of people who would need to receive an intervention in order for one person to benefit. It is the inverse of the absolute risk reduction (ARR). The ARR is the difference in risk for a disease without and with an intervention. The correct formula for calculating NNT is $1/ARR$.

Ref: *Final Recommendation Statement: Obesity in Adults: Screening and Management*. US Preventive Services Task Force, 2016. 2) EBM glossaries. *American Family Physician* website, 2018.

Item 60**ANSWER: C**

The Endocrine Society recommends hormonal contraception as the first-line medication for women diagnosed with polycystic ovary syndrome (PCOS) who are experiencing irregular menses, acne, and hirsutism and do not desire pregnancy (SOR A). Metformin may help regulate menses but has not been shown to be as effective as oral hormone therapy. In a 2015 Cochrane review, oral contraceptives were recommended as the most effective treatment for hirsutism. Either letrozole or clomiphene is appropriate for women diagnosed with PCOS who want to become pregnant.

Ref: Williams T, Mortada R, Porter S: Diagnosis and treatment of polycystic ovary syndrome. *Am Fam Physician* 2016;94(2):106-113.

Item 61**ANSWER: A**

Despite the prevalence of osteoarthritis of the knee and a myriad of treatment modalities available for those with symptomatic disease, there is very limited evidence to suggest that many of these treatments are effective. There is strong evidence to suggest that self-management programs, strengthening exercises, low-impact aerobic exercises, and neuromuscular education have some benefit. Moderate evidence recommends against the use of needle lavage of the knee; the two main studies of this modality showed little or no benefit. In 15 studies, 14 outcomes were not statistically significant, including three pain and three functional outcomes. There is also moderate evidence to recommend against the use of lateral wedge insoles. Four studies of lateral wedge insoles showed no significant change in pain or function of the knee when compared to neutral insoles. The evidence is inconclusive for platelet-rich plasma injections. A few studies have shown decreased pain in patients after injection, but there was no placebo control, so the effectiveness cannot be adequately assessed. Glucosamine and chondroitin have been shown with strong evidence to be ineffective when compared to placebo.

Ref: American Academy of Orthopaedic Surgeons (AAOS): American Academy of Orthopaedic Surgeons clinical practice guideline on treatment of osteoarthritis of the knee. 2nd ed. American Academy of Orthopaedic Surgeons, 2013.

Item 62**ANSWER: C**

According to the Choosing Wisely recommendations from the American Society of Anesthesiologists, opioids should not be used as first-line therapy for chronic noncancer pain. However, more than one-half of patients who receive continuous opioids for 90 days are still receiving them after 4 years. Chronic opioids should not be abruptly discontinued. When discontinuing chronic opioid therapy, the best practice is to reduce the dosage by 5%–10% every 1–4 weeks, but even this may be too fast for some patients.

While controlled substance prescribing plans are considered good practice for long-term opioid use, continuing opioids for this patient would not be good practice given the indication of chronic noncancer pain and the need for safety in her work. Because her use of opioids should be tapered, weekly urine drug screens would continue to be positive and therefore would not be an appropriate management strategy for this patient. NSAIDs are not indicated for this patient due to her history of gastric bypass.

Ref: Lembke A, Humphreys K, Newmark J: Weighing the risks and benefits of chronic opioid therapy. *Am Fam Physician* 2016;93(12):982-990.

Item 63**ANSWER: B**

Pain in the shoulder of a young athlete can be caused by many problems, including acromioclavicular strain, biceps tendinitis, glenohumeral instability, and rotator cuff pathology. Although rotator cuff pathologies are the most frequent cause of shoulder pain in adults, they are uncommon in children. Unique to children, however, is a repetitive use injury causing disruption at the proximal growth plate of the humerus. This condition is referred to as Little League shoulder and can be seen on plain radiographs as widening, demineralization, or sclerosis at the growth plate. If the radiograph is normal but suspicion for this condition is high, a bone scan or MRI can be ordered.

Ref: Cassas KJ, Cassettari-Wayhs A: Childhood and adolescent sports-related overuse injuries. *Am Fam Physician* 2006;73(6):1014-1022. 2) Dashe J, Roocroft JH, Bastrom TP, Edmonds EW: Spectrum of shoulder injuries in skeletally immature patients. *Orthop Clin North Am* 2013;44(4):541-551.

Item 64**ANSWER: E**

This patient has a recurrent outbreak of genital herpes, and valacyclovir is the preferred treatment. Penicillin G benzathine is a treatment for syphilis, which usually begins as a painless papule that transforms into the classic chancre. Fluconazole and metronidazole are treatments for yeast vaginitis and bacterial vaginitis; these conditions present with itching and a vaginal discharge but not vesicular lesions. Doxycycline is a treatment for *Chlamydia* infection, which is often completely asymptomatic and detected only with screening.

Ref: Groves MJ: Genital herpes: A review. *Am Fam Physician* 2016;93(11):928-934.

Item 65**ANSWER: E**

This patient has symptoms and examination findings that are concerning for acute angle-closure glaucoma. Her risk factors include her age, sex, and Asian ancestry. The examination findings include conjunctival redness, corneal edema, a poorly reactive mid-dilated pupil, decreased vision, severe eye pain, headache, and nausea. This condition needs to be evaluated and treated emergently to preserve vision. The examination is not consistent with infectious conjunctivitis, which generally does not cause severe pain, headache, or decreased pupillary response. Conditions such as scleritis or episcleritis may present with similar features, but the pupillary response may help differentiate them from glaucoma. Referral to an ophthalmologist would still be most prudent. This patient's presentation is not consistent with a vasculitis or multiple sclerosis.

Ref: Kasper DL, Fauci AS, Hauser SL, et al (eds): *Harrison's Principles of Internal Medicine*, ed 19. McGraw-Hill, 2015, pp 200, 205. 2) Walls RM, Hockberger RS, Gausche-Hill M, et al (eds): *Rosen's Emergency Medicine: Concepts and Clinical Practice*, ed 9. Elsevier Inc, 2018, p 807.

Item 66**ANSWER: A**

Antidepressants in every class (SSRIs, SNRIs, tricyclic antidepressants, and monoamine oxidase inhibitors) have been shown to reduce bulimic symptoms and can be used safely to treat depression, with the exception of bupropion. Bupropion use has been associated with an increased risk of seizures in patients with bulimia and an FDA warning limits its use.

Ref: Katzung B, Trevor A: *Basic & Clinical Pharmacology*, ed 13. McGraw-Hill Education, 2015, pp 510-530. 2) Wellbutrin XL prescribing information. US Food and Drug Administration, 2017.

Item 67**ANSWER: A**

Internal tibial torsion usually resolves spontaneously by age 5. Surgery may be considered in patients older than 8 years of age who have a severe residual deformity, especially if it is symptomatic or cosmetically unacceptable. Night splints, shoe modifications, other orthotics, casting, and braces are not recommended for this condition.

Ref: Rerucha CM, Dickison C, Baird DC: Lower extremity abnormalities in children. *Am Fam Physician* 2017;96(4):226-233.

Item 68**ANSWER: D**

This patient's history and examination findings are typical for exercise-induced asthma. The most appropriate initial treatment for this condition is an inhaled short-acting β_2 -agonist (SABA) 15 minutes before exercise (SOR A). Daily use of an inhaled long-acting β_2 -agonist as a single agent is not recommended even for those who continue to experience symptoms when using an inhaled SABA (SOR B). The addition of a daily inhaled corticosteroid is an appropriate consideration for patients who require more than a SABA to control symptoms but these should not be used on an as-needed basis before exercise (SOR B). Use of an antihistamine in an individual with exercise-induced asthma but no known allergies is not recommended (SOR B). Other treatment considerations with weak recommendations include a low-sodium diet, air humidification, and supplemental dietary fish oils.

Ref: Parsons JP, Hallstrand TS, Mastronarde JG, et al: An official American Thoracic Society clinical practice guideline: Exercise-induced bronchoconstriction. *Am J Respir Crit Care Med* 2013;187(9):1016-1027.

Item 69**ANSWER: C**

Hereditary hemochromatosis is a genetic disorder of iron regulation and subsequent iron overload. Possible end-organ damage includes cardiomyopathy, cirrhosis of the liver, and hepatocellular carcinoma. Symptoms are often nonspecific early on, but manifestations of iron overload eventually occur. The diagnosis should be suspected in patients with liver disease or abnormal iron studies indicative of iron overload. A liver biopsy can confirm the diagnosis and the degree of fibrosis. Identification of such patients and proper ongoing treatment with phlebotomy may prevent the development of hepatocellular carcinoma and other complications of this disease. There is some data that suggests an association of breast cancer with hereditary hemochromatosis but not with any of the other malignancies listed.

Ref: Crownover BK, Covey CJ: Hereditary hemochromatosis. *Am Fam Physician* 2013;87(3):183-190.

Item 70**ANSWER: E**

Yersinia pestis is an aerobic fermentative gram-negative rod. It causes a zoonotic infection with humans as the accidental host. The disease is spread by a bite from a flea vector, direct contact with infected tissue, or inhalation of infectious aerosols from a person with pulmonary plague. Plague occurs in two regions in the western United States. One region includes northern New Mexico, northern Arizona, and southern Colorado, and the other region includes California, southern Oregon, and far western Nevada.

Escherichia coli is also an aerobic fermentative gram-negative rod but it generally causes symptoms of gastroenteritis, hemolytic-uremic syndrome, urinary tract infection, intra-abdominal infection, and meningitis. *E. coli* infection does not have a specific regional distribution. *Listeria monocytogenes* is a gram-positive rod and causes an influenza-like illness with or without gastroenteritis in adults. Infection occurs through ingestion of contaminated food products such as milk, cheese, processed meats, and raw vegetables. Outbreaks can occur in any geographic distribution.

Coxiella burnetii is a gram-negative intracellular bacterium that causes Q fever. Human infections are associated with contact with infected cattle, sheep, goats, dogs, and cats. *Brucella melitensis* is a gram-negative coccobacilli that causes brucellosis. Humans are accidental hosts who can develop the disease from contact with tissues rich in erythritol, and from shedding of organisms in milk, urine, and birth products from goats and sheep.

Ref: Murray P: *Basic Medical Microbiology*. Elsevier, 2017, pp 28-29, 50-51, 54-55, 60, 89. 2) Plague: Maps and statistics. Centers for Disease Control and Prevention, 2018.

Item 71

ANSWER: E

In young adults diagnosed with secondary hypertension, evaluation for fibromuscular dysplasia of the renal arteries with MR angiography or CT angiography is indicated (SOR C). The aldosterone/renin ratio is the most sensitive test to diagnose primary hyperaldosteronism. Renal ultrasonography is an indirect test that is not as sensitive or specific for fibromuscular dysplasia. Serum creatinine elevation shows renal involvement but does not identify the cause. Testing for metanephrines is indicated only if a pheochromocytoma is suspected.

Ref: Charles L, Triscott J, Dobbs B: Secondary hypertension: Discovering the underlying cause. *Am Fam Physician* 2017;96(7):453-461.

Item 72

ANSWER: E

Because debilitating knee osteoarthritis is a frequent health concern in older adults, physicians should try to identify and possibly modify factors that increase the risk for this condition. Pooled data from many large studies has been sufficient to clearly identify several major risk factors for the development and progression of osteoarthritis of the knees. Overweight and obesity have consistently been found to approximately double the risk for developing knee osteoarthritis. Other factors that have been identified as risk factors include female sex, advancing age (50–75 years of age), and previous trauma. Smoking, inactivity, moderate physical activity, and socioeconomic status have not been shown to affect one's risk for developing knee osteoarthritis. However, any of these factors in the extreme may be detrimental to joint health in general.

Ref: Ringdahl E, Pandit S: Treatment of knee osteoarthritis. *Am Fam Physician* 2011;83(11):1287-1292. 2) Hauk L: Treatment of knee osteoarthritis: A clinical practice guideline from the AAOS. *Am Fam Physician* 2014;89(11):918-920.

Item 73**ANSWER: E**

This patient has asymptomatic bacteriuria and does not require antibiotic therapy at this time. In women age 70 and older the incidence of asymptomatic bacteriuria is 16%–18%, and in chronically incontinent and disabled older adults rates may reach 43%. Symptoms that raise concern for a urinary tract infection (UTI) include acute dysuria, new or worsening urinary urgency or frequency, new incontinence, gross hematuria, and suprapubic or costovertebral angle tenderness. General malaise in the absence of these symptoms is unlikely to represent a UTI and unlikely to improve with antibiotic therapy.

When antibiotic therapy is indicated for a UTI, trimethoprim/sulfamethoxazole remains the first-line agent. Nitrofurantoin may be used for those with a creatinine clearance $>40 \text{ mL/min/1.73 m}^2$. Ciprofloxacin is recommended as a first-line agent only in communities with trimethoprim/sulfamethoxazole resistance rates above 10%–20%. Fosfomycin may be used for more highly resistant organisms. The choice of antibiotic should be guided by bacterial pathogens if they are known.

Ref: Mody L, Juthani-Mehta M: Urinary tract infections in older women: A clinical review. *JAMA* 2014;311(8):844-854.

Item 74**ANSWER: B**

The panel members of the Eighth Joint National Committee for the management of blood pressure recommended that ACE inhibitors should be initiated for renal protection in adults with diabetes mellitus, hypertension, and microalbuminuria. This patient appears to be in an early stage of nephropathy, and ACE inhibitors will reduce the decline in renal function. β -Blockers are no longer recommended for first-line treatment. In white patients who do not have diabetes, therapy may be started with ACE inhibitors, thiazide diuretics, or calcium channel blockers.

Ref: James PA, Oparil S, Carter BL, et al: 2014 evidence-based guideline for the management of high blood pressure in adults: Report from the panel members appointed to the Eighth Joint National Committee (JNC 8). *JAMA* 2014;311(5):507-520.

Item 75**ANSWER: B**

CT angiography (CTA) is the recommended imaging procedure for the diagnosis of acute mesenteric vascular disease. The procedure can also identify other possible intra-abdominal causes of pain. Duplex ultrasonography is also accurate, especially for proximal lesions, but can be difficult to perform in patients with obesity, bowel gas, and marked calcification of the vessels, and may be problematic in patients presenting acutely, due to the length of the study and the abdominal pressure required. It is more useful in cases of suspected chronic mesenteric ischemia. Endoscopy is often normal in acute ischemia and may not reach the ischemic section of bowel. MR angiography may be useful, but it takes longer to perform than CTA and lacks the necessary resolution. Catheter angiography is required for endovascular therapies such as thrombolysis or angioplasty with or without stenting, but is usually not performed for making the initial diagnosis in the acute setting.

Ref: Clair DG, Beach JM: Mesenteric ischemia. *N Engl J Med* 2016;374(10):959-968.

Item 76**ANSWER: C**

Family physicians are often asked to provide contraception and need to be familiar with the current methods and contraindications. Estrogen-containing products, including the contraceptive patch and the vaginal ring, are contraindicated in smokers > 35 years of age and in patients with migraine with aura.

Ref: Curtis KM, Tepper NK, Jatlaoui TC, et al: US medical eligibility criteria for contraceptive use, 2016. *MMWR Recomm Rep* 2016;65(3):62.

Item 77**ANSWER: B**

Patients who are resistant to change require skillful management. Motivational interviewing is a technique that has been shown to improve the therapeutic physician-patient alliance and help to engage patients in their own care. The other options listed are not helpful and may damage the therapeutic relationship.

Ref: Cannarella Lorenzetti R, Jacques CH, Donovan C, et al: Managing difficult encounters: Understanding physician, patient, and situational factors. *Am Fam Physician* 2013;87(6):419-425.

Item 78**ANSWER: A**

This patient initially showed signs of acute mountain sickness. These include headache in an unacclimated person who recently arrived at an elevation >2500 m (8200 ft), plus one or more of the following: anorexia, nausea, vomiting, insomnia, dizziness, or fatigue. The patient's condition then deteriorated to high-altitude cerebral edema, defined as the onset of ataxia and/or altered consciousness in someone with acute mountain sickness. The management of choice is a combination of descent and supplemental oxygen. Often, a descent of only 500–1000 m (1600–3300 ft) will lead to resolution of acute mountain sickness. Simulated descent with a portable hyperbaric chamber also is effective, but descent should not be delayed while awaiting helicopter delivery. If descent and/or administration of oxygen is not possible, medical therapy with dexamethasone and/or acetazolamide may reduce the severity of symptoms. Nifedipine has also been shown to be helpful in cases of high-altitude pulmonary edema where descent and/or supplemental oxygen is unavailable.

Ref: Walls RM, Hockberger RS, Gausche-Hill M, et al (eds): *Rosen's Emergency Medicine: Concepts and Clinical Practice*, ed 9. Elsevier Inc, 2018, pp 1791-1793, 1797-1798.

Item 79

ANSWER: C

This patient most likely has a basal cell carcinoma, which can be proven by a shave biopsy. Given its size and location, Mohs surgery would be the preferred treatment. It also has the highest cure rate of any of the options listed, including a standard wide excision, electrodesiccation and curettage, photodynamic therapy, and radiation therapy. It has a 99% cure rate for primary basal cell cancers, compared with just over 91% for other methods. Photodynamic therapy and radiation therapy should be used for lesions such as this only if surgery is not an option due to medical comorbidities and/or patient preference.

Ref: Firnhaber JM: Diagnosis and treatment of basal cell and squamous cell carcinoma. *Am Fam Physician* 2012;86(2):161-168.

Item 80

ANSWER: A

This 55-year-old patient is undergoing a low-risk procedure. While her diabetes mellitus is a cardiovascular risk factor, she is asymptomatic, her age lowers her risk, and her functional status is good. She should be allowed to undergo cataract surgery with no further evaluation. Guidelines from the American College of Cardiology and the American Heart Association recommend that the patient be allowed to undergo surgery with no further testing.

Ref: Fleisher LA, Fleischmann KE, Auerbach AD, et al: 2014 ACC/AHA guideline on perioperative cardiovascular evaluation and management of patients undergoing noncardiac surgery: A report of the American College of Cardiology/American Heart Association Task Force on practice guidelines. *J Am Coll Cardiol* 2014;64(22):e77-e137. 2) Arnold MJ, Beer J: Preoperative evaluation: A time-saving algorithm. *J Fam Pract* 2016;65(10):702-710.

Item 81

ANSWER: E

The novel anticoagulants (NOACs) require dosage adjustments based on renal function. There are no dosing recommendations for NOACs based on liver function or albumin level. The INR is used to adjust warfarin dosing and the partial thromboplastin time is used to adjust heparin dosing.

Ref: Steinberg BA, Piccini JP: Anticoagulation in atrial fibrillation. *BMJ* 2014;348:g2116. 2) Gutierrez C, Blanchard DG: Diagnosis and treatment of atrial fibrillation. *Am Fam Physician* 2016;94(6):442-452.

Item 82

ANSWER: A

For this patient, acamprosate is the most effective medication to help maintain alcohol abstinence. Antidepressants may be beneficial in patients with coexisting depression. The antiemetic ondansetron may also help decrease alcohol consumption in patients with alcohol use disorder.

Ref: Winslow BT, Onysko M, Hebert M: Medications for alcohol use disorder. *Am Fam Physician* 2016;93(6):457-465.

Item 83**ANSWER: E**

This patient has risk factors and symptoms that suggest esophageal cancer. According to the Society of Thoracic Surgeons and the National Comprehensive Cancer Network, upper endoscopy with a biopsy of suspicious lesions is the recommended initial evaluation for symptoms of esophageal cancer (SOR C). Esophagography would be appropriate in patients unable to undergo endoscopy but would not be the preferred test. CT of the abdomen is not indicated in the initial evaluation for esophageal cancer but can be integrated with a PET scan for staging. Esophageal manometry is reserved for patients with dysphagia if upper endoscopy does not establish a diagnosis and a motility disorder is suspected. Increasing the dosage of the proton pump inhibitor would not be an appropriate treatment for this patient's condition and may delay the diagnosis and treatment of suspected cancer if the patient is not referred promptly for upper endoscopy.

Ref: Short MW, Burgers KG, Fry VT: Esophageal cancer. *Am Fam Physician* 2017;95(1):22-28.

Item 84**ANSWER: D**

This adolescent has findings of Marfan syndrome. It is associated with arachnodactyly, an arm span greater than height, a high arched palate, kyphosis, lenticular dislocation, mitral valve prolapse, myopia, and pectus excavatum. The cardiac examination may reveal an aortic insufficiency murmur, or a murmur associated with mitral valve prolapse. Cardiovascular defects are progressive, and aortic root dilation occurs in 80%–100% of affected individuals. Aortic regurgitation becomes more common with increasing age.

Ref: Mirabelli MH, Devine MJ, Singh J, Mendoza M: The preparticipation sports evaluation. *Am Fam Physician* 2015;92(5):371-376. 2) Kliegman RM, Stanton BF, Geme JW III, et al (eds): *Nelson Textbook of Pediatrics*, ed 20. Elsevier Saunders, 2016, pp 3384-3386.

Item 85**ANSWER: B**

While a plain chest radiograph should come first in the workup for hemoptysis, patients with normal radiographs who have a higher risk of malignancy (age ≥ 40 and a smoking history of ≥ 30 years) should undergo CT, usually with contrast. If CT is negative, pulmonary consultation and possible bronchoscopy should be pursued. Nasolaryngoscopy is not indicated if the initial history and examination do not indicate an upper airway source. Observation alone is not appropriate in patients with risk factors for malignancy.

Ref: Ketai LH, Mohammed TL, Kirsch J, et al: ACR appropriateness criteria hemoptysis. *J Thorac Imaging* 2014;29(3):W19-W22. 2) Earwood JS, Thompson TD: Hemoptysis: Evaluation and management. *Am Fam Physician* 2015;91(4):243-249.

Item 86**ANSWER: E**

This patient has severe symptomatic aortic stenosis. The only therapy shown to improve symptoms and mortality in such patients is an aortic valve replacement. In patients with asymptomatic disease, watchful waiting is usually the recommended course of action. No medications or other therapies have been shown to prevent disease progression or alleviate symptoms. Patients with coexisting hypertension should be managed medically according to accepted guidelines. Diuretics should be used with caution due to their potential to reduce left ventricular filling and cardiac output, which leads to an increase in symptoms.

Ref: Nishimura RA, Otto CM, Bonow RO, et al: 2014 AHA/ACC guideline for the management of patients with valvular heart disease: A report of the American College of Cardiology/American Heart Association Task Force on Practice Guidelines. *Circulation* 2014;129(23):e521-e643. 2) Grimard BH, Safford RE, Burns EL: Aortic stenosis: Diagnosis and treatment. *Am Fam Physician* 2016;93(5):371-378.

Item 87**ANSWER: A**

The Rome IV criteria are widely used as guidelines to diagnose suspected irritable bowel syndrome. These criteria specify that there should be recurrent abdominal pain associated with two or more additional symptoms at least 1 day per week in the last 3 months. These symptoms include pain related to defecation, a change in stool frequency, or a change in stool form. Pain brought on by eating and increased gas and bloating are observed in irritable bowel syndrome but are not included in the Rome IV criteria. Weight loss and waking at night to defecate are not typically seen in this disorder.

Ref: Mearin F, Lacy BE, Chang L, et al: Bowel disorders. *Gastroenterology* 2016;pii:S0016-5085(16)00222-5. 2) Lacy BE, Patel NK: Rome criteria and a diagnostic approach to irritable bowel syndrome. *J Clin Med* 2017;6(11):pii:E99.

Item 88**ANSWER: C**

The U.S. Preventive Services Task Force recommends screening for gestational diabetes mellitus after 24 weeks gestation with a fasting blood glucose level, a 50-g oral glucose challenge, or an assessment of risk factors (A recommendation). Screening at an earlier date receives a rating of insufficient evidence, and screening at later dates is not recommended (SOR C).

Ref: *Final Recommendation Statement: Gestational Diabetes Mellitus, Screening*. US Preventive Services Task Force, 2016.

Item 89**ANSWER: D**

A stress fracture in the proximal fifth metatarsal is particularly prone to nonunion and completion of the fracture. Because complete non-weight bearing or surgical intervention may be necessary with this high-risk fracture, MRI is indicated as the most sensitive test. Bone scans are sensitive but nonspecific. Most stress fractures of the metatarsals occur distally and can be managed with a hard shoe initially, with progressive activity as tolerated. NSAIDs are discouraged because of possible effects on fracture healing.

Ref: Pegrum J, Dixit V, Padhiar N, Nugent I: The pathophysiology, diagnosis, and management of foot stress fractures. *Phys Sportsmed* 2014;42(4):87-99.

Item 90**ANSWER: E**

Both typical and atypical antipsychotics increase the risk of mortality in patients with dementia. The FDA has a black box warning on these medications, including risperidone, about the increased risk of mortality in patients with dementia. Risperidone is not approved by the FDA for dementia-related psychosis. The typical antipsychotics are more commonly associated with extrapyramidal side effects. Diabetes mellitus and agranulocytosis are associated with the atypical antipsychotics, including risperidone. Periodic monitoring of serum glucose levels and CBCs is recommended.

Ref: Reese TR, Thiel DJ, Cocker KE: Behavioral disorders in dementia: Appropriate nondrug interventions and antipsychotic use. *Am Fam Physician* 2016;94(4):276-282. 2) Risperdal prescribing information. US Food and Drug Administration, revised 2017.

Item 91**ANSWER: B**

Since many patients with diabetes mellitus are obese, the impact of medications on the patient's weight is important to consider. Treatment with sulfonylureas, including glimepiride, is associated with weight gain. Empagliflozin, liraglutide, metformin, and sitagliptin are not associated with weight gain. In particular, the SGLT2 inhibitors such as empagliflozin and the GLP1 agonists such as liraglutide are associated with clinically significant weight loss.

Ref: George CM, Bruijn LL, Will K, Howard-Thompson A: Management of blood glucose with noninsulin therapies in type 2 diabetes. *Am Fam Physician* 2015;92(1):27-34.

Item 92**ANSWER: E**

This patient's EKG shows atrial fibrillation with a rapid ventricular response. A TSH level should be obtained in all patients presenting with acute atrial fibrillation, because patients with subclinical hyperthyroidism have a threefold increased risk of developing atrial fibrillation. D-dimer has a negative predictive value in the diagnosis of pulmonary embolism. Elevated troponin is a diagnostic marker of acute myocardial infarction and a troponin level should be obtained when acute coronary syndrome is being considered as a cause of acute atrial fibrillation. Elevated lactic acid is associated with sepsis. BNP levels should be ordered if heart failure is suspected (SOR C).

Ref: Selmer C, Olesen JB, Hansen ML, et al: The spectrum of thyroid disease and risk of new onset atrial fibrillation: A large population cohort study. *BMJ* 2012;345:e7895. 2) Zipes DP, Libby P, Bonow RO, et al (eds): *Braunwald's Heart Disease: A Textbook of Cardiovascular Medicine*, ed 11. Elsevier Health Sciences, p 1807.

Item 93**ANSWER: A**

This patient's history and the examination support the diagnosis of adolescent physiologic gynecomastia. The most appropriate next step is follow-up with this patient in 6–12 months. One-half of all adolescent males will experience some form of gynecomastia. This condition is often bilateral, but it is more common on the left side if it is unilateral. It will typically resolve 6–24 months after onset. Patients should be asked about medications and supplements, because these may be a cause of nonphysiologic breast enlargement. Concerning factors include persistence for longer than 2 years; hard, immobile, nontender masses; masses > 5 cm; nipple discharge; testicular masses; and systemic symptoms such as weight loss. Evaluation for persistent gynecomastia can include laboratory studies to exclude hepatic, renal, and thyroid disorders, and can progress to include tests to detect gonadotropin and hormone-related tumors and disorders. Imaging and/or a biopsy would be indicated if signs of a carcinoma were noted. The additional options listed are not indicated at this point, although they are a part of the recommended algorithm for further evaluation and treatment considerations.

Ref: Dickson G: Gynecomastia. *Am Fam Physician* 2012;85(7):716-722.

Item 94**ANSWER: B**

Seborrheic dermatitis is commonly seen in the office setting and affects the scalp, eyebrows, nasolabial folds, and anterior chest. The affected skin appears as erythematous patches with white to yellow greasy scales. The etiology is not exactly known, but it is likely that the yeast *Malassezia* plays a role. Topical antifungals are effective and recommended as first-line agents. Topical low-potency corticosteroids are also effective alone or when used in combination with topical antifungals, but they should be used sparingly due to their adverse effects. The other agents listed have no role in the management of seborrheic dermatitis (SOR A).

Ref: Clark GW, Pope SM, Jaboori KA: Diagnosis and treatment of seborrheic dermatitis. *Am Fam Physician* 2015;91(3):185-190.

Item 95**ANSWER: C**

The U.S. Preventive Services Task Force (USPSTF) recommends one-time screening for hepatitis C virus infection for adults born between 1945 and 1965. Abdominal aortic aneurysm screening with ultrasonography is recommended for men 65–75 years of age who have any history of smoking. The USPSTF recommends annual screening for lung cancer with low-dose CT in adults 55–80 years of age who have a 30-pack-year smoking history and currently smoke or have quit within the past 15 years. Fall risk screening is recommended in community-dwelling adults 65 years of age or older.

Ref: USPSTF A and B Recommendations. US Preventive Services Task Force, 2018.

Item 96**ANSWER: E**

This patient has peripartum depression. All women should be screened for depression during pregnancy and the postpartum period (SOR B). Reassurance may be appropriate for the baby blues, which usually start 2–3 days after birth and last less than 10 days. First-time mothers, adolescent mothers, and mothers who have experienced a traumatic delivery may benefit from home health visits or peer support to prevent but not treat peripartum depression. Mild to moderate peripartum depression can be treated with psychotherapy or SSRIs, with consideration of medications with the lowest serum medication levels in breastfed infants. Tricyclic antidepressants such as trazodone are not considered first-line treatment for peripartum depression.

Ref: Langan R, Goodbred AJ: Identification and management of peripartum depression. *Am Fam Physician* 2016;93(10):852-858.

Item 97**ANSWER: D**

The American College of Rheumatology recommends methotrexate, a nonbiologic disease-modifying antirheumatic drug (DMARD), as a first-line agent in the treatment of rheumatoid arthritis in the absence of contraindications, such as underlying liver disease. Starting DMARDs within 3 months of the onset of rheumatoid arthritis symptoms is more likely to result in sustained remissions. The addition of short-term prednisone is indicated in select cases when disease activity is high. The use of biological agents such as adalimumab, etanercept, and others is indicated only in refractory cases and in patients who cannot tolerate nonbiologic DMARDs.

Ref: Wasserman A: Rheumatoid arthritis: Common questions about diagnosis and management. *Am Fam Physician* 2018;97(7):455-462.

Item 98**ANSWER: A**

Family physicians are often consulted for perioperative medical management. Studies have shown decreased perioperative mortality in patients who continue statins and in patients with clinical indications for statin therapy who start statins prior to undergoing vascular or high-risk surgeries such as joint replacement. A meta-analysis of 223,000 patients showed a significant reduction in perioperative mortality in patients receiving statin therapy versus placebo who underwent noncardiac surgical procedures. This patient has a clinical indication (multiple risk factors) to start statin therapy now.

Ref: Fleisher LA, Fleischmann KE, Auerbach AD, et al: 2014 ACC/AHA guideline on perioperative cardiovascular evaluation and management of patients undergoing noncardiac surgery: Executive summary: A report of the American College of Cardiology/American Heart Association Task Force on Practice Guidelines. *Circulation* 2014;130(24):2215-2245. 2) Mikhail MA, Mohabbat AB, Ghosh AK: Perioperative cardiovascular medication management in noncardiac surgery: Common questions. *Am Fam Physician* 2017;95(10):645-650.

Item 99**ANSWER: C**

Asymptomatic microhematuria is defined as 3 or more RBCs/hpf on a properly collected urine specimen in the absence of an obvious benign cause. Vigorous exercise, viral illness, trauma, and infection have been ruled out as a cause of hematuria in this patient. His renal function is normal. The most appropriate next step in evaluating a patient ≥ 35 years of age is to perform a urologic evaluation with cystoscopy. Cystoscopy is also recommended for patients of any age who have risk factors for urinary tract malignancy.

The initial examination should also include CT urography with and without contrast. When CT with contrast is contraindicated, an alternative is retrograde pyelography in conjunction with noncontrast CT, MR urography, or ultrasonography. Obtaining urine cytology and urine markers is not recommended as part of the routine evaluation of asymptomatic microhematuria. A repeat urinalysis with microscopy is not needed to confirm asymptomatic microhematuria. According to the American Urological Association, one positive urine sample is sufficient to prompt an evaluation.

Ref: Davis R, Jones JS, Barocas DA, et al: Diagnosis, evaluation and follow-up of asymptomatic microhematuria (AMH) in adults: AUA guideline. *J Urol* 2012;188(6 Suppl):2473-2481. 2) American Urological Association: Fifteen things physicians and patients should question. ABIM Foundation Choosing Wisely campaign, 2015.

Item 100**ANSWER: C**

This patient's presentation is concerning for hematologic malignancy, in particular multiple myeloma. Along with radiography, the next appropriate step is serum protein electrophoresis. If laboratory work shows a monoclonal spike or if a skeletal survey indicates lytic lesions, referral to an oncologist is indicated for a bone marrow biopsy. MRI of the lumbar spine would be premature and obtaining iron studies, a TSH level, or a vitamin B₁₂ level would not adequately address the initial abnormal laboratory studies or facilitate making the diagnosis of multiple myeloma.

Ref: Michels TC, Petersen KE: Multiple myeloma: Diagnosis and treatment. *Am Fam Physician* 2017;95(6):373-383.

Item 101**ANSWER: D**

Metformin should be the first medication prescribed for diabetes mellitus when an oral agent is required (SOR A). Metformin can efficiently lower glycemic levels and is linked to weight loss and fewer occurrences of hypoglycemia. It is also less expensive than most other options. If more than one agent is required, continuing metformin is recommended along with the addition of one or more of the following: a sulfonylurea such as glipizide, a thiazolidinedione such as pioglitazone, an SGLT2 inhibitor such as empagliflozin, or a DPP-4 inhibitor such as alogliptin.

Ref: Hauk L: Type 2 diabetes mellitus: ACP releases updated recommendations for oral pharmacologic treatment. *Am Fam Physician* 2017;96(7):472-473. 2) Qaseem A, Barry MJ, Humphrey LL, et al: Oral pharmacologic treatment of type 2 diabetes mellitus: A clinical practice guideline update from the American College of Physicians. *Ann Intern Med* 2017;166(4):279-290. 3) Armstrong C: ADA updates standards of medical care for patients with diabetes mellitus. *Am Fam Physician* 2017;95(1):40-43.

Item 102**ANSWER: D**

This patient has symptoms consistent with allergic rhinitis, and the presence of symptoms more than 4 days per week and for more than 4 weeks places her into the persistent symptoms category. In addition to allergen avoidance and patient education, an intranasal corticosteroid should be the first-line treatment for allergic rhinitis with persistent symptoms (SOR A).

The Choosing Wisely recommendations from the American Academy of Otolaryngology-Head and Neck Surgery Foundations include avoiding sinonasal imaging in patients with symptoms limited to a primary diagnosis of allergic rhinitis. Impermeable pillow or mattress covers are often recommended but there is no evidence of any benefit (SOR A). Intranasal saline irrigation is beneficial and can be used as monotherapy for mild intermittent symptoms, but intranasal corticosteroids are likely to provide more benefit for more persistent symptoms. Intranasal antihistamines such as azelastine are more expensive, less effective, and more likely to produce adverse effects than intranasal corticosteroids, so they are not recommended as first-line therapy (SOR B).

Ref: Sur DK, Plesa ML: Treatment of allergic rhinitis. *Am Fam Physician* 2015;92(11):985-992.

Item 103**ANSWER: C**

This patient likely has a venous stasis ulceration. The use of compression therapy with a pressure of 30–40 mm Hg is the mainstay of treatment. There is no evidence for the use of systemic antibiotics for lower-extremity ulcerations. Likewise, there is no evidence to support the use of either silver-based or honey-based preparations in ulcerations with no infection. Foam dressings are no more effective than other standard dressings.

Ref: Singer AJ, Tassiopoulos A, Kirsner RS: Evaluation and management of lower-extremity ulcers. *N Engl J Med* 2017;377(16):1559-1567.

Item 104**ANSWER: C**

Although lead poisoning in children has decreased over the past few decades it is still a problem in the pediatric population. The most reliable and cost-effective way to protect U.S. children from lead toxicity is primary prevention, which includes reducing or eliminating the sources of lead in the community. Checking serum lead levels after exposures, anticipatory guidance regarding hand washing or dust control, iron and calcium supplementation, and providing cleaning equipment have been shown to have either little or no effect, or they address high lead levels only after the lead poisoning has occurred.

Ref: Council on Environmental Health: Prevention of childhood lead toxicity. *Pediatrics* 2016;138(1):pii:e20161493.

Item 105**ANSWER: D**

The use of gadolinium contrast has been associated with acute kidney injury and also with the development of nephrogenic systemic sclerosis in patients with stage 4 or 5 chronic kidney disease. Because of these risks, the FDA recommends avoiding gadolinium contrast in patients with a glomerular filtration rate < 30 mL/min/1.73 m², as well as in patients with acute renal failure. The risk of nephrogenic systemic sclerosis is not affected by blood pressure, medications, intravenous hydration, or pretreatment with n-acetylcysteine.

Ref: Rivera JA, O'Hare AM, Harper GM: Update on the management of chronic kidney disease. *Am Fam Physician* 2012;86(8):749-754.

Item 106**ANSWER: D**

Postpartum hemorrhage (PPH) is the cause of one-fourth of maternal deaths worldwide and 12% in the United States. It is defined as the loss of 1000 mL of blood or the loss of blood with coinciding signs and symptoms of hypovolemia within 24 hours after delivery. Twenty percent of PPH occurs in patients without risk factors, so methods to prevent this common problem should be in place with every delivery.

Active management of the third stage of labor (AMTSL) is crucial in the prevention of PPH. Administering oxytocin with or soon after the delivery of the anterior shoulder is the most important step of this process (SOR A). Even if oxytocin is used for induction, or as a part of AMTSL, it is still the most effective treatment for PPH (SOR A). Controlled cord traction is part of AMTSL and is necessary for the delivery of the placenta. If a retained placenta occurs it may be necessary to manually remove the placenta with necessary anesthesia. Trauma such as lacerations and episiotomies increases the risk of postpartum hemorrhage, so routine episiotomy should be avoided (SOR A).

Ref: American College of Obstetricians and Gynecologists: ACOG Practice Bulletin: Clinical management guidelines for obstetrician-gynecologists number 183, October 2017: Postpartum hemorrhage. *Obstet Gynecol* 2017;130(4):e168-e186.
2) Evensen A, Anderson JM, Fontaine P: Postpartum hemorrhage: Prevention and treatment. *Am Fam Physician* 2017;95(7):442-449.

Item 107

ANSWER: E

Pulseless ventricular tachycardia (VT) should be treated the same as ventricular fibrillation. The first step is defibrillation. If that is unsuccessful, epinephrine is administered and defibrillation is reattempted. Lidocaine, adenosine, and procainamide may be used for the initial treatment of a wide-complex tachycardia of uncertain type, but should not be used for the initial treatment of pulseless VT. Synchronized cardioversion alone would be indicated for the initial treatment of rapid unstable tachycardia with a pulse.

Ref: Link MS, Berkow LC, Kudenchuk PJ, et al: Part 7: Adult advanced cardiovascular life support: 2015 American Heart Association guidelines update for cardiopulmonary resuscitation and emergency cardiovascular care. *Circulation* 2015;132(18 Suppl 2):S444-S464. 2) Walls RM, Hockberger RS, Gausche-Hill M, et al (eds): *Rosen's Emergency Medicine: Concepts and Clinical Practice*, ed 9. Elsevier Inc, 2018, p 90.

Item 108

ANSWER: E

A Cochrane review found that the long-acting antimuscarinic agent tiotropium improved quality of life and reduced exacerbations and exacerbation-related hospitalizations in patients with underlying COPD. Tiotropium was noted to be superior to long-acting β -agonists such as salmeterol. Albuterol, fluticasone, and ipratropium have not been shown to have these effects (SOR A).

Ref: Chong J, Karner C, Poole P: Tiotropium versus long-acting β -agonists for stable chronic obstructive pulmonary disease. *Cochrane Database Syst Rev* 2012;(9):CD009157. 2) Karner C, Chong J, Poole P: Tiotropium versus placebo for chronic obstructive pulmonary disease. *Cochrane Database Syst Rev* 2014;(7):CD009285.

Item 109**ANSWER: A**

Mild asymptomatic elevations (<5 times the upper limit of normal) of ALT and AST are common in primary care. It is estimated that approximately 10% of the U.S. population has elevated transaminase levels. The most common causes of elevated transaminase levels are nonalcoholic fatty liver disease and alcoholic liver disease. The initial evaluation should include assessment for metabolic syndrome and insulin resistance. Waist circumference, blood pressure, a fasting lipid level, and a fasting glucose level or hemoglobin A_{1c} should be obtained. A CBC with platelets and measurement of serum albumin, iron, total iron-binding capacity, and ferritin levels would also be indicated. Iron studies should be ordered to rule out hereditary hemochromatosis, which is an autosomal recessive disease that causes increased iron absorption in the intestines and release by tissue macrophages.

Ref: Oh RC, Hustead TR, Ali SM, Pantsari MW: Mildly elevated liver transaminase levels: Causes and evaluation. *Am Fam Physician* 2017;96(11):709-715.

Item 110**ANSWER: C**

Until recently metformin was contraindicated for patients with renal dysfunction suggested by a creatinine level of 1.5 mg/dL for men and 1.4 mg/dL for women. However, available evidence now supports the use of metformin in individuals with mild to moderate chronic renal disease, defined by the estimated glomerular filtration rate (eGFR). Patients with an eGFR between 45 and 60 mL/min/1.73 m² (chronic mild kidney disease) are now permitted to take metformin. Metformin should not be used in patients with an eGFR <45 mL/min/1.73 m² (moderate kidney disease), as lactic acidosis is more likely to occur. The eGFR is used instead of the serum creatinine level because the equation includes age, sex, race, and other parameters.

Ref: 1) Inzucchi SE, Lipska KJ, Mayo H, et al: Metformin in patients with type 2 diabetes and kidney disease: A systematic review. *JAMA* 2014;312(24):2668-2675. 2) Lowes R, Nainggolan L: FDA: Metformin safe for some patients with renal problems. *Medscape*, 2016. 3) Choby B: Diabetes update: New pharmacotherapy for type 2 diabetes. *FP Essent* 2017;456:27-35.

Item 111**ANSWER: C**

Pain located between the myotendinous junction and the insertion of the Achilles tendon that occurs during prolonged walking or running is typical for midsubstance Achilles tendinopathy. The mechanisms resulting in pain are complex and not fully understood but inflammation is believed to contribute little to the process. This is evidenced in part by the ineffectiveness of treatments typically used to reduce inflammation such as NSAIDs and corticosteroids, which are not recommended in the treatment of this condition (SOR A). Other commonly used musculoskeletal therapeutic modalities such as immobilization, ultrasonography, orthotics, massage, and stretching exercises have not been shown to consistently offer significant benefits and are not considered to be first-line therapy for Achilles tendinopathy.

A gastrocnemius-strengthening eccentric exercise program performed in sets of controlled, slow, active release from weight-bearing full extension to full flexion of the foot at the ankle has been shown to reduce pain and improve function in the 60%–90% range, making this the logical first-line treatment for Achilles tendinopathy (SOR A).

The less common insertional Achilles tendinopathy localized to the enthesis is typically more recalcitrant, and immobilization in a walking boot for a period of time may be necessary before eccentric exercise can be tolerated.

Ref: Childress MA, Beutler A: Management of chronic tendon injuries. *Am Fam Physician* 2013;87(7):486-490.

Item 112

ANSWER: E

This patient has sarcoidosis that has been confirmed by a biopsy. He is symptomatic so treatment would be indicated. The recommended initial treatment for sarcoidosis is oral corticosteroids. Anti-infective agents are not appropriate treatment for sarcoidosis. Immunosuppressants are second- and third-line therapy for sarcoidosis and would not be recommended as first-line treatment.

Ref: Soto-Gomez N, Peters JI, Nambiar AM: Diagnosis and management of sarcoidosis. *Am Fam Physician* 2016;93(10):840-848.

Item 113

ANSWER: C

Psychological disorders, including anxiety, depression, and dysthymia, are frequently confused with premenstrual dysphoric disorder, and must be ruled out before initiating therapy. Symptoms are cyclic in true premenstrual dysphoric disorder. The most accurate way to make the diagnosis is to have the patient carefully record daily symptoms on a menstrual calendar for at least two cycles. Dysthymia consists of a pattern of ongoing, mild depressive symptoms that have been present for at least 2 years and are less severe than those of major depression, which is consistent with the findings in this case.

Ref: American Psychiatric Association: *Diagnostic and Statistical Manual of Mental Disorders*, ed 5. American Psychiatric Association, 2013, pp 372-379. 2) Hofmeister S, Bodden S: Premenstrual syndrome and premenstrual dysphoric disorder. *Am Fam Physician* 2016;94(3):236-240.

Item 114

ANSWER: D

Tdap is recommended for all women with each pregnancy, preferably between 27 and 36 weeks gestation. Live vaccines such as varicella and MMR are contraindicated during pregnancy. There is inadequate data to recommend vaccination against pneumococcal disease during pregnancy. Hepatitis B vaccine is recommended during pregnancy only for women at high risk for infection.

Ref: Omer SB: Maternal immunization. *N Engl J Med* 2017;376(13):1256-1267.

Item 115**ANSWER: B**

This patient has pseudofolliculitis barbae, which is a common condition affecting the face and neck in people with tightly curled hair. The condition occurs when hairs are cut at an angle and curl in on themselves, creating a foreign body reaction. The condition may progress to scarring and keloid formation. Cessation of hair removal improves the condition. If this is not desired, less aggressive hair trimming is recommended. Clippers generally result in a less close shave and contribute less to pseudofolliculitis barbae. Multi-blade razors, pulling the skin taut, and plucking hairs all result in shorter hair and are likely to exacerbate the problem. The description of the rash is not consistent with secondary infection, so oral cephalexin would not be indicated at this time. Treatment is similar to the treatment of acne, with benzoyl peroxide, topical retinoids, and topical antibiotics having a role, along with topical corticosteroids.

Ref: Kundu RV, Patterson S: Dermatologic conditions in skin of color: Part II. Disorders occurring predominately in skin of color. *Am Fam Physician* 2013;87(12):859-865.

Item 116**ANSWER: B**

This patient has severe asymptomatic hypertension (systolic blood pressure ≥ 180 mm Hg or diastolic blood pressure ≥ 110 mm Hg). If there were signs or symptoms of acute target organ injury, such as neurologic deficits, altered mental status, chest pain, shortness of breath, or oliguria, hospitalization for a hypertensive emergency would be indicated. Because this patient was asymptomatic and has a known history of hypertension, restarting his prior antihypertensive regimen and following up in 2 weeks would be the most appropriate management option. If he had no past history of hypertension it would be reasonable to consider out-of-office monitoring with an ambulatory device for 2 weeks before initiating treatment. In the absence of acute target organ injury, blood pressure should be gradually lowered to less than 160/100 mm Hg over several days to weeks. Aggressively lowering blood pressure can lead to adverse events such as myocardial infarction, cerebrovascular accident, or syncope, so administering a short-acting antihypertensive medication in the office should be reserved for the management of hypertensive emergencies.

Ref: Gauer R: Severe asymptomatic hypertension: Evaluation and treatment. *Am Fam Physician* 2017;95(8):492-500.

Item 117**ANSWER: D**

Relative energy deficiency in sport (RED-S), formerly known as the female athlete triad, is a relatively common condition in female athletes, and is characterized by amenorrhea, disordered eating, and osteoporosis. It is more common in sports that promote lean body mass. Female athletes should be screened for the disorder during their preparticipation evaluations. Individuals who present with one or more components of RED-S should be evaluated for the other components. This patient has a low BMI for her age, which indicates an eating disorder, and secondary amenorrhea, and should be screened for osteoporosis using a DXA scan. The International Society for Clinical Densitometry recommends using the Z-score, rather than the T-score, when screening children or premenopausal women. The T-score is based on a comparison to a young adult at peak bone density, whereas the Z-score uses a comparison to persons of the same age as the patient. A Z-score less than -2.0 indicates osteoporosis. The American College of Sports Medicine defines low bone density as a Z score of -1.0 to -2.0.

An EKG is not required in this patient since she has normal vital signs. Pelvic ultrasonography is not necessary unless an abnormal finding is identified on a pelvic examination. Abdominopelvic CT would be inappropriate given the patient's age and lack of abdominopelvic symptoms such as pain or a mass. A nuclear bone scan likewise is not recommended, as it is not used to diagnose osteoporosis (SOR C).

Ref: Joy EA, Van Hala S, Cooper L: Health-related concerns of the female athlete: A lifespan approach. *Am Fam Physician* 2009;79(6):489-495. 2) Mendelsohn FA, Warren MP: Anorexia, bulimia, and the female athlete triad: Evaluation and management. *Endocrinol Metab Clin North Am* 2010;39(1):155-167. 3) Javed A, Tebben PJ, Fischer PR, Lteif AN: Female athlete triad and its components: Toward improved screening and management. *Mayo Clin Proc* 2013;88(9):996-1009.

Item 118**ANSWER: A**

This patient presents with chronic olecranon bursitis. The diagnosis can be made from his history and the physical examination, and no additional workup is indicated at this time. Chronic bursitis is due to repetitive microtrauma, and the olecranon is the most common location. Patients typically have minimal pain, no history of injury, no systemic symptoms, and no signs of acute infection or inflammation. Treatment initially consists of avoiding recurrent trauma by protecting the area with an elbow pad and not leaning on it, as well as cryotherapy, compression of the affected area, and over-the-counter analgesics. If the lesion is inflamed or appears septic then laboratory testing should be performed, including a CBC with differential, a glucose level, an erythrocyte sedimentation rate, and a C-reactive protein level. Joint aspiration and/or ultrasonography may be indicated if the diagnosis is not apparent. A plain radiograph would be indicated to rule out a fracture in a patient with traumatic bursitis.

Ref: Khodae M: Common superficial bursitis. *Am Fam Physician* 2017;95(4):224-231.

Item 119**ANSWER: D**

Enoxaparin is the most appropriate pharmacologic therapy for anticoagulation in patients who are pregnant. Aspirin is not used as treatment for deep vein thrombosis. Apixaban, warfarin, and heparin either have not been studied for use in pregnancy or there is data indicating potential fetal harm.

Ref: Kearon C, Akl EA, Ornelas J, et al: Antithrombotic therapy for VTE disease: CHEST guideline and Expert Panel report. *Chest* 2016;149(2):315-352.

Item 120**ANSWER: C**

Melasma is a progressive, macular, nonscaling hypermelanosis of skin exposed to the sun, typically involving the face and dorsal forearms. It is often associated with pregnancy and the use of oral contraceptives or anticonvulsants (SOR C). Some melasma is idiopathic. Women are nine times more likely to be affected than men, and darker-skinned individuals are also at greater risk. There are three common patterns of melasma: centrofacial, malar, and mandibular.

Ref: Plensdorf S, Livieratos M, Dada N: Pigmentation disorders: Diagnosis and management. *Am Fam Physician* 2017;96(12):797-804.

Item 121**ANSWER: B**

This patient has signs of mild neurocognitive impairment. In this case one possible contributor to this condition is hypoglycemia. While it is unknown whether minor hypoglycemic events can contribute to dementia, major events have been associated with a greater risk of dementia. The sulfonylurea glyburide carries a risk of significant hypoglycemia, especially in elderly patients. Her hemoglobin A_{1c} of 6.1% correlates with an estimated average glucose of 128 mg/dL, corroborating this concern. Glyburide in particular is listed on the Beers Criteria because of its potential to cause prolonged hypoglycemia.

Ref: Whitmer RA, Karter AJ, Yaffe K, et al: Hypoglycemic episodes and risk of dementia in older patients with type 2 diabetes mellitus. *JAMA* 2009;301(15):1565-1572. 2) Erlich DR, Slawson DC, Shaughnessy AF: "Lending a hand" to patients with type 2 diabetes: A simple way to communicate treatment goals. *Am Fam Physician* 2014;89(4):256, 258. 3) American Geriatrics Society 2015 Beers Criteria Update Expert Panel: American Geriatrics Society 2015 updated Beers Criteria for potentially inappropriate medication use in older adults. *J Am Geriatr Soc* 2015;63(11):2227-2246.

Item 122**ANSWER: D**

For patients with left ventricular systolic dysfunction, clinical trials have demonstrated that ACE inhibitors, β -blockers, angiotensin receptor blockers, and aldosterone antagonists decrease hospitalizations and all-cause mortality. In African-American patients, all-cause mortality and hospitalizations have been reduced by hydralazine and isosorbide dinitrate.

Aldosterone antagonists such as spironolactone, as well as β -blockers, decrease mortality in patients with symptomatic heart failure (SOR A). Digoxin improves symptoms of heart failure but does not improve mortality.

Ref: Chavey WE, Hogikyan RV, Van Harrison R, Nicklas JM: Heart failure due to reduced ejection fraction: Medical management. *Am Fam Physician* 2017;95(1):13-20.

Item 123

ANSWER: A

Enoxaparin and other low molecular weight heparins are effective and are the preferred agents for acute and long-term anticoagulation in patients with an active malignancy (SOR B). Warfarin has been shown to be less effective in cancer patients and is not recommended to treat venous thromboembolic disease in this setting (SOR B). The novel oral anticoagulants including rivaroxaban have not been studied in the setting of malignancy and are not recommended.

Ref: Kearon C, Akl EA, Ornelas J, et al: Antithrombotic therapy for VTE disease: CHEST guideline and expert panel report. *Chest* 2016;149(2):315-352.

Item 124

ANSWER: B

A full history and physical examination are indicated for all refugees within 30 days of arrival in the United States, with a professional medical interpreter if needed (SOR C). In addition to addressing medical needs, the focus should be on emotional support and barriers to health care access (SOR C). All refugees should be screened for depression, anxiety, and posttraumatic stress disorder (SOR C). They should also be screened for anemia, hypertension, impaired fasting glucose, nutritional deficiencies, tuberculosis, and COPD (SOR C). If there is no vaccination documentation, routine vaccines should be provided except for varicella and hepatitis B. Serology should be performed before these vaccines are administered (SOR C).

Ref: Mishori R, Aleinikoff S, Davis D: Primary care for refugees: Challenges and opportunities. *Am Fam Physician* 2017;96(2):112-120.

Item 125

ANSWER: D

An AST (SGOT) to ALT (SGPT) ratio greater than 2:1 suggests alcoholic liver disease, and a ratio of 3:1 or higher is highly suggestive of alcoholic liver disease. With most hepatocellular disorders, including nonalcoholic fatty liver disease, viral hepatitis, and iron overload disorder, the patient will have an AST to ALT ratio < 1 .

Ref: Kasper DL, Fauci AS, Hauser SL, et al (eds): *Harrison's Principles of Internal Medicine*, ed 19. McGraw-Hill, 2015, p 1997.

Item 126**ANSWER: B**

This patient is a nonsmoker but has typical symptoms and findings of COPD. α_1 -Antitrypsin deficiency should be considered in patients with very premature COPD or in patients without risk factors for COPD such as smoking, secondhand smoke exposure, or other smoke exposure. Dyspnea would be present and lung function would be normal in patients with primary pulmonary hypertension or hypertrophic obstructive cardiomyopathy. Hemochromatosis may cause liver function abnormalities but not abnormal lung function. Allergic bronchopulmonary aspergillosis is associated with asthma, not COPD.

Ref: Gentry S, Gentry B: Chronic obstructive pulmonary disease: Disease and management. *Am Fam Physician* 2017;95(7):433-441.

Item 127**ANSWER: E**

Carpal tunnel syndrome is the most common entrapment neuropathy of the upper extremity. It is caused by compression of the median nerve as it travels through the carpal tunnel. Classically, patients with this condition experience pain and paresthesias in the distribution of the median nerve, which includes the palmar aspect of the thumb, index, and middle fingers, and the radial half of the ring finger. In more severe cases motor fibers are affected, leading to weakness of thumb abduction and opposition. Sensation over the thenar eminence should be normal in patients with carpal tunnel syndrome because it is in the distribution of the palmar cutaneous branch of the median nerve, which branches off proximal to the carpal tunnel.

Ref: Wiperman J, Goerl K: Carpal tunnel syndrome: Diagnosis and management. *Am Fam Physician* 2016;94(12):993-999.

Item 128**ANSWER: E**

Perioperative management of chronic anticoagulation requires an assessment of the patient's risk for thromboembolism and the risk of bleeding from the surgical procedure. High-risk patients include those with mechanical heart valves, a stroke or TIA within the past 3 months, venous thromboembolism within the past 3 months, or coronary stenting within the previous 12 months. High-risk patients require bridging therapy with low molecular weight heparin, while patients at low risk do not require bridging anticoagulation. For low-risk patients, it is recommended that warfarin be discontinued 5 days prior to surgery and restarted 12–24 hours postoperatively. This patient is at low risk for thromboembolism because her CHA₂DS₂-VASc score is 3. A patient with atrial fibrillation should receive bridging therapy with a CHA₂DS₂-VASc score ≥ 6 . This patient's surgery is associated with a high risk for bleeding, so it is preferable to stop her warfarin 5 days before the operation.

Ref: Douketis JD, Spyropoulos AC, Spencer FA, et al: Perioperative management of antithrombotic therapy: Antithrombotic therapy and prevention of thrombosis, 9th ed: American College of Chest Physicians evidence-based clinical practice guidelines. *Chest* 2012;141(2 Suppl):e326S-e350S. 2) January CT, Wann LS, Alpert JS, et al: 2014 AHA/ACC/HRS guideline for the management of patients with atrial fibrillation: A report of the American College of Cardiology/American Heart Association Task Force on Practice Guidelines and the Heart Rhythm Society. *J Am Coll Cardiol* 2014;64(21):e1-e76.

Item 129**ANSWER: D**

Solid but not liquid dysphagia suggests a structural lesion. A location in the chest indicates esophageal dysphagia. Endoscopy is the single most useful test for esophageal dysphagia and can visualize mucosal lesions better than barium radiography. Therapy can also be performed during the procedure. A fluoroscopic swallowing study would be indicated if the patient's history pointed to oral or pharyngeal dysphagia. Even if it is thought that the dysphagia is caused by a motility disorder, endoscopy is still preferred, because neoplastic and inflammatory conditions can produce spasm and motility symptoms. Manometry can be performed if endoscopy does not adequately explain the symptoms.

Ref: Kasper DL, Fauci AS, Hauser SL, et al (eds): *Harrison's Principles of Internal Medicine*, ed 19. McGraw-Hill, 2015, pp 254-258.

Item 130**ANSWER: A**

This patient most likely has Henoch-Schönlein purpura. In addition to close observation, the only treatment is supportive care, including adequate oral hydration. There is no indication for antibiotics, and oral corticosteroids have not been shown to be beneficial. In patients with progressive renal impairment, referral to a nephrologist is warranted, but given this patient's normal renal function at this time it is not indicated. A skin biopsy of the purpura would most likely show a leukocytoclastic vasculitis and would not help in the diagnosis.

Ref: Trnka P: Henoch-Schönlein purpura in children. *J Paediatr Child Health* 2013;49(12):995-1003.

Item 131**ANSWER: C**

This patient has symptoms consistent with croup, a lower respiratory infection that is common in the winter months in children ages 6 months to 3 years. The diagnosis is clinical and should be suspected in children with a history of a sudden onset of a deep cough, hoarseness, and a low-grade fever. Randomized studies have shown that even with mild croup (an occasional barking cough with no stridor at rest), oral corticosteroids provide some benefit.

A Cochrane review of two randomized trials with a total of 2024 patients found that chest radiographs did not change the outcome of ambulatory children with lower respiratory tract infections. A patient such as this would not need antiviral treatment for influenza.

Ref: Bjornson CL, Johnson DW: Croup in children. *CMAJ* 2013;185(15):1317-323. 2) Smith DK, McDermott AJ, Sullivan JF: Croup: Diagnosis and management. *Am Fam Physician* 2018;97(9):575-580.

Item 132**ANSWER: B**

Hypoxemia following an acute illness is often short-lived and as many as half the patients prescribed home oxygen on discharge from the hospital will not meet criteria supporting continuation after 3 months. For this group of patients there is no apparent benefit derived from supplemental oxygen once their oxygen saturation is 88 % or greater on room air. Potential harmful effects of continuing unnecessary home oxygen include decreased mobility, falls, house fires, and mucosal irritation, and oxygen toxicity must be considered as well. Continuing home oxygen beyond what is needed also results in a misallocation of resources. According to the American Thoracic Society and the American College of Chest Physicians, prescriptions for supplemental home oxygen should not be renewed for patients who have recently been hospitalized for acute illnesses without assessing them for ongoing hypoxemia.

Ref: Wiener RS, Ouellette DR, Diamond E, et al: An official American Thoracic Society/American College of Chest Physicians policy statement: The Choosing Wisely top five list in adult pulmonary medicine. *Chest* 2014;145(6):1383-1391.

Item 133**ANSWER: B**

In a double-blind randomized trial, letrozole was associated with greater live-birth and ovulation rates compared to clomiphene (SOR A). A Cochrane review indicated that metformin does not increase fertility in patients diagnosed with polycystic ovary syndrome (PCOS). Spironolactone and finasteride are both used to treat PCOS in women who do not desire pregnancy.

Ref: Legro RS, Brzyski RG, Diamond MP, et al: Letrozole versus clomiphene for infertility in the polycystic ovarian syndrome. *N Engl J Med* 2014;371(2):119-129. 2) Williams T, Mortada R, Porter S: Diagnosis and treatment of polycystic ovary syndrome. *Am Fam Physician* 2016;94(2):106-113.

Item 134**ANSWER: E**

This patient's age, risk factors, red-flag symptoms, and other clinical findings indicate the need for endoscopy. The Leser-Trélat sign may be defined as the abrupt onset of multiple seborrheic keratoses, which is an unusual finding that often indicates an underlying malignancy, most commonly an adenocarcinoma of the stomach. CT is not an initial approach for diagnosing a suspected malignancy of the stomach or colon. Further skin evaluation and lifestyle changes, which are indicated, will not address the need for evaluation of weight loss and other abnormal symptoms and findings.

Ref: Higgins JC, Maher MH, Douglas MS: Diagnosing common benign skin tumors. *Am Fam Physician* 2015;92(7):601-607. 2) Bennett CN, Schmieder GJ: Leser Trelat sign. StatPearls Publishing, 2017.

Item 135**ANSWER: C**

The treatment of Rocky Mountain spotted fever (RMSF) must be started as soon as the diagnosis is suspected in order to decrease mortality. Doxycycline is the only approved therapy for RMSF for individuals of all ages, including children < 8 years of age. Of the other options listed, only rifampin and chloramphenicol have been used for the treatment of RMSF, but they are not FDA approved.

Providing supportive care or waiting for confirmation of the diagnosis would not be appropriate. Laboratory tests such as a CBC and chemistries can be helpful in looking for other causes of a patient's symptoms but findings will not be specific for RMSF. Serologies may be helpful but are not available immediately and may be negative early in the disease process.

Ref: Biggs HM, Behravesh CB, Bradley KK, et al: Diagnosis and management of tickborne rickettsial diseases: Rocky Mountain spotted fever and other spotted fever group rickettsioses, ehrlichioses, and anaplasmosis—United States. *MMWR Recomm Rep* 2016;65(2):1-44.

Item 136**ANSWER: B**

Metformin should be used as first-line therapy in type 2 diabetes to reduce microvascular complications, assist in weight management, reduce the risk of cardiovascular events, and reduce the risk of mortality in patients (SOR A). Patients who are intolerant of metformin are unlikely to be successful with a third trial of that agent. Empagliflozin, an SGLT2 inhibitor, is considered a second-line choice for patients who are intolerant of metformin. Both sitagliptin, a DPP-4 inhibitor, and liraglutide, a GLP-1 receptor agonist, should be avoided or used with caution in patients with a history of pancreatitis.

Ref: George CM, Brujin LL, Will K, Howard-Thompson A: Management of blood glucose with noninsulin therapies in type 2 diabetes. *Am Fam Physician* 2015;92(1):27-34. 2) Reusch JE, Manson JE: Management of type 2 diabetes in 2017: Getting to goal. *JAMA* 2017;317(10):1015-1016. 3) Gomez-Peralta F, Abreu C, Lecube A, et al: Practical approach to initiating SGLT2 inhibitors in type 2 diabetes. *Diabetes Ther* 2017;8(5):953-962.

Item 137**ANSWER: E**

Head lice is a relatively common infestation in school-aged children and adolescents, but it is often unnecessarily feared and affected children are stigmatized. Since transmission rates are relatively low in the classroom setting and treatments can be expensive and difficult, children suspected of having head lice should remain in class and should not be treated unless there is a clear diagnosis. Nits are louse eggs and do not necessarily represent an active, infectious case of head lice. Children's privacy should be respected appropriately, and in most cases there is no need to notify an entire class or school of the presence of a case of lice.

Ref: Devore CD, Schutze GE; Council on School Health and Committee on Infectious Diseases, American Academy of Pediatrics: Head lice. *Pediatrics* 2015;135(5):e1355-e1365.

Item 138**ANSWER: C**

Several factors can alter the hemoglobin A_{1c} value, including variability and erythrocyte lifespan. When the mean erythrocyte lifespan is increased by a condition such as asplenia, hemoglobin A_{1c} increases because of increased RBC exposure time for glycation. Conversely, when the mean erythrocyte lifespan is decreased by conditions such as hemolytic anemia, hemoglobin A_{1c} is decreased because of reduced RBC exposure time for glycation. Conditions that decrease erythropoiesis, such as iron deficiency anemia, increase the mean age of the RBC, thereby increasing hemoglobin A_{1c}. Severe chronic kidney disease may increase RBC glycation through lipid peroxidase of hemoglobin and by extending the erythrocyte lifespan due to decreased erythropoietin levels, causing a false elevation of hemoglobin A_{1c}. Vitamin B₁₂ deficiency also decreases erythropoiesis and leads to falsely elevated hemoglobin A_{1c}.

Ref: O'Keeffe DT, Maraka S, Rizza RA: HbA_{1c} in the evaluation of diabetes mellitus. *JAMA* 2016;315(6):605-606.

Item 139**ANSWER: C**

Lithium is a drug with a narrow therapeutic index and a low volume of distribution. Elderly patients are more likely to develop lithium toxicity due to their lower muscle mass and age-related decreased glomerular filtration rate (GFR). Chronic toxicity is more common than acute toxicity and is often precipitated by events causing volume depletion, such as vomiting, diarrhea, and acute gastroenteritis. Drugs that impact renal function or volume status, such as ACE inhibitors, NSAIDs, and diuretics, can also precipitate toxicity. Chronic toxicity often presents with signs and symptoms related to the gastrointestinal tract (nausea, vomiting, and diarrhea, which can further worsen toxicity), heart (arrhythmias and conduction delays), and central nervous system (coarse tremors, ataxia, agitation, and confusion). Albuterol and tiotropium both cause transient tremors and tachycardia, but are not associated with ataxia. Atenolol is associated with bradycardia, but not tremors or ataxia (SOR B).

Ref: Katzung B, Masters S, Trevor A: *Basic and Clinical Pharmacology*, ed 11. The McGraw-Hill Companies Inc, 2009, pp 487-508. 2) Kasper DL, Fauci AS, Hauser SL, et al (eds): *Harrison's Principles of Internal Medicine*, ed 19. McGraw-Hill, 2015, p 2718.

Item 140**ANSWER: E**

A 5-day course of antibiotics for community-acquired pneumonia produces the same clinical success rates as longer treatment programs. There is no difference in the rate of clinical improvement, hospital readmissions, or mortality between longer or shorter treatment courses. Patients are often discharged from the hospital before significant clinical improvement occurs, leading both patients and physicians to believe that longer antibiotic courses must be prescribed. Physicians must educate their patients about the benefit of shorter antibiotic courses, including fewer adverse effects, lower cost, and lower rates of bacterial resistance.

Ref: Uranga A, España PP, Bilbao A, et al: Duration of antibiotic treatment in community-acquired pneumonia: A multicenter randomized clinical trial. *JAMA Intern Med* 2016;176(9):1257-1265.

Item 141**ANSWER: C**

This patient has intermittent asthma that has become at least moderate persistent as defined by the frequency of her symptoms. The National Asthma Education and Prevention guidelines recommend a moderate-dose inhaled corticosteroid (ICS) with a long-acting bronchodilator as the preferred treatment in moderate persistent asthma. Fluticasone/salmeterol at a dosage of 250/50 µg is the only option that fits this category. Montelukast alone is an alternative treatment for mild persistent asthma (SOR A).

Ref: McCracken JL, Veeranki SP, Ameredes BT, Calhoun WJ: Diagnosis and management of asthma in adults: A review. *JAMA* 2017;318(3):279-290.

Item 142**ANSWER: A**

Newborns with sepsis may have focal signs of infection such as pneumonia or respiratory distress syndrome, but they also may have nonfocal signs and symptoms. In the newborn period the two most common causes of neonatal sepsis are group B *Streptococcus* and *Escherichia coli*. *Listeria monocytogenes* was once a more common cause but it is now uncommon. Streptococcal pneumonia is an uncommon cause of sepsis in neonates. *Staphylococcus aureus* and group A *Streptococcus* are not as common but should be considered in newborns with cellulitis.

Ref: Polin RA, Watterberg K, Benitz W, Eichenwald E: The conundrum of early-onset sepsis. *Pediatrics* 2014;133(6):1122-1123. 2) Hay WW Jr, Levin MJ, Deterding RR, Abzug MJ: *Current Diagnosis & Treatment: Pediatrics*, ed 23. McGraw-Hill Education, 2016, pp 1150-1169.

Item 143**ANSWER: D**

The U.S. Preventive Services Task Force (USPSTF) recommends screening for major depressive disorder (MDD) in adolescents 12–18 years of age. Screening should be implemented with systems in place to ensure adequate diagnosis, effective treatment, and appropriate follow-up (B recommendation). The USPSTF found adequate evidence that screening instruments for depression in adolescents can accurately identify MDD in this age group in primary care settings, and that the treatment of MDD detected through screening in this age group is associated with moderate benefits. Based on current evidence, the USPSTF also concluded that the evidence is insufficient to assess the balance of benefits and harms from screening for MDD in children 11 years of age and younger.

Ref: *Final Recommendation Statement: Depression in Children and Adolescents: Screening*. US Preventive Services Task Force, 2016.

Item 144**ANSWER: D**

Although tinnitus is idiopathic, sensorineural hearing loss is the most common identified cause. It can also be caused by other otologic, vascular, neoplastic, neurologic, pharmacologic, dental, and psychological factors. Almost all patients with tinnitus should undergo audiometry with tympanometry, and some patients require neuroimaging or assessment of vestibular function with electronystagmography. Counseling may also improve the chances of successful subsequent treatment. Several medications can cause tinnitus, but allopurinol is not one of them.

Ref: Yew KS: Diagnostic approach to patients with tinnitus. *Am Fam Physician* 2014;89(2):106-113.

Item 145**ANSWER: D**

Penile lesions are usually easily diagnosed from clinical findings. Pearly penile papules are common and benign, and present as small, skin-colored, dome-shaped papules in a circular pattern around the coronal sulcus.

Lichen nitidus is benign but uncommon. It presents as discrete, pinhead-sized hypopigmented papules that are asymptomatic. Papules are often found scattered all over the penis, as well as on the abdomen and upper extremities.

Lichen sclerosus is more common and appears as hypopigmented lesions with the texture of cellophane. The lesions are usually located on the glans or prepuce. Atrophy, erosions, and bullae are common, and patients often present with itching, pain, bleeding, and possibly phimosis or obstructed voiding. Lichen sclerosus is associated with squamous cell cancer in a small percentage of cases.

Carcinoma in situ is a premalignant condition that is more common in uncircumcised males over age 60. Lesions are typically beefy red, raised, irregular plaques and can be found on the glans, meatus, frenulum, coronal sulcus, and prepuce. Lesions can be ulcerated or crusted. Pruritus and pain are common. A biopsy is important for making the diagnosis.

Angiokeratomas are lesions that are usually asymptomatic, circumscribed, red or bluish papules. They may appear solely on the glans of the penis, but are also found on the scrotum, abdomen, thighs, groin, and extremities. They may be misdiagnosed as pearly papules or carcinoma. Treatment is not necessary unless the lesions are bleeding or extensive. It is important to realize that angiokeratomas on the shaft of the penis, the suprapubic region, or the sacral region can be associated with Fabry disease. Patients with this finding should be promptly referred.

Ref: Buechner SA: Common skin disorders of the penis. *BJU Int* 2002;90(5):498-506. 2) Teichman JM, Sea J, Thompson IM, Elston DM: Noninfectious penile lesions. *Am Fam Physician* 2010;81(2):167-174. 3) Habif TP: *Clinical Dermatology: A Color Guide to Diagnosis and Therapy*, ed 6. Elsevier, 2016, p 914.

Item 146**ANSWER: A**

Amitriptyline may reduce headache duration and severity compared with placebo for chronic tension-type headaches (SOR B). SSRIs have no proven benefit for headache prophylaxis over placebo or tricyclic antidepressants in patients with chronic daily headaches. Propranolol reduces the frequency of migraine headaches, although its effectiveness for chronic migraine is unclear. Propranolol is not effective for tension headaches. Topiramate can reduce the frequency of chronic migraine headaches by 50% but is not effective for tension-type headaches. OnabotulinumtoxinA has been shown to reduce headache frequency in chronic migraine, but evidence of its effectiveness is lacking for chronic tension-type headaches.

Ref: Yancey JR, Sheridan R, Koren KG: Chronic daily headache: Diagnosis and management. *Am Fam Physician* 2014;89(8):642-648.

Item 147**ANSWER: D**

Pregabalin is considered first-line therapy for painful diabetic peripheral neuropathy (SOR A). Based on a meta-analysis, the American Academy of Neurology recommends pregabalin as first-line medication and gabapentin as a first-line alternative. While opioids such as oxycodone may provide a possible benefit in the treatment of neuropathy, the risk of dependency and adverse effects limits their use to patients with pain not relieved by first-line therapies. Acupuncture is not recommended as a first-line therapy due to the lack of high-quality, randomized, controlled trials. Venlafaxine and lidocaine 5% spray are considered second-line therapies.

Ref: Snyder MJ, Gibbs LM, Lindsay TJ: Treating painful diabetic peripheral neuropathy: An update. *Am Fam Physician* 2016;94(3):227-234.

Item 148**ANSWER: E**

This patient has alopecia areata, which is a chronic, relapsing, immune-mediated inflammatory disorder affecting hair follicles that results in patchy hair loss. The treatment of choice is intralesional corticosteroid injections. Topical immunotherapy is reserved for patients with extensive disease, such as >50% scalp involvement. Topical corticosteroids are less effective and are usually reserved for children and adults who cannot tolerate intralesional injections. Minoxidil is used for androgenetic alopecia and is less effective for alopecia areata. Oral antifungal drugs are used to treat tinea capitis.

Ref: Phillips TG, Slomiany WP, Allison R: Hair loss: Common causes and treatment. *Am Fam Physician* 2017;96(6):371-378.

Item 149**ANSWER: E**

The Surviving Sepsis Campaign recommends that patients with elevated serum lactate or hypotension receive isotonic intravenous fluids such as normal saline or lactated Ringer's solution at an initial rate of 30 mL/kg in the first 3 hours using small boluses of approximately 500 mL. A serum lactate value >36 g/dL (4 mmol/L) is correlated with increased severity of illness and poorer outcomes even if hypotension is not yet present. Patients who are hypotensive or whose serum lactate level is >36 g/dL require intravenous fluids or colloid to expand their circulating volume and effectively restore perfusion pressure. The administration of 30 mL/kg of fluid is recommended as a fluid challenge, which should be started as early as possible in the course of septic shock.

Ref: Rhodes A, Evans LE, Alhazzani W, et al: Surviving Sepsis Campaign: International guidelines for management of sepsis and septic shock: 2016. *Crit Care Med* 2017;45(3):486-552.

Item 150**ANSWER: D**

MRI of the breasts should be reserved for women at very high risk for breast cancer such as those with genetic mutations, a history of breast irradiation, or a very high-risk family history. Women who had chest radiation therapy during childhood or adolescence, generally for Hodgkin's disease, are at an extremely high risk for breast cancer.

Ref: Nattinger AB, Mitchell JL: Breast cancer screening and prevention. *Ann Intern Med* 2016;164(11):ITC81-ITC96.

Item 151**ANSWER: D**

A recent office-based, randomized, controlled trial demonstrated that over 40% of parents made dosing errors with medicine cups compared to a 17% error rate with an oral syringe. Oral syringes are marked with milliliters, not cubic centimeters, so dosages should use milliliters. Tableware varies in volume and should not be used. Medication bottles are not marked for measuring dosing volumes. Discharge instructions are important, but a written copy of this prescription will not help the guardian measure to the nearest milliliter.

Ref: Yin HS, Parker RM, Sanders LM, et al: Liquid medication errors and dosing tools: A randomized controlled experiment. *Pediatrics* 2016;138(4):e20160357. 2) Ebell MH, Grad R: Top 20 research studies of 2016 for primary care physicians. *Am Fam Physician* 2017;95(9):572-579.

Item 152**ANSWER: B**

This patient has celiac disease with both intestinal and extraintestinal manifestations (diarrhea and dermatitis herpetiformis, respectively). Iron deficiency anemia due to chronic blood loss is a common finding in patients with celiac disease.

Eczema herpeticum is the appearance of a herpetic infection complicating eczema. This is a serious acute problem that can be life-threatening in severe cases. Lichen simplex chronicus is a chronic skin condition that is perpetuated by scratching. Lesions are commonly thickened and excoriated. Diarrhea and anemia are not associated with this disorder. While eczema is possible based on the description of the rash, the intestinal manifestations and positive tissue transglutaminase antibody in this patient point to celiac disease. This patient's rash does not suggest cutaneous lupus, which is also unlikely given the negative antinuclear antibody test.

Ref: Pelkowski TD, Viera AJ: Celiac disease: Diagnosis and management. *Am Fam Physician* 2014;89(2):99-105.

Item 153**ANSWER: B**

With a history of major depression and mania, this patient would be classified as having bipolar I disorder. SSRIs can be used to treat major depression in these patients, but they are insufficient as monotherapy for controlling or preventing mania. They may even precipitate a manic episode in patients with bipolar I disorder and are contraindicated as monotherapy for these patients (SOR B). Patients with bipolar I disorder are sometimes treated with a combination of antidepressants such as an SSRI, plus a mood stabilizer, which includes anticonvulsants (lamotrigine, divalproex), atypical antipsychotics (quetiapine), or lithium, but this is considered second-line therapy. All of these mood stabilizers are effective in the treatment and prevention of mania. The use of these medications in combination with psychotherapy generally provides the best results in patients with bipolar I disorder.

Ref: Bobo WV: The diagnosis and management of bipolar I and II disorders: Clinical practice update. *Mayo Clin Proc* 2017;92(10):1532-1551.

Item 154**ANSWER: A**

Allergic bronchopulmonary aspergillosis (ABPA) affects 1%–12% of immunocompetent patients with asthma and is important to consider in patients with recurrent exacerbations because it can cause permanent lung damage if it is undetected and untreated. The symptoms alone are insufficient for a diagnosis, but this clinical presentation should prompt consideration of the diagnosis, and some of the symptoms and findings noted are included in the diagnostic criteria. The major diagnostic criteria include the presence of asthma or cystic fibrosis and immediate skin reactivity to *Aspergillus* antigens, peripheral eosinophilia, transient pulmonary infiltrates or opacities, central bronchiectasis on a chest radiograph or CT, serum precipitating antibodies to *Aspergillus fumigatus*, and elevated *Aspergillus* IgE- and/or IgG-specific antibodies.

Minor criteria that support the diagnosis include production of brownish mucus plugs, identification of *Aspergillus* in the sputum, and delayed skin sensitivity to *Aspergillus*. Pneumonia is unlikely in this case given recent treatment with a respiratory fluoroquinolone and a lack of common symptoms such as fever, chills, tachycardia, tachypnea, and pleuritic chest pain, along with a cough productive of mucopurulent sputum. The most common symptoms of pulmonary embolism include dyspnea, chest pain, syncope, tachypnea, and a cough. While medication nonadherence may increase asthma exacerbations and wheezing, it would be unlikely to be related to the new brown mucus production.

Ref: Watkins RR, Lemonovich TL: Diagnosis and management of community-acquired pneumonia in adults. *Am Fam Physician* 2011;83(11):1299-1306. 2) Wilbur J, Shian B: Diagnosis of deep venous thrombosis and pulmonary embolism. *Am Fam Physician* 2012;86(10):913-919. 3) Greenberger PA, Bush RK, Demain JG, et al: Allergic bronchopulmonary aspergillosis. *J Allergy Clin Immunol Pract* 2014;2(6):703-708. 4) Mouthon L, Dunogue B, Guillemin L: Diagnosis and classification of eosinophilic granulomatosis with polyangiitis (formerly named Churg-Strauss syndrome). *J Autoimmun* 2014;48-49:99-103.

Item 155

ANSWER: D

Takotsubo cardiomyopathy (TTC) is also known as apical ballooning syndrome and stress-induced cardiomyopathy. It generally occurs in postmenopausal women with a mean age of 62–76 years. The clinical presentation is similar to that of acute coronary syndrome. Evaluation with an EKG, cardiac biomarkers, and imaging is needed to differentiate between these two conditions. This patient presents with classic apical and midsegment left ventricular hypokinesis, or apical ballooning, and a new T-wave inversion with modest elevations in cardiac troponin. While she has an identifiable characteristic emotional stressor, up to one-third of patients with TTC do not have an identifiable stressor.

In this scenario, a negative myocardial perfusion scan makes coronary artery disease or acute coronary syndrome unlikely. Patients with viral myocarditis typically present with fever, myalgia, and signs and symptoms of heart failure following a viral syndrome. Cardiac amyloidosis is a restrictive cardiomyopathy that is typically associated with thickened walls of both ventricles and markedly dilated atria. Patients with acute pericarditis present with chest pain, a pericardial friction rub on examination, an ST-segment elevation on EKG, and a pericardial effusion on echocardiography.

Ref: Scantlebury DC, Prasad A: Diagnosis of Takotsubo cardiomyopathy. *Circ J* 2014;78(9):2129-2139. 2) Kasper DL, Fauci AS, Hauser SL, et al (eds): *Harrison's Principles of Internal Medicine*, ed 19. McGraw-Hill, 2015, pp 1553-1577.

Item 156

ANSWER: C

According to the CDC, the leading causes of cancer death in men from 2011–2015 were lung cancer (53.8 deaths per 100,000 per year), prostate cancer (19.5 deaths per 100,000 per year), colorectal cancer (17.3 deaths per 100,000 per year), and pancreatic cancer (12.6 deaths per 100,000 per year).

Ref: US Cancer Statistics Working Group: US cancer statistics data visualization tool, based on November 2017 submission data (1999–2015). Centers for Disease Control and Prevention and National Cancer Institute, 2018.

Item 157

ANSWER: A

Clonidine (0.1–0.3 mg every 6–8 hours) is a useful adjunct to buprenorphine in the treatment of opioid use disorder to help increase the rates of abstinence and decrease stress-related opioid cravings (SOR C). Naloxone is an opioid antagonist used to treat overdoses. Nifedipine is a common antihypertensive like clonidine but it has no role in the treatment of opioid use disorder. Methadone and naltrexone are used to treat opioid use disorder but neither of these agents would be used simultaneously with buprenorphine.

Ref: Zoorob R, Kowalchuk A, Mejia de Grubb M: Buprenorphine therapy for opioid use disorder. *Am Fam Physician* 2018;97(5):313-320.

Item 158

ANSWER: B

For children with a fever without localizing signs, management depends on the child's age and findings on examination. For children 3–36 months of age with a fever $\leq 39^{\circ}\text{C}$ (102°F), reassurance that this is likely a self-limited viral infection is appropriate, with instructions to return if there are new signs or symptoms. If the temperature is $> 39^{\circ}$ and the child has received appropriate vaccines on schedule, then a urinalysis and culture should be performed for all children < 6 months of age and for uncircumcised boys < 2 years of age. A more extensive workup would be appropriate for children < 3 months of age.

Ref: Kliegman RM, Stanton BF, Geme JW III, et al (eds): *Nelson Textbook of Pediatrics*, ed 20. Elsevier Saunders, 2016, pp 1280-1283.

Item 159

ANSWER: E

The core elements of antibiotic stewardship are commitment, action for policy and practice, tracking and reporting, and education and expertise. Delayed prescription strategies for appropriate conditions such as upper respiratory infections and otitis media are effective in reducing antibiotic use. Using evidence-based guidelines, clinical support tools, and triage systems also results in decreased antibiotic use. Using call centers or nurse triage reduces unnecessary visits, and nurses can effectively manage upper respiratory infection symptoms via phone consultations.

Ref: Sanchez GV, Fleming-Dutra KE, Roberts RM, Hicks LA: Core elements of outpatient antibiotic stewardship. *MMWR Recomm Rep* 2016;65(6):1-12.

Item 160**ANSWER: A**

The presence of RBC casts on microscopic examination of fresh spun urine sediment indicates acute glomerulonephritis, which may be due to a variety of immunologic, infectious, or postinfectious causes, with the classic example being poststreptococcal glomerulonephritis. Many cases of acute glomerulonephritis require renal biopsies for definitive diagnosis and treatment. Acute pyelonephritis causes bacteriuria, pyuria, and possibly WBC casts. Acute tubular necrosis is usually associated with hypotension, acute blood loss, sepsis, or rhabdomyolysis, and there may be granular or epithelial casts in the urine sediment, but not RBC casts. Acute papillary necrosis is the result of medullary (not cortical) renal injury, and although gross hematuria may be present, there are no RBC casts. Nephrotic syndrome is not associated with hematuria but rather with massive proteinuria (>3.5 g/24 hr).

Ref: Kasper DL, Fauci AS, Hauser SL, et al (eds): *Harrison's Principles of Internal Medicine*, ed 19. McGraw-Hill, 2015, pp 289, 294, 1834-1836.

Item 161**ANSWER: C**

Mallet finger, an injury to the distal extensor tendon of the finger at the distal interphalangeal (DIP) joint, is usually caused by forceful flexion of an extended DIP joint. This is frequently the result of being struck by an object such as a ball. The inability to actively extend the DIP joint is a hallmark of mallet finger. The inability to passively extend the DIP joint completely may be an indication of trapped soft tissue or bone that may require surgery. Up to one-third of distal extensor tendon injuries are associated with an avulsion fracture, and if the avulsion is greater than 30% of the joint space, referral to an orthopedist is recommended. Splinting with strict use of the splint and avoidance of any flexion of the DIP joint is the recommended treatment, and is beneficial even with a delayed presentation. Athletic activities may be continued with the splint in place.

Ref: Leggit JC, Meko CJ: Acute finger injuries: Part I. Tendons and ligaments. *Am Fam Physician* 2006;73(5):810-816. 2) Daniels JM, DeCastro A, Stanton RN: Finger injuries: 5 cases to test your skills. *J Fam Pract* 2013;62(6):300-304.

Item 162**ANSWER: C**

NSAIDs such as ibuprofen should be used as first-line treatment for the control of pleuritic pain (SOR B). While NSAIDs do not have the analgesic potency of narcotics, they do not cause respiratory suppression or change the patient's sensorium. Corticosteroids should be reserved for patients who cannot take NSAIDs.

Ref: Reamy BV, Williams PM, Odom MR: Pleuritic chest pain: Sorting through the differential diagnosis. *Am Fam Physician* 2017;96(5):306-312.

Item 163**ANSWER: B**

Patients with drug-eluting stents should be on dual antiplatelet therapy with aspirin plus a thienopyridine such as clopidogrel for a minimum of 1 year. At the time of this patient's visit, 2 years after the stent placement, there is no indication to continue clopidogrel, but aspirin therapy should be continued indefinitely. All of the patient's other medications have current active indications and should be continued, although if the patient experiences hypoglycemia, the sulfonylurea could be decreased or discontinued.

Ref: Levine GN, Bates ER, Bittl JA, et al: 2016 ACC/AHA guideline focused update on duration of dual antiplatelet therapy in patients with coronary artery disease: A report of the American College of Cardiology/American Heart Association Task Force on Clinical Practice Guidelines: An update of the 2011 ACCF/AHA/SCAI guideline for percutaneous coronary intervention, 2011 ACCF/AHA guideline for coronary artery bypass graft surgery, 2012 ACC/AHA/ACP/AATS/PCNA/SCAI/STS guideline for the diagnosis and management of patients with stable ischemic heart disease, 2013 ACCF/AHA guideline for the management of ST-elevation myocardial infarction, 2014 AHA/ACC guideline for the management of patients with non-ST-elevation acute coronary syndromes, and 2014 ACC/AHA guideline on perioperative cardiovascular evaluation and management of patients undergoing noncardiac surgery. *Circulation* 2016;134(10):e123-155.

Item 164**ANSWER: B**

Both 13-valent pneumococcal conjugate vaccine (PCV13) and 23-valent pneumococcal polysaccharide vaccine (PPSV23) are recommended for patients with chronic renal failure. Indications for PPSV23 alone in immunocompetent persons younger than 65 include chronic lung disease, diabetes mellitus, chronic heart disease, smoking, and alcoholism.

Ref: Kobayashi M, Bennett NM, Gierke R, et al: Intervals between PCV13 and PPSV23 vaccines: Recommendations of the Advisory Committee on Immunization Practices (ACIP). *MMWR Morb Mortal Wkly Rep* 2015;64(34):944-947.

Item 165**ANSWER: D**

Early recognition and effective treatment of acute Bell's palsy (idiopathic facial paralysis) has been shown to decrease the risk of chronic partial paralysis and pain. Corticosteroids have been shown in a meta-analysis to decrease chronic symptoms, but a Cochrane meta-analysis of 10 studies concluded that antiviral medication along with corticosteroids is significantly more effective than corticosteroids alone. The medications are most effective if started within 72 hours of symptom onset. The same analysis showed that antiviral medications alone were less effective than corticosteroids alone. This patient's presentation is not consistent with stroke or another emergency. Because supranuclear input to the facial nerves comes from both cerebral hemispheres, strokes and other central pathologies affecting the facial nerves typically spare the forehead, which is not the case in this patient.

Ref: Baugh RF, Basura GJ, Ishii LE, et al: Clinical practice guideline: Bell's palsy executive summary. *Otolaryngol Head Neck Surg* 2013;149(5):656-663. 2) Gagyor I, Madhok VB, Daly F, et al: Antiviral treatment for Bell's palsy (idiopathic facial paralysis). *Cochrane Database Syst Rev* 2015;(11):CD001869.

Item 166**ANSWER: B**

25-Hydroxyvitamin D levels should not be measured in patients presenting with fatigue (SOR A). A serum antibody test for Lyme disease or a D-dimer would not be indicated for this patient based on her history and symptoms. Because of the patient's history of irregular menses, a β -hCG level would be indicated.

Ref: LeFevre ML, LeFevre NM: Vitamin D screening and supplementation in community-dwelling adults: Common questions and answers. *Am Fam Physician* 2018;97(4):254-260.

Item 167**ANSWER: E**

In a patient presenting with obesity, hypertension, type 2 diabetes mellitus, and hirsutism, who also has thin skin and osteopenia, an elevated 24-hour collection showing high urinary free cortisol confirms the presence of Cushing syndrome. The dexamethasone suppression test, though still commonly used, no longer has a place in the diagnosis and treatment of patients with Cushing syndrome. Corticotropin-dependent and corticotropin-independent causes of Cushing syndrome can be separated by measuring plasma corticotropin. Plasma free cortisol measurements should be obtained only to determine the success or failure of transsphenoidal microadenomectomy or adrenalectomy. Inferior petrosal sinus sampling is used to confirm the source of corticotropin secretion before surgical intervention.

Ref: Loriaux DL: Diagnosis and differential diagnosis of Cushing's syndrome. *N Engl J Med* 2017;376(15):1451-1459.

Item 168**ANSWER: D**

This patient has obesity hypoventilation syndrome (OHS), a disorder in which central obesity leads to chronic hypoventilation due at least in part to restricted diaphragm excursion. Current criteria for this condition include hypoventilation leading to carbon dioxide retention ($\text{PaCO}_2 > 45 \text{ mm Hg}$) in an individual with a BMI $> 30 \text{ kg/m}^2$ when other causes of chronic alveolar hypoventilation have been ruled out. These patients retain bicarbonate to compensate for the respiratory acidosis. It has been suggested that an increased serum bicarbonate level ($> 29 \text{ mEq/L}$) in the absence of another cause for metabolic alkalosis should be included in the definition of OHS.

OHS leads to a restrictive pattern on spirometry, which this patient has. Asthma and COPD are obstructive lung diseases and can therefore be ruled out in this patient who has no signs of airway obstruction on spirometry. Obstructive sleep apnea is often present in patients with OHS, but sleep apnea alone does not lead to daytime hypoventilation and carbon dioxide retention. Pulmonary fibrosis is a cause of restrictive lung disease and has not yet been completely ruled out in this patient, but a normal chest radiograph makes this less likely. Comprehensive pulmonary function testing, including the diffusion capacity of the lung for carbon monoxide (DLCO), would help rule this out. Pulmonary fibrosis leads to a decreased DLCO while OHS does not.

Ref: Johnson JD, Theurer WM: A stepwise approach to the interpretation of pulmonary function tests. *Am Fam Physician* 2014;89(5):359-366. 2) Piper A: Obesity hypoventilation syndrome: Weighing in on therapy options. *Chest* 2016;149(3):856-868.

Item 169

ANSWER: D

Coronary artery stenting is a common procedure, and stent restenosis carries a high mortality rate. Current American College of Cardiology guidelines recommend dual antiplatelet therapy (aspirin with a second agent such as clopidogrel) for at least 12 months following the placement of a drug-eluting stent. Dual antiplatelet therapy with aspirin plus clopidogrel for more than 1 year gives no additional benefit and carries an additional risk of bleeding. Aspirin has been shown to be effective for the secondary prevention of heart disease and should be continued after 1 year.

Ref: Ebell MH: No benefit to prolonged dual antiplatelet therapy after drug-eluting stent placement. *Am Fam Physician* 2014;90(7):502. 2) Smith JN, Negrelli JM, Manek MB, et al: Diagnosis and management of acute coronary syndrome: An evidence-based update. *J Am Board Fam Med* 2015;28(2):283-293. 3) Mukherjee D: ACC/AHA guideline update on duration of dual antiplatelet therapy in CAD patients. American College of Cardiology, 2016. 4) Mikhail MA, Mohabbat AB, Ghosh AK: Perioperative cardiovascular medication management in noncardiac surgery: Common questions. *Am Fam Physician* 2017;95(10):645-650.

Item 170

ANSWER: D

Plantar fasciitis is the most common cause of heel pain, with a prevalence of 10% in the general population. It often presents with throbbing heel pain that is worst in the morning with the first step after rest. Palpation of the medial calcaneal tuberosity and dorsiflexion of the affected foot will elicit sharp pain. Diagnostic imaging is not required. Heel spurs are present in approximately 50% of patients with plantar fasciitis, but can also be found in patients without plantar fasciitis.

Calcaneal stress fractures are caused by repetitive overuse and the pain usually begins after an increase in weight-bearing activities or a change in activities. It usually occurs only with activity, but may eventually also occur at rest. Heel pad syndrome causes pain with deep palpation of the middle of the heel or walking barefoot on harder surfaces. Sever's disease is the most common cause of heel pain in children and adolescents 8–12 years of age.

Ref: Tu P: Heel pain: Diagnosis and management. *Am Fam Physician* 2018;97(2):86-93.

Item 171**ANSWER: A**

Complete vocal rest, including no whispering or throat clearing, is the most effective and quickest initial remedy for short-duration laryngitis, whether viral or due to vocal overuse or abuse. Limiting voice use or whispering, as opposed to complete vocal rest, will likely prolong and possibly worsen hoarseness. Clearing the throat of mucus should also be avoided for the same reason. Inhaled corticosteroids and antibiotics are not effective treatments for laryngitis. Hypertonic saline nebulization treatments would likely cause violent coughing fits that would worsen the condition. Nebulized ribavirin is never indicated for use in adults.

Ref: House SA, Fisher EL: Hoarseness in adults. *Am Fam Physician* 2017;96(11):720-728.

Item 172**ANSWER: A**

Second degree Mobitz type I (Wenckebach) heart block is characterized by an intermittent blockade of electrical impulses from the atria to the ventricles at the level of the atrioventricular node. This prevents generation of a QRS complex. It is characterized by progressive prolongation of the PR interval until a P wave is not followed by a QRS complex. P waves come at regular intervals so PP intervals are normal. Following the missed QRS complex, the PR interval returns to its baseline duration. A pacemaker is not recommended in patients with second degree Mobitz type I heart block who are asymptomatic. It is recommended in symptomatic patients, however, and is guided by electrophysiologic studies.

Ref: Kasper DL, Fauci AS, Hauser SL, et al (eds): *Harrison's Principles of Internal Medicine*, ed 19. McGraw-Hill, 2015, pp 1470-1476.

Item 173**ANSWER: C**

This patient has symptoms of anaphylaxis. Symptoms include an acute onset (minutes to several hours); involvement of the skin, mucosal tissue, or both; plus one of the following: respiratory compromise (dyspnea, wheezing, bronchospasm, stridor, reduced peak expiratory flow, hypoxemia), reduced blood pressure, or associated symptoms of end-organ dysfunction (hypotonia, collapse, syncope, incontinence).

The first and most important treatment in anaphylaxis is intramuscular epinephrine, 1:1000 dilution dosed at 0.01 mg/kg (maximal dose of 0.3 mg in children and 0.5 mg in adults) (SOR B). Management of the airway, breathing, and circulation is also essential (SOR B).

Other essential treatments include volume replacement with normal saline for the treatment of hypotension that does not respond to epinephrine (SOR B). Histamine H₁-receptor antagonists such as diphenhydramine and corticosteroids may be considered as second-line treatments in patients with anaphylaxis (SOR C). Glucagon can be considered for patients who are taking β -blockers.

Ref: Arnold JJ, Williams PM: Anaphylaxis: Recognition and management. *Am Fam Physician* 2011;84(10):1111-1118. 2) Commis SP: Outpatient emergencies: Anaphylaxis. *Med Clin North Am* 2017;101(3):521-536.

Item 174**ANSWER: C**

Low-dose aspirin therapy is recommended by the U.S. Preventive Services Task Force for the primary prevention of cardiovascular disease (CVD) in patients 50–59 years of age who have a risk of CVD $\geq 10\%$ (USPSTF B recommendation). The recommendation statement adds that the patient should have a life expectancy of at least 10 years, should be willing to take daily aspirin for at least 10 years, and should not be at increased risk for gastrointestinal bleeding. The decision to start aspirin therapy for patients 60–69 years of age should be based on individual considerations (USPSTF C recommendation). For adults younger than 50 or age 70 or older, the evidence is insufficient to assess the balance of benefits and harms (C recommendation). The recent Aspirin in Reducing Events in the Elderly (ASPREE) trial indicated that daily aspirin use in those over age 70 did not significantly lower the risk of cardiovascular disease, and did not increase disability-free survival.

Ref: *Final Recommendation Statement: Aspirin Use to Prevent Cardiovascular Disease and Colorectal Cancer: Preventive Medication.* US Preventive Services Task Force, 2017. 2) McNeil JJ, Nelson MR, Woods RL, et al: Effect of aspirin on all-cause mortality in the healthy elderly. *N Engl J Med* 2018;[Epub ahead of print]. 3) McNeil JJ, Wolfe R, Woods RL, et al: Effect of aspirin on cardiovascular events and bleeding in the healthy elderly. *N Engl J Med* 2018;[Epub ahead of print].

Item 175**ANSWER: B**

The Baby-Friendly Hospital Initiative is a global program established by UNICEF and WHO to promote healthy infant feeding and mother-baby bonding. The primary objective is to educate the public on the benefits of breastfeeding and encourage, promote, and facilitate breastfeeding as outlined in the UNICEF/WHO Ten Steps to Successful Breastfeeding chart. These steps promote breastfeeding to the public and provide guidelines for hospitals and birthing centers for the successful initiation and continuation of breastfeeding.

Baby-friendly facilities must have a written breastfeeding policy that is routinely communicated to all health care staff, and all health care staff must be trained in the skills necessary to implement this policy. All pregnant women should be informed about the benefits and management of breastfeeding. Mothers should be helped to initiate breastfeeding within an hour after birth and shown how to breastfeed and to maintain lactation, even if they are separated from their infants. Breastfeeding infants should not be given food other than breast milk, unless medically indicated. If mothers choose to give formula after appropriate education, they should be instructed in proper preparation and use.

Rooming in should be practiced, allowing mothers and infants to remain together 24 hours a day. Mothers should be encouraged to breastfeed on demand. Breastfeeding infants should not be given pacifiers or artificial nipples. Mothers should be referred to breastfeeding support groups on discharge from the hospital. In addition, the hospital must comply with the International Code of Marketing of Breast Milk Substitutes, which requires that formula companies cannot give free gifts to staff or mothers, that breast milk substitutes are not marketed in the maternity unit, and that breast milk supplements and infant feeding supplies are purchased at fair market price.

Ref: Perrine CG, Galuska DA, Dohack JL, et al: Vital signs: Improvements in maternity care policies and practices that support breastfeeding—United States, 2007–2013. *MMWR Morb Mortal Wkly Rep* 2015;64(39):1112-1117. 2) Guidelines and evaluation criteria for facilities seeking baby-friendly designation. Baby-Friendly USA, 2016.

Item 176

ANSWER: A

This patient has a pituitary microadenoma. Microadenomas < 10 mm in size that are secreting prolactin may be treated with a dopaminergic agent such as bromocriptine. This will lower the prolactin level and shrink the adenoma. Nonprolactin-secreting adenomas, especially those > 10 mm in size (macroadenomas), require neurosurgical evaluation.

Ref: Molitch ME: Diagnosis and treatment of pituitary adenomas: A review. *JAMA* 2017;317(5):516-524.

Item 177

ANSWER: B

Inclusion criteria for bariatric surgery include a BMI ≥ 40 kg/m² without coexisting medical problems or a BMI ≥ 35 kg/m² with one or more severe obesity-related comorbidities such as diabetes mellitus. Exclusion criteria include active substance abuse, uncontrolled severe psychiatric illness, severe cardiopulmonary disease that makes the surgical risk prohibitive, and lack of cognitive function to comprehend the associated risks, benefits, and required lifestyle changes.

Ref: Schroeder R, Harrison TD, McGraw SL: Treatment of adult obesity with bariatric surgery. *Am Fam Physician* 2016;93(1):31-37.

Item 178

ANSWER: C

Maintaining and communicating accurate patient medication information is one of the goals of the Joint Commission National Patient Safety Goals program. This includes medication reconciliation, which is intended to identify and resolve discrepancies. In this process, a clinician compares the medications a patient should be using and is actually using with the new medications that are ordered. While adverse drug effects, potentially inappropriate medication use in the elderly, high-risk medication use, or polypharmacy might also occur and might be beneficial to address, these are not the primary focus of medication reconciliation.

Ref: National Patient Safety Goals Effective January 1, 2015: Hospital Accreditation Program. The Joint Commission, 2015. 2) AHRQ patient safety primer: Medication reconciliation. Agency for Healthcare Research and Quality, updated 2017.

Item 179**ANSWER: A**

The defining symptom of acute bronchitis is cough. Even in smokers the etiologic agent is viral at least 90% of the time, so antibiotics are not indicated. Unless wheezing is noted, albuterol is not helpful. Inhaled corticosteroids are used in maintenance therapy for asthma. Indications for an adult patient with acute bronchitis to have a chest radiograph include: bloody sputum, rusty-colored sputum, or dyspnea; a pulse rate >100 beats/min; a respiratory rate >24/min; or a temperature >37.8°C (100.0°F). A chest radiograph is also indicated if there are abnormal findings on a chest examination such as fremitus, egophony, or focal consolidation. Supportive care is made easier by informing the patient that symptoms are likely to last 2–3 weeks. Symptoms may be managed with measures such as dextromethorphan, guaifenesin, or honey.

Ref: Kinkade S, Long NA: Acute bronchitis. *Am Fam Physician* 2016;94(7):560-565.

Item 180**ANSWER: D**

The American Heart Association and the American College of Cardiology have decreased the number of indications for antibiotic prophylaxis prior to dental procedures. Currently antibiotics are indicated for prosthetic cardiac valves, previous infective endocarditis, unrepaired cyanotic congenital heart disease or a repaired congenital defect with a residual shunt, and a cardiac transplant with valve regurgitation due to a structurally abnormal valve. Amoxicillin, 2 g, is the antibiotic prophylaxis of choice.

Ref: Wilson W, Taubert KA, Gewitz M et al: Prevention of infective endocarditis: Guidelines from the American Heart Association: A guideline from the American Heart Association Rheumatic Fever, Endocarditis, and Kawasaki Disease Committee, Council on Cardiovascular Disease in the Young, and the Council on Clinical Cardiology, Council on Cardiovascular Surgery and Anesthesia, and the Quality of Care and Outcomes Research Interdisciplinary Working Group. *Circulation* 2007;116(15):1736-1754. 2) Oral health topics: Antibiotic prophylaxis prior to dental procedures. American Dental Association, updated 2018.

Item 181**ANSWER: B**

This patient has a history and physical examination concerning for septic arthritis, which is a rheumatologic emergency due to the potential for joint destruction. Joint swelling, redness, and warmth may accompany the pain but these are more difficult to detect at the hip than the knee. Systemic symptoms such as fever may occur but are absent in more than 40% of patients, particularly elderly patients and those who are immunocompromised. Risk factors for septic arthritis include underlying joint disease such as rheumatoid arthritis or osteoarthritis, and immunosuppressive states such as HIV infection, diabetes mellitus, and taking immunosuppressive medications. This patient has a history of osteoarthritis and is taking adalimumab, an immunosuppressive agent. Although there may be clues to the diagnosis of septic arthritis on imaging and laboratory assessment, the diagnostic test of choice is analysis of synovial fluid obtained through arthrocentesis. A radionuclide bone scan, CT, MR arthrography, and MRI are not sensitive enough to rule out septic arthritis.

Ref: Horowitz DL, Katzap E, Horowitz S, Barilla-LaBarca ML: Approach to septic arthritis. *Am Fam Physician* 2011;84(6):653-660. 2) Goldman L, Schafer AI (eds): *Goldman's Cecil Medicine*, ed 25. Elsevier Saunders, 2016, pp 1806-1807.

Item 182

ANSWER: B

Cognitive-behavioral therapy, specifically exposure and response prevention, is considered the most effective psychotherapy method (SOR A). There is no evidence for psychodynamic or “talk” therapy. Traditional psychotherapy and psychoanalysis are less effective than cognitive-behavioral therapy.

Ref: Fenske JN, Petersen K: Obsessive-compulsive disorder: Diagnosis and management. *Am Fam Physician* 2015;92(10):896-903.

Item 183

ANSWER: B

Proton pump inhibitors (PPIs) are safe and well tolerated for short-term use. It is recommended that the lowest dosage and shortest duration of therapy be used to control symptoms of GERD. Long-term PPI use is associated with fractures, hypomagnesemia, vitamin B₁₂ deficiency, iron deficiency, and acute interstitial nephritis with progression to chronic kidney disease. Use of PPIs has also been associated with community-acquired pneumonia and *Clostridium difficile* infection, although studies have been conflicting. Vitamin D deficiency, nephrotic syndrome, gastrointestinal malignancy, and myocardial infarction are not proven complications of long-term PPI use.

Ref: Anderson WD 3rd, Strayer SM, Mull SR: Common questions about the management of gastroesophageal reflux diseases. *Am Fam Physician* 2015;91(10):692-697. 2) Safety of long-term PPI use. *JAMA* 2017;318(12):1177-1178. 3) Vaezi MF, Yang YX, Howden CW: Complications of proton pump inhibitor therapy. *Gastroenterology* 2017;153(1):35-48.

Item 184

ANSWER: A

Molluscum contagiosum is a common disease during childhood, but can also occur in adolescents and adults. It is caused by a poxvirus and is characterized by flesh-colored, dome-shaped papules with central umbilication, most commonly on the trunk, axilla, popliteal or antecubital fossae, and crural folds. If lesions are asymptomatic and not inflamed, the initial treatment is observation, with most lesions resolving spontaneously within 2–12 months. If the lesions are inflamed or pruritic, then topical corticosteroid treatment, chemical treatment with cantharidin, podofilox 0.5% solution, curettage, or cryotherapy may be indicated.

Atopic dermatitis (eczema) is initially treated with emollients and by avoiding frequent hot baths. Verruca (warts) are commonly treated with paring, followed by topical salicylic acid or cryotherapy. Antifungal cream would not be appropriate.

Ref: Allmon A, Deane K, Martin KL: Common skin rashes in children. *Am Fam Physician* 2015;92(3):211-216.

Item 185**ANSWER: D**

This patient presents with symptoms of acute rhinosinusitis. In the first 3–4 days, viral and bacterial rhinosinusitis are indistinguishable. Guidelines from the American Academy of Otolaryngology—Head and Neck Surgery suggest that antibiotics should not be routinely prescribed for acute mild to moderate sinusitis unless symptoms persist for 7 days or worsen after initial improvement. Watchful waiting without antibiotic treatment is appropriate when follow-up is accessible (SOR A). In this scenario antibiotic therapy is not indicated.

Amoxicillin with or without clavulanate is appropriate for symptoms lasting 7 or more days without improvement and is the first-line antibiotic treatment for acute bacterial rhinosinusitis (SOR A). Due to the risk of adverse effects and no benefit over β -lactams, respiratory fluoroquinolones are not considered first-line antibiotic therapy. Symptomatic treatment is recommended within the first 10 days of the onset of symptoms and may be continued if antibiotics are started. Intranasal corticosteroid use has a modest therapeutic benefit for patients with acute rhinosinusitis. Decongestants and antihistamines have not been proven effective for the treatment of acute rhinosinusitis.

Ref: Aring AM, Chan MM: Current concepts in adult acute rhinosinusitis. *Am Fam Physician* 2016;94(2):97-105.

Item 186**ANSWER: D**

Although national guidelines vary, it is generally advised to start routine colon cancer screening between ages 45 and 50, and to screen with a more individualized approach between ages 75 and 85. Factors to consider include life expectancy, the patient's overall health, whether the patient has been screened previously, and patient preference. Most guidelines recommend stopping colon cancer screening in patients older than 85 years or when their life expectancy falls below 10 years (SOR B).

Ref: AGS Choosing Wisely Workgroup: American Geriatrics Society identifies another five things that healthcare providers and patients should question. *J Am Geriatr Soc* 2014;62(5):950-960. 2) Salzman B, Beldowski K, de la Paz A: Cancer screening in older patients. *Am Fam Physician* 2016;93(8):659-667. 3) *Final Recommendation Statement: Colorectal Cancer: Screening*. US Preventive Services Task Force, 2016.

Item 187**ANSWER: B**

Some abnormal gross motor developmental findings suggest muscular dystrophy. Signs of increased muscular tone, such as cross-legged posturing, neck stiffness, and hyperreflexia, suggest a central cause of motor delay such as cerebral palsy. Head lag due to neck muscle weakness in infants is a classic early finding of muscular dystrophies. Hemiparesis similarly suggests a central nervous system abnormality. Toe walking can be seen with both central and peripheral neuromuscular abnormalities, including muscular dystrophy, but is less specific, and therefore less helpful, in differentiating the cause of motor delay. In muscular dystrophies it is a sign of quadriceps weakness.

Ref: Lurio JG, Peay HL, Mathews KD: Recognition and management of motor delay and muscle weakness in children. *Am Fam Physician* 2015;91(1):38-44.

Item 188

ANSWER: E

Amniotic fluid volume is regulated in part by fetal swallowing, inspiration, and urination. Some malformations of the urinary tract, including renal agenesis and persistent obstruction from posterior urethral valves, lead to oliguria or anuria, and are associated with marked oligohydramnios.

Anencephaly, esophageal atresia, heart failure, and maternal α -thalassemia are associated with polyhydramnios. Anencephaly is probably the most common cause of polyhydramnios, via transudation from the exposed meninges; swallowing difficulties and excessive urination may also be contributing factors. Esophageal atresia is almost always associated with polyhydramnios due to an inability to swallow. Intrauterine heart failure, whether due to dysrhythmias, structural defects, or severe anemia, often leads to fetal hydrops, which is associated with polyhydramnios. α -Thalassemia, relatively common in Asians, can also cause fetal hydrops and polyhydramnios.

Ref: Cunningham FG, Leveno KJ, Bloom SL, et al (eds): *Williams Obstetrics*, ed 23. McGraw-Hill Medical, 2010, pp 495-496.

Item 189

ANSWER: E

Clindamycin or a combination of trimethoprim/sulfamethoxazole (or doxycycline or minocycline) plus cephalexin (or dicloxacillin or amoxicillin/clavulanate) should provide adequate coverage for *Streptococcus* and methicillin-resistant *Staphylococcus aureus* (MRSA) for mild to moderate cellulitis.

Doxycycline plus trimethoprim/sulfamethoxazole would provide inadequate coverage for streptococcal bacteria. Cephalexin plus dicloxacillin would provide inadequate coverage for MRSA. The primary indication for ciprofloxacin is treatment of infections with gram-negative rods. Fosfomycin is indicated only for urinary tract infections. Neither is typically used in the treatment of cellulitis.

Ref: Raff AB, Kroshinsky D: Cellulitis: A review. *JAMA* 2016;316(3):325-337.

Item 190

ANSWER: A

This patient most likely has iron deficiency anemia. The low normal mean corpuscular volume, low serum ferritin, and low reticulocyte index are all consistent with iron deficiency. Vitamin B₁₂ deficiency would be indicated by low vitamin B₁₂ and a macrocytic anemia. Serum ferritin would be higher with anemia of chronic disease and myelodysplastic anemia. The reticulocyte index would be high with hemolysis.

Ref: Kasper DL, Fauci AS, Hauser SL, et al (eds): *Harrison's Principles of Internal Medicine*, ed 19. McGraw-Hill, 2015, pp 393-399.

Item 191

ANSWER: B

In many normally developing infants there may be imperfect coordination of eye movements and alignment during the early days and weeks of life, but proper coordination should be achieved by age 4–6 months. Persistent deviation of an eye in an infant requires evaluation.

Ref: Bell AL, Rodes ME, Collier Kellar L: Childhood eye examination. *Am Fam Physician* 2013;88(4):241–248. 2) Kliegman RM, Stanton BF, Geme JW III, et al (eds): *Nelson Textbook of Pediatrics*, ed 20. Elsevier Saunders, 2016, pp 3026–3031.

Item 192

ANSWER: C

This patient has clinically diagnosable acute bacterial prostatitis, and no further testing, including imaging, is required to establish the diagnosis. Culture of a midstream voided urine may aid in identifying the pathogen, but prostate massage should be avoided because it may increase the risk of bacteremia. A prostate biopsy is not indicated in the presence of acute infection, and a prostate-specific antigen level is not indicated because it is likely to be elevated in the presence of infection.

Ref: Coker TJ, Dierfeldt DM: Acute bacterial prostatitis: Diagnosis and management. *Am Fam Physician* 2016;93(2):114–120.

Item 193

ANSWER: D

Insulin therapy should be initiated in hospitalized patients with persistent hyperglycemia, starting at a threshold of 180 mg/dL. Once insulin therapy is started, a target glucose range of 140–180 mg/dL is recommended for the majority of hospitalized patients, regardless of whether they have a critical illness.

Ref: American Diabetes Association: 14. Diabetes care in the hospital: Standards of medical care in diabetes—2018. *Diabetes Care* 2018;41(Suppl 1):S144–S151.

Item 194

ANSWER: E

Traveler's diarrhea is caused predominantly by bacterial pathogens (up to 80%–90%) and is associated with hygiene practices. Handwashing has been shown to reduce the risk of traveler's diarrhea by 30%. The use of alcohol-based hand sanitizer is also effective. Although it is considered traditional advice, avoiding street vendor foods, tap water, ice, and raw foods has not been shown to reduce the risk of traveler's diarrhea. There is not sufficient evidence to recommend taking a probiotic to reduce the risk of traveler's diarrhea. Due to concerns about antimicrobial resistance and altering protective bowel flora, taking prophylactic antibiotics is generally not recommended for healthy travelers. However, using an antibiotic for as-needed treatment is appropriate.

Ref: Sanford C, McConnell A, Osborn J: The pretravel consultation. *Am Fam Physician* 2016;94(8):620–627. 2) Chen LH, Hochberg NS, Magill AJ: The pretravel consultation. Centers for Disease Control and Prevention, 2017.

Item 195**ANSWER: C**

This patient has findings consistent with influenza, including a rapid onset of fever, nausea, and sore throat, and negative pulmonary findings. Influenza is considered a clinical diagnosis and confirmation of the diagnosis with laboratory testing is not required. Treatment of influenza is recommended for individuals at a high risk of influenza-related complications. High-risk individuals include those with chronic lung disease; cardiovascular (excluding hypertension), renal, hepatic, hematologic, or neurologic disease; or age > 65. Children on long-term aspirin therapy, and pregnant and postpartum women are also considered high risk. This patient should be treated with antiviral medication because of his chronic pulmonary disease. While pneumonia and streptococcal pharyngitis should be considered in the differential diagnosis, these are less likely given the examination findings, and antibiotics are not recommended. Prednisone is not indicated for influenza-like illness and may cause harm.

Ref: Influenza antiviral medications: Summary for clinicians. Centers for Disease Control and Prevention, 2018.

Item 196**ANSWER: D**

This patient presents with secondary amenorrhea. The differential diagnosis includes polycystic ovary syndrome (PCOS), intrauterine synechiae (Asherman syndrome), functional hypothalamic amenorrhea, hypothyroidism, hyperprolactinemia, and primary ovarian insufficiency (also known as premature ovarian failure). This patient's presentation and the laboratory findings are most consistent with a diagnosis of primary ovarian insufficiency. This is defined as menopause before the age of 40 due to ovarian follicular depletion. Laboratory findings will usually reveal a low serum estradiol and elevated FSH and LH levels. This condition is different than menopause because of the age of presentation and the unpredictability of long-term ovarian function (up to 10% of cases spontaneously remit and patients have a temporary return of fertility).

Patients with PCOS typically present with obesity, difficulty conceiving, and normal or low FSH and LH levels. This patient's normal weight and prior history of normal menses make this diagnosis less likely. Intrauterine synechiae is characterized by scar tissue inside the uterus. Risk factors include intrauterine procedures, pregnancy, inflammation, and infection. Patients present with abnormal uterine bleeding, recurrent pregnancy loss, dysmenorrhea, and infertility. FSH and LH levels are usually normal.

Functional hypothalamic amenorrhea is characterized by suppression of the hypothalamic-pituitary-ovarian axis, usually due to extreme stress, excessive exercise, marked weight loss, and/or dysfunctional eating. LH and FSH levels are usually low or low-normal. Turner's syndrome is caused by the 45,X genotype, and patients have short stature, a webbed neck, a low hairline, and cardiac abnormalities. This is unlikely in a patient who is 178 cm (70 in) tall and has a normal examination.

Ref: Klein DA, Poth MA: Amenorrhea: An approach to diagnosis and management. *Am Fam Physician* 2013;87(11):781-788.

Item 197**ANSWER: D**

The U.S. Preventive Services Task Force recommends screening for hepatitis C virus (HCV) infection in persons at risk for infection and also one-time screenings for adults born between 1945 and 1965 (Grade B recommendation). HCV is the most common chronic bloodborne pathogen in the United States and a leading cause of complications of chronic liver disease. The prevalence of the anti-HCV antibody in the United States is approximately 1.6% in non-institutionalized persons. According to data from 1999 to 2008, approximately 75% of patients in the United States living with HCV infection were born between 1945 and 1965. This patient has a normal weight so diabetes screening is not recommended. Screening for asymptomatic bacteriuria is not recommended in nonpregnant patients.

Ref: *Final Update Summary: Hepatitis C: Screening*. US Preventive Services Task Force, 2016.

Item 198**ANSWER: D**

The most common cause of hypercalcemia is hyperparathyroidism. This is seldom symptomatic and is often discovered through routine blood testing. Hypercalcemia due to cancer can be caused by secretion of the parathyroid hormone-related protein and by osteoclastic bone resorption. Other causes of hypercalcemia include thiazide diuretics, lithium, vitamin D intoxication, hyperthyroidism, milk alkali syndrome from excessive calcium antacid ingestion, adrenal insufficiency, and lymphoma.

Ref: Barstow C: Electrolytes: Calcium disorders. *FP Essent* 2017;459:29-34.

Item 199**ANSWER: D**

The mainstay of therapy for acute respiratory syncytial virus bronchiolitis is supportive care, and maintaining hydration is important. Infants with respiratory rates >60/min may have poor feeding secondary to difficulty breathing and oral rehydration may increase the risk of aspiration. In these cases, nasogastric or intravenous fluids should be administered. Oxygen saturation of 90% or more on room air is sufficient for infants with bronchiolitis, and using supplemental oxygen to maintain higher oxygen saturations only prolongs hospitalization because of an assumed need for oxygen. Bronchodilators should not be administered to infants with bronchiolitis, because they have not been shown to have any effect on the need for hospitalization, oxygen saturation, or disease resolution. In addition, there is no evidence to support the use of epinephrine or corticosteroids in the inpatient setting.

Ref: Smith DK, Seales S, Budzik C: Respiratory syncytial virus bronchiolitis in children. *Am Fam Physician* 2017;95(2):94-99.

Item 200

ANSWER: A

Gallstones are often asymptomatic and found incidentally on imaging. However, they may become symptomatic, which usually causes pain in the right upper quadrant or epigastrium. Most patients with symptomatic gallstones present with chronic cholecystitis, which causes recurrent attacks of pain. The pain is constant, increases in severity at the beginning, and lasts from 1 to 5 hours. It often starts during the night after a fatty meal and may be associated with nausea and vomiting. Abdominal ultrasonography is the initial imaging method.

The two main complications of choledochal stones are cholangitis and pancreatitis. Acute cholangitis is a bacterial infection. Bacterial growth is enhanced by obstruction of the duct. It may present as a mild self-limited disease but can also lead to sepsis. Cases typically present with fever, pain, and jaundice. Laboratory findings include an elevated WBC count and elevated bilirubin, transaminases, and alkaline phosphatase. Ultrasonography will show a dilated bile duct in many cases, although it might not be dilated in acute obstruction.

Patients with pancreatitis present with pain, nausea, and vomiting. The pain is usually epigastric and radiates to the back. It reaches its maximum intensity within 1 hour and may last for days. The physical examination may reveal tachycardia, hypotension, tachypnea, and fever. The abdomen may be distended and is typically tender to palpation. The diagnosis requires two of three primary features: abdominal pain, elevation of serum amylase or lipase, and findings on imaging studies that are consistent with the diagnosis. Ultrasonography can show pancreatic enlargement or edema, and visualization of gallstones will suggest choledocholithiasis as the cause of the pancreatitis.

Ref: Brunicki FC (ed): *Schwartz's Principles of Surgery*, ed 10. McGraw Hill Medical, 2015, pp 1317-1323. 2) Goldman L, Schafer AI (eds): *Goldman's Cecil Medicine*, ed 25. Elsevier Saunders, 2016, pp 961-962, 1038-1044.

Item 201

ANSWER: C

This patient's radiographs show an anterior shoulder dislocation on anteroposterior and scapular Y views. Treatment of this condition includes reduction of the dislocation, which can be accomplished in this case with a local anesthetic or conscious sedation. An acute shoulder dislocation reduction may be attempted without pain medication. Surgical decompression and figure-of-eight bandaging are not indicated. Sling immobilization and physical therapy may be appropriate after shoulder reduction.

Ref: Monica J, Vredenburg Z, Korsh J, Gatt C: Acute shoulder injuries in adults. *Am Fam Physician* 2016;94(2):119-127.

Item 202**ANSWER: C**

To prevent neural tube defects in newborns, the U.S. Preventive Services Task Force recommends folic acid, 0.4–0.8 mg daily, for all women who are planning on or are capable of becoming pregnant (USPSTF A recommendation).

Ref: *Final Recommendation Statement: Folic Acid for the Prevention of Neural Tube Defects: Preventive Medication.* US Preventive Services Task Force, 2017.

Item 203**ANSWER: B**

There are three major risk factors for curve progression of idiopathic scoliosis: the magnitude of the curve at presentation, the potential for future growth, and female sex. Of these factors, curve progression has the most impact on the need for referral versus observation. The Cobb angle is based on spine radiology that quantifies the magnitude of the scoliosis curve. If the Cobb angle is $\geq 20^\circ$ there is a high risk that the curve will progress and that the patient may need treatment. Age, sex, menstrual status, pubertal status, and growth potential are less important factors. Scoliosis typically does not cause pain and it is more likely that this patient's weight is contributing to her back pain.

Ref: Horne JP, Flannery R, Usman S: Adolescent idiopathic scoliosis: Diagnosis and management. *Am Fam Physician* 2014;89(3):193-198.

Item 204**ANSWER: C**

Although behavioral interventions are the mainstay of treatment for insomnia, they often need to be supplemented by pharmacologic therapy. When both doxepin and extended-release melatonin fail to provide benefit, a member of the Z-drug class should be tried next. Among the Z-drugs only eszopiclone provides an early peak onset and a long half-life, with a 1-hour approximate time to peak and a 6-hour half-life. While zaleplon has an equally short time to peak of 1 hour, it also has a 1 hour half-life. Antihistamines, including diphenhydramine and doxylamine, as well as atypical antipsychotics such as olanzapine, are not indicated unless used primarily to treat another condition.

Ref: Matheson E, Hainer BL: Insomnia: Pharmacologic therapy. *Am Fam Physician* 2017;96(1):29-35.

Item 205**ANSWER: B**

Chronic cough is defined as a cough lasting at least 8 weeks. If a thorough history (with attention to ACE inhibitor use), a physical examination, and a plain-film chest radiograph do not suggest an obvious cause for the cough, experts suggest that the three most common etiologies are gastroesophageal reflux, persistent postnasal drip, and unrecognized asthma. Treating a chronic cough empirically with a high-dose proton pump inhibitor for 2–3 months is considered a reasonable choice before further investigations are attempted. Ordering an esophageal pH probe or esophagogastroduodenoscopy would also be considered appropriate. Postnasal drip is often due to allergic rhinitis or another noninfectious condition and some guidelines recommend empiric nasal corticosteroid sprays and/or first-generation oral antihistamine use.

CT of the chest and bronchoscopy may become necessary if the evaluation and treatment for these three common conditions does not improve the patient's symptoms. Since there are no symptoms of bacterial sinusitis, the use of a broad-spectrum antibiotic is not justified.

Ref: Irwin RS, Baumann MH, Bolser DC, et al: Diagnosis and management of cough executive summary: ACCP evidence-based clinical practice guidelines. *Chest* 2006;129(1 Suppl):1S-23S. 2) Broaddus VC, Mason RJ, Ernst JD, et al: *Murray & Nadel's Textbook of Respiratory Medicine*, ed 6. Elsevier Saunders, 2016, pp 497-514. 3) Smith JA, Woodcock A: Chronic cough. *N Engl J Med* 2016;375(16):1544-1551.

Item 206**ANSWER: D**

Physicians should use trained interpreters whenever possible to avoid mistakes and pitfalls associated with using family members or untrained interpreters for medical interviews. Simply being bilingual does not mean someone will be an appropriate interpreter. Although it is technically legal to use a nontrained interpreter for this patient, title VI of the Civil Rights Act requires interpreter services for all patients with limited English capabilities who are receiving federal assistance (except Medicare Part B). This patient does not have Medicaid, but ethically it would be appropriate to extend the same courtesy to her.

It is difficult to predict what may occur in any visit, and a physician is open to serious medical mistakes by assuming a visit does not require an interpreter, because the patient may bring up a serious medical issue. Confidentiality is a concern when using family members to interpret, since they may not have an understanding of the need for confidentiality. It is not appropriate to ask the patient through her family member about her preferences for interpreting.

Ref: Juckett G, Unger K: Appropriate use of medical interpreters. *Am Fam Physician* 2014;90(7):476-480.

Item 207**ANSWER: C**

The National Osteoporosis Foundation recommends pharmacologic treatment when a DXA scan reveals a T-score ≤ -2.5 (the cutoff for a diagnosis of osteoporosis), or when the T-score falls between -1.0 and -2.5 (the diagnosis criterion for osteopenia) and the 10-year risk of a major fracture reaches 20%. The T-score of -2.0 places this patient in the “osteopenic” range. A 10-year probability of a hip fracture $\geq 3\%$ is also an indication for treatment.

Ref: Cosman F, de Beur SJ, LeBoff MS, et al: Clinician’s guide to prevention and treatment of osteoporosis. *Osteoporosis Int* 2014;25(10):2359-2381. 2) Jeremiah MP, Unwin BK, Greenawald MH, Casiano VE: Diagnosis and management of osteoporosis. *Am Fam Physician* 2015;92(4):261-268.

Item 208**ANSWER: C**

Overt hyperthyroidism during pregnancy is associated with adverse effects to the mother and fetus, so treatment is required. Since methimazole is associated with birth defects when used in the first trimester, propylthiouracil is preferred. Methimazole should be considered after the first trimester because the risk of congenital anomalies is less than the risk of liver failure associated with propylthiouracil. Surgery and radioactive iodine should only be used if there is a clear indication, and radioactive iodine would not be appropriate during pregnancy.

Ref: Carney LA, Quinlan JD, West JM: Thyroid disease in pregnancy. *Am Fam Physician* 2014;89(4):273-278.

Item 209**ANSWER: C**

This patient has a classic presentation of podagra (acute metatarsophalangeal joint gout). Without an overlying skin lesion as an indicator of infection, this patient can be assumed to have gout in this classic presentation. Low-dose colchicine, 1.2 mg initially, followed by 0.6 mg in 1 hour, is recommended over high-dose colchicine, 1.2 mg initially, followed by 0.6 mg hourly for 6 hours. The high-dose regimen increases side effects but the effectiveness is not improved. This case should not be assumed to represent a septic joint and treated with cephalexin, given the typical podagra presentation. Febuxostat and allopurinol are urate-lowering drugs used as treatment for intercritical gout and not for acute treatment. Generally, treatment with urate-lowering therapy is not necessary in patients having fewer than two attacks per year.

Ref: Qaseem A, McLean RM, Starkey M, et al: Diagnosis of acute gout: A clinical practice guideline from the American College of Physicians. *Ann Intern Med* 2017;166(1):52-57. 2) Qaseem A, Harris RP, Forciea MA; Clinical Guidelines Committee of the American College of Physicians: Management of acute and recurrent gout: A clinical practice guideline from the American College of Physicians. *Ann Intern Med* 2017;166(1):58-68.

Item 210**ANSWER: C**

Tetracycline and its derivatives have historically been used for the treatment of papulopustular rosacea and there is data to support their use. A modified-release doxycycline is FDA-approved for this indication. Amoxicillin, cephalexin, erythromycin, and trimethoprim/sulfamethoxazole lack evidence to support their use in the treatment of papulopustular rosacea.

Ref: Oge LK, Muncie HL, Phillips-Savoy AR: Rosacea: Diagnosis and treatment. *Am Fam Physician* 2015;92(3):187-196.

Item 211**ANSWER: B**

Pessaries are considered first-line treatment for pelvic organ prolapse (SOR C). Ring pessaries provide support and are the initial choice in most circumstances. Sexual intercourse can still occur with a ring pessary, which can be inserted and removed by the patient. Space-occupying pessaries are associated with more vaginal discharge and irritation and do not allow for sexual intercourse. While they can improve stress and urge urinary incontinence, Kegel exercises do not treat pelvic organ prolapse. Surgery, including hysterectomy or hysteropexy that conserves the uterus, can be considered after first-line treatment with a pessary.

Ref: Iglesia CB, Smithling KR: Pelvic organ prolapse. *Am Fam Physician* 2017;96(3):179-185.

Item 212**ANSWER: D**

The American Academy of Pediatrics recommends a daily intake of 400 IU of vitamin D in infants, children, and adolescents (SOR C). Breastfeeding does not provide adequate levels of vitamin D. Exclusive formula feeding probably provides adequate levels of vitamin D, but infants who consume less than 1 liter of formula per day need supplementation with 400 IU of vitamin D daily. Vitamin D supplementation should be started within the first 2 months of life.

Ref: Wagner CL, Greer FR: American Academy of Pediatrics Section on Breastfeeding; American Academy of Pediatrics Committee on Nutrition: Prevention of rickets and vitamin D deficiency in infants, children, and adolescents. *Pediatrics* 2008;122(5):1142-1152. 2) Casey CF, Slawson DC, Neal LR: Vitamin D supplementation in infants, children, and adolescents. *Am Fam Physician* 2010;81(6):745-748. 3) Institute of Medicine: *Dietary Reference Intakes for Calcium and Vitamin D*. The National Academies Press, 2011. 4) Bly E, Huntington J, Harper AL: Clinical inquiry. What is the best age to start vitamin D supplementation to prevent rickets in breastfed newborns? Breastfed infants who take vitamin D beginning at 3 to 5 days of life don't develop rickets. *J Fam Pract* 2013;62(12):755-763. 5) Munns CF, Shaw N, Kiely M, et al: Global consensus recommendations on prevention and management of nutritional rickets. *J Clin Endocrinol Metab* 2016;101(2):394-415.

Item 213**ANSWER: E**

The American Society of Anesthesiologists (ASA) has recently revised its physical status classification system. A healthy patient would be classified as ASA I, while a patient with mild systemic disease would be classified as ASA II. All patients who are having major surgery should be offered preoperative laboratory testing, including a CBC and renal function testing. For patients who are ASA III or IV and have chronic liver disease or take anticoagulants, coagulation testing should be considered. There is no compelling evidence to support either a chest radiograph or an EKG as part of a routine preoperative evaluation.

Ref: Martin SK, Cifu AS: Routine preoperative laboratory tests for elective surgery. *JAMA* 2017;318(6):567-568.

Item 214**ANSWER: D**

The most common hip disorder in adolescents (ages 8–15) is slipped capital femoral epiphysis (SCFE). Early diagnosis and treatment are critical in preventing disability related to early-onset degenerative disease of the hip. In the past, SCFE has been more common in boys than in girls but that prevalence is changing due to the rise in obesity. SCFE should be suspected in an adolescent who has unexplained pain in the hip, groin, thigh, or knee. It is rarely associated with trauma, overuse, or prior illness. On examination the most indicative sign is limited internal rotation of the involved hip. Bilateral radiographs of the hips, including frog-leg lateral views, should be obtained in any adolescent who presents with a new limp and pain in the groin, hip, thigh, or knee (SOR C).

Adductor muscle strain (groin strain) is very uncommon in adolescents. Patients suspected of having a groin strain should also undergo radiography. Legg-Calvé-Perthes disease and transient synovitis are more common in children under age 10. The presenting symptoms of hip pain and a limp are similar to SCFE. Apophysitis of the anterior superior iliac spine is common in adolescents but is caused by overuse. It is mostly seen in runners, dancers, and ice hockey and soccer players ages 14–18.

Ref: Peck DM, Voss LM, Voss TT: Slipped capital femoral epiphysis: Diagnosis and management. *Am Fam Physician* 2017;95(12):779-784.

Item 215**ANSWER: A**

In addition to nasal corticosteroids, saline irrigation is a mainstay in the treatment of chronic rhinosinusitis. Low-pressure, high-volume irrigation, such as with a neti pot, is superior to nasal saline spray (SOR B). There is no evidence that one nasal corticosteroid is better than another. The role of antibiotics in the treatment of chronic rhinosinusitis is unclear. Antibiotics may be helpful in patients with signs of bacterial infection, such as mucopurulent drainage or acute worsening of symptoms. Oral corticosteroids are an option for the short-term improvement of severe symptoms in patients with nasal polyps who are already on maintenance therapy with both nasal saline irrigation and an intranasal corticosteroid spray.

Ref: Sedaghat AR: Chronic rhinosinusitis. *Am Fam Physician* 2017;96(8):500-506.

Item 216**ANSWER: B**

This patient has COPD and is in a risk category of A (low risk, fewer symptoms) based on the Global Initiative for Chronic Obstructive Lung Disease (GOLD) combined assessment of COPD. As a result, either a short-acting anticholinergic or a short-acting β_2 -agonist should be selected as the initial pharmacologic management. Long-acting β_2 -agonists or long-acting anticholinergics are indicated for patients with a GOLD combined assessment category of B or worse. Long-acting inhaled corticosteroids are indicated for patients with a GOLD combined assessment category of C or worse. Due to its narrow therapeutic window, modest benefit, and need for monitoring, theophylline is not recommended as an initial agent and should be considered as an alternative only for patients with severe refractory symptoms.

Ref: Gentry S, Gentry B: Chronic obstructive pulmonary disease: Diagnosis and management. *Am Fam Physician* 2017;95(7):433-441. 2) Pocket guide to COPD diagnosis, management, and prevention: A guide for health care professionals. Global Initiative for Chronic Obstructive Lung Disease, 2017.

Item 217**ANSWER: D**

This patient has essential hypertension and her goal blood pressure is < 140/90 mm Hg based on JNC 8 guidelines, or 130/80 mm Hg based on the more recent recommendations of the American College of Cardiology/American Heart Association Task Force on Clinical Practice Guidelines. Until recently, it was recommended that physicians should tolerate a rise of < 30% in serum creatinine after ACE inhibitor or angiotensin receptor blocker (ARB) initiation. Rises in serum creatinine of > 30% from baseline increase the risk of renal failure, adverse cardiac outcomes, and death. A recent study suggests that rises in serum creatinine of < 30% also put patients at risk for these outcomes, with a dose-response relationship between the magnitude of creatinine change and the risk of adverse outcomes.

This patient has more than a 30% rise in creatinine and has no other factors, such as diabetes mellitus, heart failure, or chronic kidney disease, that would indicate a need for ACE or ARB therapy for her hypertension. Discontinuing her ACE inhibitor and starting a medication from a different class is the most appropriate treatment at this time. Based on JNC 8 guidelines, additional options for blood pressure medications include thiazide diuretics and calcium channel blockers.

Ref: James PA, Oparil S, Carter BL, et al: 2014 evidence-based guideline for the management of high blood pressure in adults: Report from the panel members appointed to the Eighth Joint National Committee (JNC 8). *JAMA* 2014;311(5):507-520. 2) Schmidt M, Mansfield KE, Bhaskaran K, et al: Serum creatinine elevation after renin-angiotensin system blockade and long term cardiorenal risks: Cohort study. *BMJ* 2017;356:j791. 3) Whelton PK, Carey RM, Aronow WS, et al: 2017 ACC/AHA/AAPA/ABC/ACPM/AGS/APhA/ASH/ASPC/NMA/PCNA guideline for the prevention, detection, evaluation, and management of high blood pressure in adults. *J Am Coll Cardiol* 2018;71(19):e127-e248.

Item 218**ANSWER: C**

The recommended treatment for metatarsal stress fractures is no weight bearing for a few days, possibly using a posterior splint, transitioning to a walking boot or short leg cast, and then a rigid-soled shoe in 4–6 weeks. Callus formation on a radiograph and a lack of point tenderness signify adequate healing, and immobilization can be discontinued. Other recommended conservative therapy includes modified rest for 6–8 weeks with continuation of activities of daily living and limited walking. Normal activity can be resumed after 2–3 weeks with no pain. Additionally, the use of NSAIDs, ice, and stretching, as well as cross-training is recommended. Resuming regular activity after only 1 week of pain-free rest would not be recommended. Fractures of the fifth metatarsal should be carefully investigated to rule out a Jones fracture that may require orthopedic treatment. Treatment of the more common second and third metatarsal stress fractures is relatively straightforward.

Ref: Bica D, Sprouse RA, Armen J: Diagnosis and management of common foot fractures. *Am Fam Physician* 2016;93(3):183-191. 2) Brukner P, Clarsen B, Cook J, et al: *Brukner & Khan's Clinical Sports Medicine*, ed 5. McGraw Hill, 2017, pp 959-961.

Item 219**ANSWER: A**

A systematic evidence review released by the U.S. Preventive Services Task Force (USPSTF) noted that the most active people had median cardiovascular risk reductions of about 30%–35% when compared with the least active. Statins are beneficial for both primary and secondary prevention of cardiovascular disease, but the benefit is greater when the baseline risk is greater. Current guidelines would not support statin therapy for a patient with a 10-year risk of atherosclerotic cardiovascular disease (ASCVD) <5%. Fish oil supplements have not proven to be useful for primary prevention of ASCVD. Aspirin is recommended for the prevention of cardiovascular disease in adults 50–59 years of age with a >10% 10-year ASCVD risk who are not at increased risk of bleeding, are expected to live at least 10 years, and are willing to take low-dose daily aspirin for 10 years (USPSTF B recommendation). Niacin is no longer recommended for cardiovascular risk reduction due to a lack of evidence for benefit.

Ref: Shiroma EJ, Lee IM: Physical activity and cardiovascular health: Lessons learned from epidemiological studies across age, gender, and race/ethnicity. *Circulation* 2010;122(7):743-752. 2) *Final Recommendation Statement: Aspirin Use to Prevent Cardiovascular Disease and Colorectal Cancer: Preventive Medication*. US Preventive Services Task Force, 2017. 3) Last AR, Ference JD, Menzel ER: Hyperlipidemia: Drugs for cardiovascular risk reduction in adults. *Am Fam Physician* 2017;95(2):78-87.

Item 220**ANSWER: A**

Uterine fibroid tumors (leiomyomas) are the most common tumors of the female reproductive tract, with some evidence suggesting that the cumulative incidence in women age 25–45 years is approximately 30%. Symptoms related to fibroids can include menorrhagia, pelvic pain, obstructive symptoms, infertility, or pregnancy loss. However, many fibroids are asymptomatic and are discovered incidentally, with observation being the preferred management in this situation (SOR B). The risk of malignant leiomyosarcoma is exceedingly small (0.23% in one study) and there is a risk of side effects or complications from other treatment modalities.

For women who are symptomatic, the data is insufficient regarding the most appropriate therapy. Surgical options include myomectomy, hysterectomy, uterine artery embolization, and myolysis, but data to allow direct comparison is lacking. With the exception of trials of GnRH-agonist therapy as an adjunct to surgery, there is not enough randomized trial data to support the use of medical therapies such as oral contraceptives, NSAIDs, or progestins in the treatment of symptomatic fibroids.

Ref: Hartmann KF, Fonnesebeck C, Surawicz T, et al: Management of uterine fibroids. Agency for Healthcare Research and Quality, 2017. 2) De La Cruz MS, Buchanan EM: Uterine fibroids: Diagnosis and treatment. *Am Fam Physician* 2017;95(2):100-107.

Item 221**ANSWER: B**

Diarrhea that develops in patients with ileal Crohn's disease or following ileal resection is usually due to increased amounts of bile acid remaining in the stool. This affects colonic secretion and motility and various protein factors in the gut, resulting in the development of bile acid diarrhea (BAD). Although various tests can be performed to evaluate the stool, gut flora, and bowel function, a therapeutic trial with a bile acid sequestrant such as cholestyramine is most often used for both the diagnosis and treatment of BAD. Reducing fat intake may also be beneficial. Loperamide can lessen the diarrhea in some patients but should not be the primary treatment because chronic use can result in constipation. Fiber supplementation may help to produce a more formed stool and could be used as an adjunct treatment when appropriate.

Ref: Kasper DL, Fauci AS, Hauser SL, et al (eds): *Harrison's Principles of Internal Medicine*, ed 19. McGraw-Hill, 2015, pp 1934-1935. 2) Goldman L, Schafer AI (eds): *Goldman's Cecil Medicine*, ed 25. Elsevier Saunders, 2016, pp 928-929.

Item 222**ANSWER: C**

An SSRI or SNRI should be used first as monotherapy for posttraumatic stress disorder (PTSD), and should be optimized before an additional agent is added. Prazosin is an effective augmenting therapy for patients with PTSD and sleep disturbance (SOR B). Other α -blockers and β -blockers have been shown to be ineffective in the treatment of PTSD. Benzodiazepines such as lorazepam can treat symptoms of hyperarousal but have been associated with adverse effects and should be avoided in the treatment of PTSD (SOR B). Hypnotics such as zolpidem are generally reserved for short-term use. There is no evidence to support the use of atypical antipsychotics for PTSD and their use should be avoided (SOR C).

Ref: Warner CH, Warner CM, Appenzeller GN, Hoge CW: Identifying and managing posttraumatic stress disorder. *Am Fam Physician* 2013;88(12):827-834.

Item 223**ANSWER: D**

This patient has a typical presentation of impingement syndrome of the shoulder. Subacromial injection of a corticosteroid may provide pain relief for up to several weeks but does not alter long-term outcomes. According to some studies, these injections are associated with greater health care utilization. Injection of a corticosteroid has not been shown to provide superior pain relief compared to oral NSAIDs. Physical therapy is superior for long-term pain relief.

Ref: Foster ZJ, Voss TT, Hatch J, Frimodig A: Corticosteroid injections for common musculoskeletal conditions. *Am Fam Physician* 2015;92(8):694-699.

Item 224**ANSWER: B**

Statins such as atorvastatin, antiplatelet drugs such as aspirin, angiotensin inhibitors such as lisinopril, and β -blockers such as metoprolol have all been shown to increase survival after an acute coronary artery event. Calcium channel blockers such as amlodipine, fibrates such as gemfibrozil, and nitroglycerins such as isosorbide mononitrate have not been shown to increase survival. Spironolactone has been shown to increase survival in patients with heart failure and reduced ejection fractions but not in those with ischemic heart disease with preserved ejection fractions.

Ref: O'Gara PT, Kushner FG, Ascheim DD, et al: 2013 ACCF/AHA guideline for the management of ST-elevation myocardial infarction: A report of the American College of Cardiology Foundation/American Heart Association Task Force on Practice Guidelines. *Circulation* 2013;127(4):e362-e425.

Item 225**ANSWER: C**

As many as 20% of newborns will be affected by neonatal acne, usually in the form of pustules confined to the cheeks, chin, eyelids, and forehead. This is typically mild, self-limited, and best managed by reassuring the parents. Acne can also appear in infants, typically males 6–12 months of age, and is also usually self-limited and not associated with underlying endocrine pathology in the absence of any other findings suggesting hormonal abnormalities such as clitoromegaly, breast or testicular development, pubic hair growth, hirsutism, or a growth abnormality consistent with increased muscle development. Acne appearing during mid-childhood is rare and, if present, warrants referral for extensive laboratory testing to identify an underlying endocrine abnormality. Preadolescents and adolescents are very likely to develop acne as a result of normal ovarian/testicular development. In the absence of other findings to suggest an endocrine problem, developing an effective treatment regimen is most appropriate for these individuals.

Ref: Eichenfield LF, Krakowski AC, Piggott C, et al: Evidence-based recommendations for the diagnosis and treatment of pediatric acne. *Pediatrics* 2013;131(Suppl 3):S163-S186.

Item 226**ANSWER: B**

Using a procalcitonin-guided therapy algorithm reduces antibiotic use by 3.47 days without increasing either morbidity or mortality in adults with acute respiratory infections. If the procalcitonin level is <0.10 mg/dL, a bacterial infection is highly unlikely and it is strongly recommended that antibiotics not be prescribed. If the procalcitonin level is 0.10–0.24 mg/dL a bacterial infection is still unlikely and it is recommended that antibiotics not be used. If the level is 0.25–0.50 mg/dL a bacterial infection is likely and antibiotics are recommended. It is strongly recommended that antibiotics be given if the level is >0.50 mg/dL, because a bacterial infection is very likely.

Ref: Morris C, Paul K, Safranek S: Procalcitonin-guided antibiotic therapy for acute respiratory infections. *Am Fam Physician* 2016;94(1):53-58.

Item 227**ANSWER: A**

This case and image are consistent with *Ascaris lumbricoides* infestation. *A. lumbricoides* is a large roundworm that typically infects the ileum. Symptoms are variable but large infections can lead to intestinal obstruction. Pinworms are much smaller and typically present with anal pruritus. Tapeworms can be large, but are flat and segmental in appearance, and are typically found in the stool as segments called proglottids. Hookworms are also round, but are typically 6–12 mm in length. They are a significant cause of anemia in children globally. *Giardia lamblia* is a microscopic protozoan parasite that is not visible on gross examination.

Ref: Kucik CJ, Martin GL, Sortor BV: Common intestinal parasites. *Am Fam Physician* 2004;69(5):1161-1168. 2) Weatherhead JE, Hotez PJ: Worm infections in children. *Pediatr Rev* 2015;36(8):341-352.

Item 228**ANSWER: C**

Screening for colorectal cancer (CRC) is recommended for average-risk individuals beginning at age 50 (SOR A). Individuals at higher risk include those with a personal history of adenomatous polyps, CRC, inflammatory bowel disease, genetic cancer syndromes, or a family history of either adenomatous polyps or CRC. Patients with a first degree relative with CRC or adenomatous polyps discovered before age 60, or two or more first degree relatives at any age with CRC or advanced adenoma, should undergo colonoscopy screening starting at age 40 or 10 years before the youngest age a family member was diagnosed, whichever comes first. The maximum surveillance interval for these patients is 5 years (SOR C). Patients with a single first degree relative diagnosed at age 60 or older, and patients with two affected second degree relatives, should undergo screening starting at age 40 by any recommended method, and at the same intervals for average-risk individuals (SOR C). Patients with small, distal hyperplastic polyps are considered to have a normal colonoscopy (SOR C). There is no need for referral to a gastroenterologist or interval fecal immunochemical testing (FIT) following an adequate colonoscopy.

Ref: Short MW, Layton MC, Teer BN, Domagalski JE: Colorectal cancer screening and surveillance. *Am Fam Physician* 2015;91(2):93-100. 2) Rex DK, Boland CR, Dominitz JA, et al: Colorectal cancer screening: Recommendations for physicians and patients from the US Multi-Society Task Force on Colorectal Cancer. *Am J Gastroenterol* 2017;112(7):1016-1030.

Item 229**ANSWER: D**

Penile enlargement in an 8-year-old male is a sign of precocious puberty. Isolated sparse pubic and axillary hair growth and axillary odor is referred to as premature adrenarche, and represents high levels of dehydroepiandrosterone rather than activation of the hypothalamic-pituitary-gonadal axis that leads to puberty. The isolated findings of premature adrenarche are generally considered benign. An 8-year-old with breast buds and a 10-year-old with menarche are within the normal range of expected pubertal development. Penile enlargement typically represents full activation of the hypothalamic-pituitary-gonadal axis and warrants endocrinologic evaluation in boys younger than 9 years of age.

Ref: Kaplowitz P, Bloch C: Evaluation and referral of children with signs of early puberty. *Pediatrics* 2016;137(1). 2) Klein DA, Emerick JE, Sylvester JE, Vogt KS: Disorders of puberty: An approach to diagnosis and management. *Am Fam Physician* 2017;96(9):590-599.

Item 230**ANSWER: B**

Leukocytosis is a relatively common finding with many possible etiologies. For most cases without a clear cause, a repeat CBC with differential and a peripheral smear review are indicated to confirm leukocytosis, determine subtypes, and look for concerning abnormalities on the smear. Given this patient's fatigue, a hematologic referral may be indicated if leukocytosis is confirmed on repeat testing. Similar recommendations would apply to flow cytometry testing. Blood cultures are not necessary in cases of leukocytosis without evidence of infection. Obesity can cause leukocytosis, but because of the patient's fatigue it would not be appropriate at this time to attribute the leukocytosis to obesity alone.

Ref: Herishanu Y, Rogowski O, Polliack A, Marilus R: Leukocytosis in obese individuals: Possible link in patients with unexplained persistent neutrophilia. *Eur J Haematol* 2006;76(6):516-520. 2) Riley LK, Rupert J: Evaluation of patients with leukocytosis. *Am Fam Physician* 2015;92(11):1004-1011.

Item 231

ANSWER: E

When administered at appropriate doses, opiates do not reduce or compromise respiratory status and do not hasten dying. Opiates help to reduce the sense of air hunger in patients with dyspnea. The use of opiates for palliative therapy in advanced pulmonary disease is supported by clinical guidelines from the American Thoracic Society.

Ref: Albert RH: End-of-life care: Managing common symptoms. *Am Fam Physician* 2017;95(6):356-361.

Item 232

ANSWER: D

This patient's back pain is most consistent with an inflammatory cause rather than a mechanical cause. Morning stiffness and improvement with physical activity are key features of inflammatory back pain. Ankylosing spondylitis (AS), one subset of the broader diagnostic category of axial spondyloarthritis, is the likely diagnosis in this patient. Delays in diagnosis are common due to the widespread presence of mechanical low back pain. The identification of patients with inflammatory back pain is important, because early intervention with disease-modifying agents can preserve long-term joint function. HLA-B27 is found in 74%–89% of patients with AS and it can be diagnostic in a patient with typical inflammatory back pain symptoms.

Inflammatory markers such as the erythrocyte sedimentation rate and C-reactive protein are often elevated in patients with AS but are not specific to this diagnosis. Rheumatoid arthritis is not a likely cause of back pain in this patient without any other joint findings. Antinuclear antibody testing can assist in the diagnosis of systemic lupus erythematosus, which can cause an inflammatory arthritis, but it is similarly nonspecific and lupus typically has other findings in addition to back pain.

Ref: Taurog JD, Chhabra A, Colbert RA: Ankylosing spondylitis and axial spondyloarthritis. *N Engl J Med* 2016;374(26):2563-2574. 2) Strand V, Singh JA: Evaluation and management of the patient with suspected inflammatory spine disease. *Mayo Clin Proc* 2017;92(4):555-564.

Item 233

ANSWER: A

The 2015 American Geriatrics Society Beers Criteria for potentially inappropriate medication use in older adults ≥ 65 years of age states that donepezil use should be avoided in patients with syncope, due to an increased risk of bradycardia (Moderate Evidence Level; Strong Strength of Recommendation). Donepezil is a cholinesterase inhibitor. Due to their cholinergic effect, these medications have a vagotonic effect on the sinoatrial and atrioventricular nodes. This can cause bradycardia or heart block in patients with or without underlying cardiac conduction abnormalities. Syncope has been reported with these medications.

Memantine is an N-methyl-D-aspartate receptor antagonist and is not associated with bradycardia. Escitalopram, lisinopril, and zolpidem are also not associated with bradycardia.

Ref: Aricept (donepezil hydrochloride) label. US Food and Drug Administration, 2012. 2) American Geriatrics Society 2015 Beers Criteria Update Expert Panel: American Geriatrics Society 2015 updated Beers Criteria for potentially inappropriate medication use in older adults. *J Am Geriatr Soc* 2015;63(11):2227-2246.

Item 234

ANSWER: D

In a pediatric patient, blood pressure should be evaluated using comparisons based on age, sex, and height. Although this adolescent's blood pressure is prehypertensive for an adult according to JNC 8 guidelines, it is stage 1 hypertension (between 95% and 99%) for her age, sex, and height. All pediatric patients with confirmed hypertension should have further evaluation to check for renal dysfunction as well as other cardiac risk factors. Additionally, renal ultrasonography is recommended to evaluate for renal disease and echocardiography to evaluate for end-organ damage that would affect treatment goals. Additional studies, such as plasma renin and catecholamine levels or renovascular imaging, may be indicated in children with abnormalities on initial evaluation that suggest secondary causes of hypertension.

Pharmacologic therapy is usually recommended for pediatric patients with symptomatic hypertension, secondary hypertension, target organ damage, diabetes mellitus, or persistent hypertension in spite of nonpharmacologic treatment. A low-sodium diet may be helpful for decreasing blood pressure, and given this patient's obesity, intensive counseling about lifestyle changes is appropriate.

Ref: Flynn JT, Kaelber DC, Baker-Smith CM, et al: Clinical practice guideline for screening and management of high blood pressure in children and adolescents. *Pediatrics* 2017;140(3):e20171904.

Item 235

ANSWER: A

Patients treated with valproic acid (VPA) have a higher incidence of hyperammonemia. Although the incidence of VPA-induced hyperammonemia varies, it should be considered in patients taking VPA who present with altered mental status or encephalopathy. In addition to discontinuing VPA, the encephalopathy should be managed with ammonia-lowering drugs such as lactulose. Ammonia levels can also be elevated in patients taking VPA who do not have encephalopathy, and close monitoring of these patients for the development of encephalopathy is recommended. Gilbert syndrome causes an asymptomatic elevation of bilirubin in the absence of underlying hepatic disease. Occult gastrointestinal bleeding should be suspected in patients with an elevated BUN level in the absence of underlying renal disease or volume depletion. Patients with portal vein thrombosis present with abdominal pain and other symptoms of an underlying predisposing disease such as cirrhosis (SOR C).

Ref: Kasper DL, Fauci AS, Hauser SL, et al (eds): *Harrison's Principles of Internal Medicine*, ed 19. McGraw-Hill, 2015, pp 2026, 2028, 2056.

Item 236**ANSWER: A**

Current guidelines recommend that patients with an ST-elevation myocardial infarction (STEMI) who also have atrial fibrillation take dual antiplatelet therapy such as aspirin plus clopidogrel and a vitamin K antagonist, with a goal INR of 2.0–3.0. If a patient was already taking a direct-acting oral anticoagulant (DOAC) instead of warfarin for atrial fibrillation, the patient should continue with the DOAC in addition to dual antiplatelet therapy. The duration of triple therapy should be as short as possible, and aspirin can often be discontinued after 1–3 months. However, this patient's STEMI occurred less than 2 weeks ago and he should continue triple therapy.

Ref: Anderson JL, Morrow DA: Acute myocardial infarction. *N Engl J Med* 2017;376(21):2053-2064.

Item 237**ANSWER: E**

Somatic symptom disorder (formerly called somatization disorder) usually begins in the teens or twenties and is characterized by multiple unexplained physical symptoms, insistence on surgical procedures, and an imprecise or inaccurate medical history. These patients also commonly abuse alcohol, narcotics, or other drugs.

Patients with illness anxiety disorder are overly concerned with bodily functions, and can often provide accurate, extensive, and detailed medical histories. Malingering is an intentional pretense of illness to obtain personal gain. Patients with panic disorder have episodes of intense, short-lived attacks of cardiovascular, neurologic, or gastrointestinal symptoms. Generalized anxiety disorder is characterized by unrealistic worry about life circumstances accompanied by symptoms of motor tension, autonomic hyperactivity, or vigilance and scanning.

Ref: Kurlansik SL, Maffei MS: Somatic symptom disorder. *Am Fam Physician* 2016;93(1):49-54.

Item 238**ANSWER: C**

The Lachman test is the most accurate test for an anterior cruciate ligament (ACL) tear (SOR A). Accurate testing can lead to appropriate referral and treatment for ACL tears, and early detection can lead to better outcomes. The Lachman test has higher validity based on a sensitivity of 68% for partial ruptures and 96% for complete ruptures. The other two commonly used tests are the anterior drawer test, which has a sensitivity of 38% and a specificity of 81%, and the pivot shift test, which is more technically difficult than the other two tests and has a sensitivity ranging from 24% to 85%. The pivot shift test is effective if done correctly but should not be used alone to diagnose an ACL tear (SOR A).

The lever sign test is a newer test that holds promise for detecting ACL tears and is easily performed in the office. However, sensitivity and specificity reports vary (SOR B). The McMurray test is used to detect meniscal tears.

Ref: Grover M: Evaluating acutely injured patients for internal derangement of the knee. *Am Fam Physician* 2012;85(3):247-252. 2) Koster Ch, Harmsen AM, Lichtenberg MC, Bloemers FW: ACL injury: How do the physical examination tests compare? *J Fam Pract* 2018;67(3):130-134.

Item 239

ANSWER: E

Testosterone replacement has significant risks and contraindications. Absolute contraindications include breast cancer, prostate cancer, a prostate-specific antigen (PSA) level >4 ng/dL, an abnormal rectal examination with nodules, and polycythemia with a hematocrit >54%. Relative contraindications include a baseline hematocrit >50%, a desire for fertility, uncontrolled heart failure, untreated sleep apnea, and severe lower tract symptoms. This patient has polycythemia with a hematocrit >54% and should not be started on testosterone. Testosterone stimulates erythropoiesis and increases the risk of thrombosis. Although there may be an association between testosterone deficiency and coronary artery disease, a history of coronary artery disease is not a contraindication to testosterone replacement. Patients with chronic renal disease who are on chronic opioid therapy are at higher risk of developing secondary testosterone deficiency. Testosterone replacement may increase PSA levels and should not be used in patients with known or suspected prostate cancer.

Ref: Petering RC, Brooks NA: Testosterone therapy: Review of clinical applications. *Am Fam Physician* 2017;96(7):441-449.

Item 240

ANSWER: C

De Quervain's tenosynovitis usually occurs with repeated use of the thumb and is characterized by pain in the radial wrist. The course is typically self-limited but can last for up to a year, so waiting would not be a good option for this patient who wants to continue her usual activities as soon as possible. Conservative therapy with immobilization and NSAIDs is recommended if there are no contraindications to NSAIDs. A corticosteroid injection is helpful but is typically reserved for severe cases or if conservative therapy fails. Surgery may be beneficial but is generally not recommended unless the course is severe, given the natural history of resolution.

Ref: Tallia AF, Cardone DA: Diagnostic and therapeutic injection of the wrist and hand region. *Am Fam Physician* 2003;67(4):745-750. 2) Huisstede BM, Coert JH, Fridén J, Hoogvliet P; European HANDGUIDE Group: Consensus on a multidisciplinary treatment guideline for de Quervain disease: Results from the European HANDGUIDE study. *Phys Ther* 2014;94(8):1095-1110.